A

TREATISE

ON

DISLOCATIONS AND FRACTURES

OF THE JOINTS.

BY

SIR ASTLEY COOPER, BART. F.R.S.

SERJEANT-SURGEON TO THE KING, ETC.

A NEW EDITION, MUCH ENLARGED.

EDITED BY

BRANSBY B. COOPER, F.R.S.

SURGEON TO GUY'S HOSPITAL.

LONDON:

JOHN CHURCHILL, PRINCES STREET, SOHO.

M.DCCC.XLII.

TO THE

STUDENTS OF ST. THOMAS'S AND GUY'S HOSPITALS.

My dear young Friends,

This Work has been composed for your use; and if you derive advantage from it, my principal object will be attained. I cannot, however, omit the opportunity of expressing my gratitude for the affectionate and respectful manner in which you have always received me as your instructor. Your parents and relatives, many of whom were my pupils, are also entitled to my most grateful acknowledgments, — they fostered me in early life, — and by their friendship and recommendation have largely contributed to procure me a degree of success which, I fear, is beyond my merits, and a course of uninterrupted happiness which few have been permitted to enjoy.

Believe me, always,

Your affectionate Friend,

Astley Cooper.

PREFACE

TO THE FIFTH EDITION.

It is incumbent on me to observe, that, although I believe the matter of this Work to be correct, and regard it as the result of a considerable share of experience, yet I am aware that the reader may detect a too familiar mode of expression, and may censure me for want of attention to its style. The familiarity of the diction arises from my desire to be perspicuous. I prefer plain and simple language to an elaborate and ostentatious phraseology, just as I would a good plain suit to the finest embroidered dress; and am ready to own that my thoughts are more steadfastly directed to the matter which I give, than to the manner in which it is conveyed.

I am much indebted to my friends for their communications; the life of man is too short to allow him, even with the greatest industry and zeal, and with the most advantageous opportunities, to witness all the varieties of accident or disease; and I should feel that I was not properly discharging my duty, if I omitted to avail myself of all the evidence which might be adduced by those on whose respectable testimony I could depend.

While, then, I sincerely thank my friends for their kindness, I wish to state to them and to others, that they will always oblige me, by giving me any information which it is in their power to convey upon this or any other subject in surgery.

In looking over the following pages on dislocations, I feel that my professional brethren will be disposed to think that I have limited to too short a period the attempts at reduction. It has been stated, that dislocations have been reduced at four, and even six months after the injury; and this assertion I am not disposed to deny; indeed, I have myself had an opportunity of witnessing examples of the fact: but, excepting in very emaciated, relaxed, and aged persons, I have observed that the injury done in the extension, has been greater than the advantage received from the reduction; and, therefore, in the case of a very strong muscular person, I am not disposed, after three months, to recommend the attempt; finding that the use of the limb is not, when reduced, greater than that which it would have acquired in its dislocated state. Let this be fairly represented to the patient; and then, at his request only, the reduction should be attempted: but, "with all appliances and means to boot," the extension must be very gradually made, and without violence, to avoid injury to the muscles and nerves.*

* The remainder of the original Preface consisted chiefly of additional observations on fracture of the neck of the femur, which are in this edition incorporated with the body of the Work, and, therefore, need not be reprinted here.—*Ed.*

EDITOR'S PREFACE.

THE rapid and increasing demand for this Work, having required that it should be again committed to the press, some prefatory observations may be expected from me, in fulfilling the very grateful task of Editor, which was assigned to me some time prior to the lamented decease of Sir Astley Cooper.

In the performance of this duty, it is generally considered proper and becoming to say something in reference to the peculiar merits of the Treatise and its Author. I am convinced, however, that no higher encomium can be conferred on Sir Astley Cooper's memory, than the general and substantial approbation which calls forth this extended record of his long experience, and of his discriminating vigilance of observation; and I cannot but rejoice in thus feeling myself relieved from the embarrassment to which I should otherwise have been exposed, in attempting to express, in fit and unexceptionable language, the extent of praise which this Work so richly deserves.

I may, however, be allowed to express the gratification I have experienced from the sentiments expressed in the mass of correspondence, as well as from the additional Cases which have been contributed from various sources

since the last edition; as they all tend to form so many various, yet concurrent testimonies to the soundness of the principles which it is the object of this Treatise to inculcate.

From these papers, as well as from my own practice, several additional Cases have been selected for the present edition; and much new matter has been added, which was derived from Sir Astley Cooper himself.

In order to admit of these additions, and at the same time to preserve the matter within the limits of the present volume, it has been thought necessary in some few instances to condense the original. It is, however, proper to mention, that the additional Cases which were detailed in the preface to the last edition, are now introduced into the body of the Work, under the appropriate heads to which they refer.

As Surgery, in common with all other sciences, is progressive, so must it follow, that increase of experience must tend daily either to the confirmation or the condemnation of the principles laid down by Sir Astley Cooper, in the treatment of fractures and dislocations of joints; and it may be here remarked, in proof of the general diffusion of the doctrines of this Work, and their utility, how rarely, even in remote districts, are now to be noticed dislocations remaining unreduced through ignorance of the nature of the injury, or of the means to be employed for their reduction.

Trusting that the additional matter embodied in the present edition, may contribute to the utility of this Work, it is again committed to the candid judgment of the Profession; not with the hesitation that would

attend an untried theory, — not with the affected boldness which too often conceals a conscious temerity of speculation,—but with that reasonable confidence which is warranted by experience.

My time having been so much occupied in writing the life of the late Sir Astley Cooper, and in my professional avocations, I have availed myself of the assistance of Mr. Druitt, in arranging the new matter, and in generally preparing this edition for the press.

My thanks, at the same time, are due to Mr. Churchill, for the care and attention he has devoted as well to the general arrangement of the publication, as to the minute details of its typographical execution; but more especially for his selection of an artist so fully competent to the task as Mr. Bagg. The reader will find the delineations copied from the quarto edition to be even more graphic and perspicuous than the originals; while the illustrations now for the first time introduced into the work are equally correct, clear, and expressive. The advantages of such engravings being placed in immediate connexion with the portion of text which they are intended to elucidate, will not pass unnoticed by those who have felt the inconvenience of having to search at the end of the volume for each plate to which reference occurs in the text.

BRANSBY B. COOPER.

2, New Street, Jan. 3rd, 1842.

CONTENTS.

CHAPTER I.

PAGE

On Dislocations in General 1

CHAPTER II.

On Dislocations of the Hip-joint 34

Sect. 1. Anatomy of the joint . . . . . *ib.*

2. Dislocation on the dorsum ilii 36

3. Dislocation into the foramen ovale 60

4. Dislocation into the ischiatic notch . . . 71

5. Dislocation on the pubes 84

6. Anomalous dislocations of the hip-joint . . . 100

CHAPTER III.

On Fractures of the Pelvis 111

CHAPTER IV.

On Fractures of the upper part of the Thigh-bone . . . 127

Sect. 1. Introductory . . . . . . *ib.*

2. Fracture of the neck of the thigh-bone within the capsular ligament 128

3. Fractures of the cervix femoris external to the capsular ligament and into the cancelli of the trochanter major . 165

4. Fracture of the femur through the trochanter major . 175

5. Fracture of the epiphysis of the trochanter major . . 185

6. Fractures below the trochanter major . . . 190

CHAPTER V.

On Dislocations of the Knee 193

Sect. 1. Anatomy of the joint . . . . . *ib.*

2. Dislocations of the patella 195

3. Dislocations of the tibia at the knee-joint . . . 204

PAGE

SECT. 4. Partial dislocation of the thigh-bone from the semilunar cartilages 212
5. Compound dislocation of the knee-joint . . . 216
6. Dislocations of the head of the fibula . . . 221

CHAPTER VI.

On Fractures of the Knee 224
SECT. 1. Fractures of the patella . . . . . ib.
2. Oblique fractures of the condyles of the femur into the knee-joint 240
3. Oblique fracture of the femur just above its condyles . 244
4. Fracture of the head of the tibia 249

CHAPTER VII.

On Dislocations and Fractures of the Ankle-joint . . . 251
SECT. 1. Anatomy of the joint . . . . ib.
2. Simple dislocation of the tibia inwards . . . 252
3. Simple dislocation of the tibia forwards . . 255
4. Simple dislocation of the tibia outwards . . 260
5. Compound dislocation of the ankle-joint . . 262
6. Fracture of the fibula near the ankle-joint . . 317
7. Fractures of the tibia at the ankle-joint . . 318

CHAPTER VIII.

On Dislocations of the Foot 322

CHAPTER IX.

On Dislocations of the Jaw 341
SECT. 1. Anatomy of the joint . . . . ib.
2. Dislocations of the jaw 342

CHAPTER X.

On Dislocations of the Clavicle 349
SECT. 1. Anatomy of the articulation of the clavicle with the sternum ib.
2. Dislocations of the sternal extremity of the clavicle . 350
3. Anatomy of the articulation of the clavicle with the scapula 355
4. Dislocations of the scapular extremity of the clavicle . 356

CHAPTER XI.

	PAGE
On Dislocations of the Shoulder-joint	360
SECT. 1. Anatomy of the shoulder-joint	*ib.*
2. Dislocation into the axilla	363
3. Dislocation forwards under the clavicle	383
4. Dislocation of the os humeri on the dorsum scapula	391
5. Partial dislocation of the os humeri	400
6. Compound dislocation of the os humeri	409

CHAPTER XII.

On Fractures near the Shoulder-joint liable to be mistaken for Dislocations	411
SECT. 1. Fracture of the acromion	*ib.*
2. Fracture of the neck of the scapula	413
3. Fractures of the head and neck of the os humeri	417

CHAPTER XIII.

On Dislocations of the Elbow-joint	437
SECT. 1. Anatomy of the joint	*ib.*
2. Dislocation of both bones backwards	440
3. Lateral dislocation of the elbow	448
4. Dislocation of the ulna backwards	449
5. Dislocation of the radius forwards	452
6. Dislocation of the radius backwards	459

CHAPTER XIV.

On Fractures of the Elbow-joint	463
SECT. 1. Fractures of the os humeri above the condyles	*ib.*
2. Fractures of the internal condyle of the os humeri	466
3. Fracture of the external condyle of the os humeri	467
4. Fracture of the coronoid process of the ulna	468
5. Fracture of the olecranon	470
6. Fracture of the neck of the radius	476
7. Compound fractures of the elbow-joint	477

CHAPTER XV.

On Dislocations and Fractures of the Wrist-joint	482
SECT. 1. Anatomy of the joint	*ib.*
2. Dislocation of the radius and ulna	483
3. Dislocation of the radius at the wrist	489
4. Dislocation of the ulna	490
5. Fractures of the lower end of the radius	492

CHAPTER XVI.

PAGE
On Dislocations and Fractures of the Carpal and Metacarpal Bones, and of the Fingers and Toes . . . 501
Sect. 1. Dislocations of the carpus . . . . . *ib.*
2. Dislocations and fractures of the metacarpal bones . 505
3. Dislocations and fractures of the fingers and toes . . 509
4. Dislocations of the thumb . . . 512

CHAPTER XVII.

On Dislocations of the Ribs 520

CHAPTER XVIII.

On Injuries of the Spine 523
Sect. 1. Anatomy of the spine . . . . *ib.*
2. Concussion of the spinal marrow . . . 526
3. Extravasation into the sheath of the spinal cord . . 530
4. Fractures of the spine . . . 532
5. Suppuration and ulceration of the spinal cord . . 561

APPENDIX.

No. 1. Additional observations on fracture of the neck of the femur . 563
No. 2. On non-union of fractured bones . . . 568

ANALYTICAL TABLE OF CASES.

CASE		PAGE
1.	Spontaneous dislocation of both patellæ from relaxation .	8
2.	Spontaneous dislocation of the hip-joint from relaxation. Mr. Brindley, of Winkhill	*ib.*
3.	Spontaneous dislocation of the shoulder after a fever . .	9
4.	Spontaneous dislocation of the left patella following chronic inflammation of the knee	*ib.*
5.	Dislocation of the shoulder caused by palsy and wasting of the muscles after long extension . . .	10
6.	Case of the same, after dentition . . .	11
7.	Dislocation of the little finger from spasm, during an attack of hemiplegia	*ib.*
8.	Dislocation of the little finger caused by an electric shock. Mr. Druitt	*ib.*
9.	Excision of the head of the femur. Mr. White . .	12
10.	Dislocation of the hip-joint, complicated with fracture of the acetabulum and rupture of the intestines . . .	*ib.*
11.	Compound fracture of the leg, and dislocation of the shoulder; the latter overlooked till too late for reduction . . .	13
12.	Dislocation of the fifth cervical vertebra from the sixth. Mr. B. Cooper	*ib.*
13.	Case of the same	14
14.	Sprain of the shoulder, falsely said to be a dislocation . .	17
15.	Fracture of the cervix femoris, falsely said to be a dislocation. Mr. John Rowe	18
16.	Spasm of the muscles of the hip-joint producing some of the symptoms of dislocation. M. Kluyskiens . .	20
17.	Dislocation of the shoulder of two years' standing, said to be cured by division of muscles. M. Dieffenbach . . .	29
18.	Dislocation of the hip-joint on the dorsum ilii, not reduced; appearances nine years afterwards . . .	41
19.	Same dislocation, reduced; advantage of constitutional measures	42
20.	Same dislocation, reduced. Mr. Nott, of Collumpton .	43
21.	Same dislocation neglected for five weeks; unsuccessful attempt at reduction by mechanical means only . . .	44

CASE PAGE

22. Dislocation of the hip-joint on the dorsum ilii, reduced after five weeks, by the pulleys and constitutional means combined. Mr. Norwood, of Hertford 45
23. Same dislocation, reduced after six weeks. Mr. Thomas, of St. Luke's Hospital 46
24. Same dislocation, reduced after seven weeks. Mr. Mayo, of Winchester . . . . . . *ib.*
25. Same dislocation, reduced with great difficulty, after a month, by manual extension . . . . . *ib.*
26. Same dislocation; disadvantages of manual extension . 47
27. Same dislocation in a child seven years old, reduced. Mr. Daniel *ib.*
28. Same dislocation, reduced; extension made from the ankle. Mr. Oldknow, of Nottingham 48
29. Same dislocation, complicated with fracture of the dislocated bone, in a youth of eighteen; fracture allowed to unite, and in five weeks the dislocation reduced. Mr. Badley . . 49
30. Same dislocation; both limbs exactly of the same length, because the sound limb had been previously shortened by fracture. Mr. Badley . . . . . . *ib.*
31. Same dislocation, with fracture; not reduced . . 50
32. Same dislocation; caused by a heavy weight falling on the back. Mr. Maurice, of Marlborough 51
33. Same dislocation in military practice; reduced without pulleys. Mr. Elliot . . . . . . *ib.*
34. Case of the same. Mr. Elliot 52
35. Same dislocation, reduced; tobacco used to cause relaxation. Mr. B. Cooper . . . . . *ib.*
36. Same dislocation in a female; recurring spontaneously in the night after reduction. Mr. Liston 54
37. Same dislocation in a scrofulous boy of fourteen; the cervix femoris broken in attempting to reduce it; cure with very little deformity. Mr. Gwynne 55
38. Same dislocation; unsuccessful experiment of extension with a weight of 112 lbs. Mr. B. Cooper . . . 56
39. Same dislocation, with fracture of the acetabulum. Mr. Key 57
40. Dissection of a recent dislocation on the dorsum ilii. Mr. Todd, of Dublin 59
41. Dislocation into the foramen ovale, unreduced; appearance of the patient after ten months 63
42. Same dislocation, reduced. Mr. Daniel . . . 65
43. Same dislocation; the head of the bone thrown, in the attempt at reduction, into the ischiatic notch, from which it could not be removed 66
44. Same dislocation, reduced; the limb carried behind the sound one during the extension. Mr. Key . . . *ib.*
45. Same dislocation, reduced. Mr. B. Cooper . . 68

CASE PAGE

46. Dislocation of the hip-joint into the foramen ovale, the dislocated limb congenitally shorter than the other 69
47. Same dislocation; diagnosis rendered difficult by fracture of the opposite thigh. Dr. Bellingham 70
48. Dislocation into the ischiatic notch; reduced by extension in a direct line with the body 74
49. Same dislocation, reduced. Mr. Rogers, of Manningtree . 75
50. Same dislocation, reduced at the fifth attempt. Mr. James Chapman 77
51. Same dislocation, reduced. Mr. Mayo, of Winchester . 78
52. Same dislocation, reduced. Mr. Worts . . . 79
53. Same dislocation, reduced; diagnosis rendered difficult by a fracture of the opposite thigh. Mr. Roberts, of Dudley . . 80
54. Dislocation of the left femur into the sciatic notch, and of the right into the dorsum ilii; the left reduced; the right not reduced, because of a fracture of the acetabulum. Mr. Growse, of Bilderton 81
55. Dislocation into the ischiatic notch, with fracture of the opposite thigh. Mr. Travers 83
56. Dislocation on the pubes, reduced. Dr. Gaitskill . . 88
57. Same dislocation, reduced. Mr. Tyrrell . . . 89
58. Same dislocation, reduced; head of the bone thrown on the femoral artery, so as to stop its pulsations. Mr. Morgan *ib.*
59. Same dislocation; failure of extension in the direct line of the body; success of Sir A. Cooper's plan. Mr. Holland, of Manchester 90
60. Same dislocation, reduced. Mr. Callaway . . . 91
61. Same dislocation in a boy of seventeen; head of the bone thrown on the inner side of the artery; a wound in the groin; abscesses; and death on the eighteenth day. Mr. B. Cooper 92
62. Case of unreduced dislocation on the pubes; appearances at six months 95
63. Compound dislocation of the femur on the pubes; reduced by the hands; fatal in three weeks, from excessive suppuration. Dr. Walker, of Charlestown 96
64. Dislocation on the dorsum ilii, said to be reduced after five years, through the patient's falling out of his berth on board ship. Mr. Cornish, of Falmouth 98
65. Dislocation of the hip-joint directly upwards; head of the bone resting between the anterior spinous processes of the ilium; reduced. Dr. Cummins 101
66. Same dislocation, reduced. Mr. Morgan . . . 103
67. Same dislocation, unreduced; a new socket formed beneath the anterior superior spine of the ilium. Mr. Oldknow . . 105
68. Same dislocation, unreduced; a new socket formed between the anterior inferior spine of the ilium and the acetabulum; ligamentum teres entire. Mr. Earle 106

CASE PAGE

69. Dislocation of the hip directly downwards, on the tuber ischii. Mr. Keate 107
70. Dislocation downwards on the tuber ischii . . . 109
71. Fracture of the os innominatum; posterior part of the acetabulum broken off, and head of the femur dislocated upwards; symphysis pubis torn asunder; fatal 113
72. Fracture of the pelvis through the acetabulum, with some of the appearances of dislocation backwards; fatal in four days; head of the bone found driven into the cavity of the pelvis . . 114
73. Right os innominatum torn from the sacrum, and rami of ischium and pubes fractured; fatal. Mr. Sandford . . *ib.*
74. Fracture of the ramus of the ischium, with laceration of the urethra, and extravasation of urine 117
75. Fracture of the right os innominatum . . . 119
76. Fracture of the pubes. Mr. B. Cooper . . . 120
77. Fracture of the spinous process and crista ilii. Mr. B. Cooper *ib.*
78. Comminuted fracture of the pelvis, and laceration of the bladder. Mr. B. Cooper 121
79. Separation of the symphysis pubis. Mr. B. Cooper . . 122
80. Fracture through the acetabulum from a fall on the hip; recovery in six weeks. Sir C. Bell 123
81. Fracture of the left acetabulum, and of the trochanter. Mr. Vincent *ib.*
82. Fracture of the descending ramus of the pubes, which penetrated the bladder and rectum. Mr. Key . . . 125
83. Fracture of the pubes . . . . . *ib.*
84. Fracture of the acetabulum, with some of the symptoms of fracture of the neck of the thigh-bone. Mr. Earle . . *ib.*
85. Fracture of the tibia; six inches of bone removed; non-union. Mr. Benjamin Bell 141
85* Fracture of the neck of the thigh-bone within the capsular ligament; non-union. Mr. Robertson 156
86. Fracture of the cervix femoris within the capsule; the reflected ligament not torn through; no shortening, nor crepitus, nor eversion, and union by bone. Mr. Swan 157
87. Same fracture; inversion of the limb. Mr. Swan . . 158
88. Same fracture; appearances on dissection . . . 159
89. Same fracture; no shortening; united by bone in three months. Mr. Stanley . . . . . . *ib.*
90. Fracture of the cervix femoris; external to the capsule; the cervix driven into the cancelli of the trochanter major. Mr. Powell . 167
91. Same fracture; fatal in four days. Mr. Wray . . 169
92. Same fracture. Mr. Travers . . . . *ib.*
93. Same fracture; fatal in a fortnight. Mr. Key . . 171
94. Diagonal fracture through the base of the cervix femoris; with inversion of the limb. Mr. Guthrie . . . 172
95. Fracture through the trochanter major . . . 176
96. Same fracture; great difficulty of diagnosis. Mr. Harris, of Reading *ib.*

CASE PAGE

97. Fracture through the trochanter major, in a young lady. Mr. Godwin, of Midhurst 182
98. Same fracture, which united with the limb, shortened about an inch, and slightly everted, but very useful. Mr. Constable . *ib.*
99. Same fracture, with separation of the trochanter major, and with some resemblance to dislocation. Mr. Stanley . . 184
100. Fracture of the epiphysis of the trochanter major. Death nine days after the accident from fever and suppuration. Mr. Key . 186
101. Same fracture. The diagnosis very difficult from the smallness of the detached portion, the slight degree of deformity, and the mobility of the limb in all its natural directions, and in no other. Mr. B. Cooper 187
102. Same fracture, with some of the symptoms of dislocation. Mr. Stanley 189
103. Oblique fracture of the upper part of the thigh-bone, showing the use of plaster of Paris. Mr. G. Bond, of Glastonbury . 191
104. Partial dislocation of the patella outwards . . . 195
105. Repeated dislocation of the right patella inwards from slight causes 196
106. Dislocation of both patellæ outwards, which went in of themselves when the legs were straightened . . . . *ib.*
107. Dislocation of the patella outwards; reduction difficult. Mr. G. Young *ib.*
108. Patella turned half round in its place; reduced with considerable difficulty by pressing the edges of the bone in opposite directions. Mr. Welling, of Hastings 197
109. Patella dislocated on the external condyle and resting on its edge; reduction effected by bending the knee to its utmost. Mr. Herbert Mayo . . . . . . *ib.*
110. Dislocation of the patella, which was turned half round and rested with its edge in the centre of the condyles; reduction not effected even although the tendons and extensor muscles were divided; death in eleven months from suppuration of the knee-joint . 198
111. Dislocation of the patella on the inner condyle in a young woman of twenty; death in a fortnight from inflammation of the joint. Mr. Key 202
112. Dislocation of the tibia inwards at the knee-joint . . 205
113. Same dislocation. Mr. B. Cooper . . . *ib.*
114. Dislocation of the tibia outwards at the knee-joint . . 206
115. Dislocation of the tibia inwards at the knee-joint, succeeded by great swelling and œdema. Mr. Richards . . . *ib.*
116. Dislocation of the tibia forwards at the knee-joint . . 207
117. Same dislocation. Mr. Herbert Mayo . . . 208
118. Same dislocation. Dr. O'Beirne 209
119. Same dislocation. Dr. Franklin, of Limerick . . 210
120. Dislocation of the tibia backwards at the knee-joint. Dr. Walshman 211
121. Partial dislocation of the semilunar cartilages, unreduced . 213
122. Same dislocation, frequently recurring . . . *ib.*
123. Same dislocation, followed by rheumatic inflammation of the joint 214

CASE PAGE

124. Dislocation of the external semilunar cartilage of the right knee, which could not be reduced. Mr. Luke . . . 215
125. Compound dislocation of the knee-joint, amputated . . 217
126. Compound dislocation of the knee-joint; the popliteal artery ruptured; spachelus of the foot; amputation after a month; recovery. Mr. Shaw, of Wirksworth 218
127. Dislocation of the head of the left fibula backwards; displacement kept up by the biceps. Dr. Bossey, of Woolwich . . 222
128. Transverse fracture of the patella 225
129. Case of the same . . . . . *ib.*
130. Fracture of both patellæ; efficacy of passive motion in restoring the use of the limbs 230
131. Fracture of the patella; union by a ligament three inches in length; great weakness of limb 231
132. Fracture of the patella; upper fragment very small; great difficulty of preserving apposition. Mr. Okes, of Cambridge . . *ib.*
133. Patella fractured transversely, and lower portion also broken perpendicularly; transverse fracture united by ligament; perpendicular by bone. Mr. Parrott, of Tooting . . . 233
134. Compound fracture of the patella, followed by violent inflammation and death. Mr. W. Cooper 234
135. Fracture of the patella with a small wound extending into the joint, followed by inflammation and death . . . *ib.*
136. Compound fracture of the patella; recovery with an anchylosed joint. Mr. Hawker . . . . . *ib.*
137. Compound fracture of the patella; wound extending into joint; complete recovery. Mr. Dixon . . . *ib.*
138. Compound fracture of the right patella; recovery with a perfectly useful limb 235
139. Compound comminuted fracture of the patella, with wound leading into joint; perfect recovery in six weeks. Mr. B. Cooper . 236
140. Gun-shot wound of the right knee, carrying away nearly the whole of patella, and completely exposing the joint; recovery in four months. Mr. Ward, of Nottingham . . . 237
141. Ligamentous union of the patella perforated by an ulcer which opened the joint; death 240
142. Compound fracture of the condyles of the femur in a boy; complete recovery. Mr. Travers 241
143. Same fracture in a man aged seventy-six; death. Mr. Rowe . 242
144. Oblique fracture of the os femoris above the condyles; rectus muscle perforated by the upper fragment . . . 244
145. Oblique fracture of the os femoris just above its condyles; great difficulty in preventing projection of the upper portion. Mr. Welbank, jun. 245
146. Same fracture; the upper portion of the bone protruded through the skin, and was sawn off 248

CASE PAGE

147. Dislocation of the tibia inwards at the ankle-joint. Mr. Bedford . 254
148. Partial dislocation of the tibia forwards at the ankle-joint, not reduced. Mr. Tyrrell 256
149. Unreduced dislocation of the left ankle-joint forwards. Mr. Douglas, of Glasgow 257
150. Fracture of the tibia and fibula just above the ankle-joint, with some of the symptoms of dislocation backwards. Mr. Douglas, of Glasgow 259
151. Compound dislocation of the ankle-joint; surprise of a surgeon that the patient could recover 267
152. Compound dislocation of ankle-joint; exfoliation of part of the astragalus; recovery. Dr. Lynn . . . 268
153. Compound dislocation of ankle-joint; astragalus shattered; recovery. Mr. Battley . . . . . . *ib.*
154. Compound dislocation of left ankle-joint outwards, with fracture of tibia. Mr. Rowley 269
155. Compound dislocation of ankle-joint outwards, with oblique fracture of inner malleolus; complete recovery in two months. Mr. Ward. 270
156. Compound dislocation of ankle-joint inwards; fracture of tibia: bad fracture of fibula; gradual recovery after some months. Mr. Clarke *ib.*
157. Two cases of compound dislocation of ankle-joint inwards; one recovered in five, the other in seven weeks. Mr. Somerville . 271
158. Compound dislocation of ankle-joint, tibia, and fibula, protruding at the outer, the astragalus at the inner ankle; complete recovery in about twelve months. Mr. Scarr, of Bishop's Stortford . 273
159. Bad compound dislocation of tibia; fracture of fibula a few inches above ankle-joint, in a man of very bad constitution, aged seventy; complete recovery. Mr. Abbott, of Needham Market . 274
160. Compound dislocation of left ankle-joint inwards, with both bones fractured, and fracture of right thigh; recovery with a stiff joint. Mr. Chandler 276
161. Compound dislocation of tibia forwards, with fracture of fibula; use of joint recovered in five months. Mr. Maddocks . . 279
162. Bad compound dislocation of tibia and fibula outwards, with great laceration of integuments; extensive sloughing; recovery in fifteen weeks. Mr. Ormond, of Trowbridge . . . 280
163. Compound dislocation of ankle-joint without fracture of tibia or fibula. Mr. Liston 283
164. Compound dislocation of tibia outwards, with fractured fibula also protruding; removal of end of tibia and an inch of fibula; recovery with very little lameness 286
165. Compound dislocation of ankle-joint inwards; end of tibia sawn off 287
166. Compound dislocation of right ankle inwards; tibia protruding three inches; fibula broken; end of tibia sawn off. Mr. Averill . 289
167. Compound dislocation of tibia and fibula outwards, with fracture of the astragalus; fractured portion removed. Dr. Rumsey . 290

CASE PAGE

168. Compound dislocation of ankle-joint inwards; tibia and fibula protruding four inches; an inch and a half of their ends removed; recovery with little shortening. Mr. Hicks, of Baldock . 294
169. Compound dislocation of ankle-joint outwards, with fracture of tibia and fibula, which protruded, and their ends sawn off before reduction could be effected. Mr. Cooper, of Brentford . . 296
170. Dislocation of tibia forwards and a little inwards; fracture of the fibula two inches above outer malleolus. Mr. Tyrrell . 298
171. Compound dislocation of ankle; protruded tibia sawn off; anterior tibial artery taken up; recovery. Mr. Carden, of Worcester . 299
172. Compound dislocation of tibia inwards at the ankle; very extensive laceration; amputation 301
173. Same dislocation; great loss of integument; amputation seven weeks after. Mr. Green . . . . *ib.*
174. Same dislocation; bones extremely shattered; amputation on the sixteenth day; recovery 302
175. Compound dislocation of ankle-joint; bones displaced by repeated spasms; amputation. Mr. Andrews and Mr. Foote . . 304
176. Compound dislocation of ankle-joint; amputation necessary for deformity after two years. Mr. Norman . . . 308
177. Compound dislocation of the tibia inwards; death from tetanus *ib.*
178. Case in which a brewer's man, with a very irritable constitution, died from running a splinter of wood into his thumb . . 309
179. Compound dislocation of ankle; spasms of muscles of leg; great constitutional disturbance, delirium, and death at the end of a week 310
180. Dislocation of ankle-joint from ulceration . . . 312
181. Dislocation of tibia inwards and forwards, with fracture of fibula; tibia reduced, but repeatedly thrown out of position by action of muscles; the last time protruded through skin; amputation and death. Mr. Earle . . . . . . *ib.*
182. Displacement of the foot upwards between the tibia and fibula, without fracture of either. Mr. Luke . . . 316
183. Oblique fracture of tibia an inch and a half above ankle-joint, of fibula near its centre. Death on fifth day, from gangrenous inflammation of leg 319
184. Oblique fracture of tibia and fibula . . . 320
185. Dislocation of the tendon of peronæus longus from its sheath. Mr. Sankey 321
186. Dislocation of the astragalus outwards; tibia broken obliquely at the inner malleolus; attempts to reduce the bone fruitless; great deformity. Mr. James 322
187. Dislocation of astragalus, which sloughed out . . 323
188. Simple dislocation of astragalus backwards, unreduced, causing little inconvenience. Mr. B. Phillips 325
189. Same dislocation, unreduced; scarcely any lameness remained five months after accident. Mr. B. Phillips . . . 326
190. Compound dislocation of the astragalus; amputation . . 328

CASE PAGE

191. Compound dislocation of ankle-joint, with exfoliation of astragalus; recovery. Dr. Lynn 328
192. Compound luxation of astragalus; bone cut out; good recovery, with tolerable useful foot. Mr. Trye . . . . . *ib.*
193. Dislocation of astragalus inwards from the navicular bone and os calcis, reduced and cured. Mr. Henry Cline . . *ib.*
194. Compound dislocation of astragalus outwards; head of bone exposed. Mr. Green 329
195. Compound dislocation of the astragalus; laceration of posterior tibial artery; removal of the astragalus; recovery. Mr. Green . 330
196. Compound comminuted fracture and dislocation of the astragalus; removal of the bone; death in three weeks. Mr. Liston . 331
197. Compound dislocation of the astragalus, which was removed; death in ten days. Mr. J. S. Miles 333
198. Extensive fracture of lower ends of tibia and fibula, with compound dislocation of astragalus inwards. Mr. B. Cooper . . 335
199. Dislocation of anterior bones of tarsus from os calcis and astragalus; complete recovery 336
200. Compound dislocation of astragalus from navicular bone and os calcis. Mr. South . . . . . . *ib.*
201. Partial dislocation of the three cuneiforme bones upwards, reduced. Mr. Luke 338
202. Partial dislocation of scaphoid and cuboid bones; foot shortened half an inch. Mr. Liston . . . . . . *ib.*
203. Compound dislocation and fracture of distal extremity of metatarsal bone of great toe. Mr. Liston . . . . . *ib.*
204. Dislocation of the toes from the metatarsal bones . . . 339
205. Fracture of the os calcis from contraction of the gastrocnemii. Mr. Marsden . . . . *ib.*
206. Same fracture, united by ligament. Mr. Green . . . 340
207. Dislocation of the jaw in a madman 343
208. Dislocation of the jaw, from puerperal convulsions, reduced at the end of a month. Mr. Morley 345
209. Supposed dislocation of the os malæ. Mr. Gossett . . . 347
210. Dislocation of clavicle forwards. Boyer 352
211. Dislocation of sternal extremity of clavicle backwards by accident, increased by progressive distortion of spine so as to press upon the œsophagus; removal of extremity of bone. Mr. Davie . . 354
212. Dislocation of acromial extremity of clavicle. Mr. Key. . 358
213. Dislocation of scapular extremity of clavicle, with fracture of the acromion. Mr. South 359
214. Dislocation of the shoulder into the axilla, with unusual mobility. Mr. Stedman 370
215. Dislocation of the humerus into axilla; three attempts made at reduction before they succeeded. Mr. Bedford . . . *ib.*
216. Spontaneous reduction of dislocation into the axilla . . . *ib.*

CASE PAGE

217. Dislocation of the shoulder in a muscular man, of five months' standing, recommended not to be attempted to be reduced . 371
218. Dislocation of the shoulder into the axilla, of two months' standing; rupture of axillary artery in reduction; death. Dr. Gibson, of Pennsylvania . . . . . . *ib.*
219. Dislocation of the humerus into the axilla; the axillary artery ruptured; death. Mr. Bellingham, of Uckfield . . *ib.*
220. Dislocation of humerus into axilla, reduced by hanging over a five-barred gate 378
221. Dislocation of the humerus, attempted to be reduced seven weeks after the accident unsuccessfully; advised against any further attempt at the end of eleven weeks . . . 380
222. Reduction of a dislocation into the axilla of three months' standing. Mr. B. Cooper 382
223. Dislocation of the right shoulder, with fracture of the humerus; dislocation unreduced. Mr. Peck . . . . *ib.*
224. Dissection of a recent dislocation of humerus forwards. Mr. Curling 385
225. Dislocation forwards of the humerus, reduced . . 388
226. Unreduced dislocation of the os humeri forwards under the clavicle. Mr. J. Mash, of Northampton 389
227. Dislocation of the humerus forwards, reduced after nine weeks and six days . . . . . . *ib.*
228. Dislocation of the shoulder backwards, reduced . . 392
229. Same dislocation, reduced. Mr. B. Cooper . . . *ib.*
230. Same dislocation, reduced. Mr. Key . . . 393
231. Same dislocation, reduced. Mr. Dunn . . . 394
232. Same dislocation from muscular spasm, not reduced. Mr. Key . *ib.*
233. Same dislocation, reduced. Mr. Toulmin . . . 398
234. Same dislocation, reduced. Mr. C. M. Coley . . 399
235. Partial dislocation of the humerus forwards and inwards against the coracoid process 400
236. Same dislocation, not reduced . . . . *ib.*
237. Dissection of a case of partial dislocation of the humerus forwards. Mr. Patey 401
238. Dissection of the same accident. Mr. Douglas . . 402
239. Displacement of the long head of the biceps, with dislocation of the humerus upward. Mr. John Soden, jun. of Bath . . 403
240. Dislocation of the shoulder, followed by spasms and œdema . 407
241. Rupture of the tendon of the biceps. Mr. Stanley . . 408
242. Compound dislocation of humerus forwards; reduction and cure in fourteen months. Mr. Dixon 409
243. Fracture of the neck of the scapula . . . 413
244. Same fracture. Mr. Alderman Partridge, of Colchester . 415
245. Same fracture; union in seven weeks without deformity . 416
246. Fracture of neck of humerus within capsular ligament, with dislocation of the head forwards, unreduced . . . 418

CASE PAGE
247. Fracture of the anatomical neck of the humerus; head dislocated and anchylosed to the inferior costa of the scapula . . 419
248. Same accident. Mr. J. N. Heale 420
249. Comminuted fracture of upper extremity of humerus, with dislocation. Mr. Hingestone 421
250. Dislocation of the head of the humerus broken from the shaft, into the axilla. Mr. B. Cooper 425
251. Fracture of the coracoid process, acromion, and humerus at its anatomical neck; death eight weeks after from apoplexy. Mr. Webster 428
252. Fracture of the neck of the humerus in a child æt. ten years . 431
253. Same fracture treated by raising and supporting the humerus in a right angle with the side. Mr. Tyrrell . . . ib.
254. Humerus broken at its anatomical neck, and forced through the pectoral muscle. Mr. Guthrie . . . . ib.
255. Fracture of the surgical neck of the humerus nearer its head than usual; recovery. Mr. Blenkarne . . . 433
256. Oblique fracture through the head and neck of the humerus; death. 434
257. Compound fracture of head of humerus; end sawn off. Mr. Morley, Uttoxeter 435
258. Fracture of the greater tubercle of the humerus. Mr. Herbert Mayo ib.
259. Dislocation of the radius and ulna backwards at the elbow, reduced. Mr. Stedman 442
260. Compound dislocation of the elbow-joint; recovery. Mr. Samuel White . . . . . . ib.
261. Dislocation of radius and ulna backwards, with wound near joint; death in four days. Mr. Key 444
262. Same dislocation, with fracture through the external condyle. Mr. B. Cooper 445
263. Same dislocation, with fracture of internal condyle. Mr. James, of Exeter 446
264. Dislocation of the elbow inwards, reduced by extending the arm . 449
265. Dislocation of the ulna inwards and backwards, reduced. Mr. M. Gossett 451
266. Dislocation of the radius forwards, unreduced. Mr. Cline . 453
267. Same dislocation, unreduced . . . . ib.
268. Same dislocation, reduced during a state of syncope . . ib.
269. Same dislocation, reduced by extension from the hand without including the ulna . . . . . ib.
270. Same dislocation, unreduced . . . . ib.
271. Unreduced dislocation of radius forwards, of six or seven months' standing; patient advised against an attempt at reduction. Mr. Tyrrell 454
272. Dislocation of radius forwards, caused by the action of the flexor muscles. Mr. Adams, of Dublin . . . 455
273. Dislocation of the radius forwards, reduced. Dr. Rumsey, of Beaconsfield . . . . . . ib.

CASE PAGE

274. Dislocation of the radius forwards, with fracture through sigmoid cavity of ulna 456
275. Same dislocation, with fracture of internal condyle of humerus. Mr. B. Cooper 457
276. Same dislocation, with fracture of radius an inch and a half below its head. Mr. B. Cooper . . . . . *ib.*
277. Dislocation of radius backwards, reduced. Mr. May, of Reading 460
278, 279. Same dislocations, reduced. Professor Langenbeck . *ib.*
280. Same dislocation, unreduced, with fracture through coronoid process of ulna. Mr. B. Cooper 462
281. Lateral dislocation of radius, unreduced. Mr. Freeman . . *ib.*
282. Oblique fracture of humerus above the condyles. Mr. D. B. Major 463
283. Severe compound fracture of extremity of humerus, with transverse fracture two inches and a half above the condyles. Mr. Ivimy, of Portsea 465
284. Oblique fracture of humerus, with unreduced dislocation . *ib.*
285. Fracture of internal condyle of humerus, with fracture of olecranon 466
286. Fracture of coronoid process of ulna . . . 469
287. Same fracture in a boy, caused by hanging a long time from a wall. Mr. Liston 470
288. Fracture of olecranon. Mr. B. Cooper 471
289. Same fracture 475
290. Same fracture, complicated with fracture of internal condyle. Mr. B. Cooper 476
291. Compound fracture of elbow-joint ; recovery . . . 477
292. Same fracture ; recovery 478
293. Same fracture ; recovery . . . . *ib.*
294. Same fracture ; death 479
295. Severe compound fracture of elbow-joint ; excision of joint ; recovery. Mr. M'Intyre, of Newcastle . . . *ib.*
296. Same injury ; excision of joint ; recovery. Mr. M'Intyre . 480
297. Dislocation of one wrist forwards and the other backwards, produced by a force applied in the same manner to both. Mr. Rudall, of Sheepwash 485
298. Dislocation of wrist-joint from convulsive fits ; reduced after two years 487
299. Compound dislocation of wrist-joint ; amputation. Mr. B. Cooper 488
300. Dislocation of ulna at the wrist. Mr. Sylvester . . 491
301. Dislocation of radius and ulna forwards, in left hand, with fracture of radius of opposite arm. Mr. Taylor . . . 494
302. Compound dislocation of ulna at the wrist, with fracture of radius ; recovery. Mr. P. Cartwright 496
303. Same dislocation, with bad fracture of radius ; amputation after five weeks 497
304. Same dislocation, with fracture of radius ; recovery. Mr. Steel, of Berkhampstead 498

CASE PAGE

305. Compound dislocation of ulna at wrist-joint, followed by anchylosis, for which the arm was amputated by a surgeon. Mr. Davies, of Merthyr 499
306. Oblique fracture of radius through its lower articulating surface; fractured portion with os scaphoides thrown backwards on the carpus. Mr. F. R. Elkington 501
307. Dislocation of os magnum backwards, reduced. M. Richerand 502
308. Repeated dislocation of os magnum backwards. Mr. B. Cooper 503
309. Compound dislocation of scaphoid bone; recovery nearly complete. Mr. Fagg 504
310. Compound comminuted fracture of metacarpal bones of middle and ring fingers; recovery, with a useful hand . . 506
311. Severe gun-shot vound of hand; fore-finger only left . . *ib.*
312. Hand crushed in a man æt. seventy-two; amputation. Mr. B. Cooper 507
313. Compound dislocation of second phalanx of thumb, reduced. Dr. Penneck, of Penzance 512
314. [illegible]location of the metacarpal bone from the trapezium . . 514
315. Compound dislocation of thumb, and recovery of its use. Mr. G. Cooper . . . . . . *ib.*
316. Compound dislocation of first phalanx of thumb; reduction; complete recovery 518
317. Dislocation of last phalanx of thumb; reduced easily. Mr. B. Cooper *ib.*
318. Dislocation of last phalanx of thumb backwards; reduced. Mr. B. Cooper 519
319. Compound dislocation of last phalanx, reduced, and recovery complete. Mr. B. Cooper . . . . . *ib.*
320. Dissection of dislocation of head of seventh rib on corresponding vertebra. Mr. Webster, of St. Albans . . . 521
321. Displacement of cartilages of fifth and sixth ribs from their junction with the sternum. Mr. B. Cooper . . . 522
322. Concussion of spinal marrow; complete recovery in ten weeks. Dr. Curry 526
323. Same injury, relieved by fomentation and cupping . . 527
324. Same injury; imperfect recovery. Mr. Herbert Mayo . . *ib.*
325. Same injury; threatening inflammatory softening of spinal cord. Mr. Herbert Mayo . . . . . *ib.*
326. Fatal concussion of spinal cord; no disorganization found. Boyer 528
327. Concussion of spinal cord; death on twelfth day. Boyer . *ib.*
328. Death from injury to spine; sheath of cord found lacerated, and medullary matter exuded through the openings . . 529
329. Death from inflammation of ligamentous structures of spine extending to sheath of spinal cord. Boyer . . . . *ib.*
330. Extravasation into spinal canal; death after a year. Mr. Heaviside 530
331. Fracture of spinous process of third dorsal vertebra, without injury to cord. Mr. Key 532
332. Fracture of three or four spinous processes of cervical vertebræ; recovery . . . . . . *ib.*

CASE PAGE
333. Fracture of first cervical vertebra; death in a year . 533
334. Fracture of the atlas; odontoid process of axis broken off; death from pleurisy forty-seven weeks after the accident. Mr. B. Phillips . . . . . . *ib.*
335. Dislocation of the cervical vertebræ from turning the head suddenly. Boyer 535
336. Odontoid process of axis broken off; immediate death . . 536
337. Dislocation of neck from lifting a child by its head. Petit . *ib.*
338. Fracture of first and second lumbar vertebræ; death in twelve months. Mr. Harrold 539
339. Fracture of the body of first lumbar vertebra; death a year after. Mr. Key 541
340. Fracture of twelfth dorsal vertebra; death in three weeks. Mr. B. Cooper 544
341. Fracture of sixth cervical vertebra, without paralysis; death from erysipelas on the fourteenth day. Mr. B. Cooper . . 547
342. Fracture of ninth dorsal vertebra; involuntary contractions of muscles of thigh; death in nine weeks. Sir B. Brodie . 549
343. Fracture and displacement of third and fourth lumbar vertebræ; involuntary motions of lower limbs. Sir B. Brodie . . *ib.*
344. Dislocation and fracture of sixth and seventh cervical vertebræ; death. Mr. W. Baxter 550
345. Injury to the fourth or fifth cervical vertebra; imperfect paralysis; death in fifteen weeks. Mr. Greenwood, of Horselydown . *ib.*
346. Fracture of the sixth cervical vertebra; death in eight days. Mr. B. Cooper 551
347. Fracture of the lamina and transverse process of second cervical vertebra; death in four days. Ollivier . . . 555
348. Injury to the lumbar vertebræ; loss of sensation, but not of motion. Ollivier 556
349. Displacement of fourth cervical vertebra; temporary recovery; death after four months. Ollivier . . . . *ib.*
350. Fracture of tenth dorsal vertebra; loss of motion, but not entirely of sensation; death in six days. Ollivier . . . 557
351. Fracture, with depression of tenth dorsal vertebra; depressed portion removed; death in twelve days. Mr. Tyrrell . . 559
352. Operation for depression performed; death from disorganization of cord. Mr. Oldknow, of Nottingham . . . 560
352* Inflammation and softening of the spinal cord following the concussion of a blow 561

APPENDIX.

CASE PAGE

353. Fracture of the cervix femoris internal to the capsular ligament; recovery with good use of the limb. Mr. Sheppard, of Worcester 566
354. Ununited fracture of the tibia and fibula, in a strumous constitution; the bones repeatedly displaced by hysteric spasms. Mr. Bernard, of Crewkerne 569
355. Ununited oblique fracture of the tibia and fibula; disease of the heart and dropsy. Mr. Neville, of Esher . . 570
356. Ununited fracture of the femur; gouty inflammation of the knee. Mr. Phythian, of Somerset, Pennsylvania, North America . 571
357. Ununited oblique fracture of the tibia and fibula. Mr. Page, of Plymouth 572
358. Ununited oblique fracture of the tibia. Mr. Chandler, of Canterbury 573
359. Ununited fracture of the humerus; mercury successful. Mr. B. Cooper 574
360. Ununited fracture of the humerus; all remedies unsuccessful. Mr. Key 575

A

TREATISE ON DISLOCATIONS.

CHAPTER I.

ON DISLOCATIONS IN GENERAL.

A DISLOCATION, or luxation, signifies a displacement of the articulating portion of a bone from the surface on which it was naturally received.

Of the various accidents which happen to the body there are few which require more prompt assistance, or which more directly endanger the reputation of a surgeon, than cases of dislocation. If much time shall have elapsed before the attempt at reduction is made, the difficulty of accomplishing it is proportionably increased, and not unfrequently becomes insuperable: and if the nature of the injury be unknown, and the dislocation consequently be left unreduced, the patient will remain a living memorial of the surgeon's ignorance or inattention.

In a dislocation of the os femoris, which still remains unreduced, a consultation was held upon the nature of the injury, and after long consideration, a report was made by one of the surgeons to this effect: "Well, sir, thank God, we are all agreed that there is no dislocation."

A considerable share of anatomical knowledge is required to detect the nature of these accidents, as well as to suggest the proper means of reduction; and it is much to be lamented, that students neglect to inform themselves sufficiently of the structure of the joints. They often dissect the muscles of a limb with great neatness and minuteness, and then throw it away, without any examination of the ligaments, cartilages, or ends of the

bones; a knowledge of which, in a surgical point of view, is of infinitely greater importance; and from such negligence arise the errors into which those novices fall when they embark in the practice of their profession; for the dislocations of the hip, the elbow, and the shoulder, are scarcely to be detected, as to their precise nature, but by those who possess accurate anatomical information. Even our hospital surgeons, who have neglected their anatomy, mistake these accidents; and I have known the pulleys applied to an hospital patient, in a case of fracture of the neck of the thigh-bone, which had been mistaken for a dislocation, and the patient exposed, through the surgeon's ignorance, to a violent and protracted extension. It is therefore proper, that the form of the extremities of the bones, their mode of articulation, the ligaments by which they are connected, and the direction in which their most powerful muscles act, should be well understood. Moreover, the surgeon should make himself familiar with the external shape of the joints in the living subject, both in rest and in motion, and under every variety of action.

Yet it would be injustice not to acknowledge that the tumefaction arising from extravasation of blood, and the tension resulting from the inflammation which frequently ensues, may in the early days of the accident render it difficult for the best surgeon perfectly to ascertain the exact extent of the injury. Therefore conclusions afterwards formed, at a time when the swelling has dispersed, when the muscles have wasted, and when the head of the displaced bone can be distinctly felt, should be pronounced with caution, so that they may not tend to the prejudice of the individual who had at first all the difficulties to encounter. It may be justly recommended, both for the safety of the public and for the reputation of surgeons, that the diagnosis should be withheld in cases of accidents to joints, while tumefaction renders the nature of the injury obscure; the patient being told that the difficulties which attend an early decision are generally removed when the swelling of the soft parts has subsided.

Symptoms.—The immediate effect of dislocation is to change the form of the joint, and to produce more or less alteration in the length of the limb; to occasion the almost entire loss of motion in the part after the muscles have had time to contract;

and to alter the axis of the limb. This altered position of the limb has been attributed, by some surgeons, to the influence of the remaining portion of capsular ligament; but in each kind of dislocation, the direction of the bone is so invariably the same, that we must believe it to be chiefly the effect of muscular influence; for the ligament is almost always extensively torn; in most cases scarcely any portion of it remains whole, particularly in dislocations of the thigh; yet the position of the limb under the different species of dislocation, is found subject to little variation. The form of the bone has, however, some influence on its future position: for in fractures of the neck of the thigh-bone, the knee is turned outwards; whilst in three out of the four dislocations of the hip, it is turned inwards: a circumstance which arises from the greater tendency of the bone to roll upon its axis when its neck is broken.

In the first moments, however, after dislocation, considerable motion often remains, and the position is not so determinately fixed as it afterwards becomes; for I have seen a man brought into Guy's Hospital, who, but a few moments before, had the thigh-bone dislocated into the foramen ovale, and I was surprised to find in a case otherwise so well marked, that a great mobility of the bone still existed at the dislocated part; but in less than three hours, it became firmly fixed in its new situation by the permanent, or, as it is called, *tonic* contraction of the muscles.*

In some dislocations the limb is rendered shorter, and thus the muscles influenced by it are immediately thrown into a state of relaxation; but if the limb be elongated, the tension of the principal muscles around the joint is extreme, and they are sometimes stretched to laceration. Blood is often effused in considerable quantity around the joint, which renders detection of the accident difficult; the swelling being sometimes so considerable as to conceal entirely the ends of the bones. This effusion is in proportion to the size and number of the vessels lacerated.

A severe but obtuse pain arises from the pressure of the head of the bone upon the muscles, and, in some cases, this pain is rendered more acute from its pressure upon large nerves. From this cause also may be produced a paralysis of the parts below,

* This extent of mobility would not have been present in any other dislocation of the hip joint, but into the foramen ovale, so that the comparative greater mobility present in this luxation forms one of its diagnostic marks.—*Ed.*

instances of which occur in dislocations of the shoulder. In other cases, the bone may press upon important parts, so as to produce effects dangerous to life. I have for many years mentioned in my lectures, a case of dislocated clavicle pressing upon the œsophagus so as to endanger life; of which Mr. Davie, of Bungay, was so kind as to send me an account. A more detailed account of this case will be given hereafter.

In most dislocations, the head of the bone may be readily felt in its new situation, and may be felt to move during rotation of the limb: thus furnishing the surest criterion of the nature of the accident. The natural prominences of the dislocated bone, in some instances, either disappear, or become less conspicuous,—as the trochanter in luxations of the hip-joint; but the contrary result ensues in dislocations of the elbow; for there the olecranon is more than usually prominent, and serves as the principal guide for discovering the nature of the injury.

Some time after the accident it frequently happens that a sensation of crepitus is produced by the effusion of adhesive matter into the joint and surrounding bursæ; the synovia in which becomes inspissated, and crackles under motion. But every practitioner ought to be able to distinguish this *crackling* from the *grating* crepitus of fracture.

Consequences.—The degree of inflammation which succeeds to these accidents is generally slight; but in some cases it is very considerable, and produces a great tumefaction, which, added to that resulting from extravasation of blood, frequently renders the detection of the injury exceedingly difficult. Sometimes, after the reduction of dislocations, suppuration ensues, and the patient falls a victim to excessive discharge and irritation. Mr. Howden, who was one of our most intelligent apprentices at Guy's Hospital, and was afterwards surgeon in the army, related the following case:—"A man had his thigh dislocated upwards and backwards on the ilium, which was soon after reduced; the next day a considerable swelling was observed on the part, which continued to increase, accompanied with rigors, and in four days the patient died. On dissection, the capsular ligaments, and ligamentum teres, were found entirely torn away, and a considerable quantity of pus extravasated in the surrounding parts."* I attended the master of a ship,

* See Minutes of the Physical Society, Guy's Hospital, Nov. 12th, 1791.

who had dislocated his thigh upwards; an extension was made, apparently with success; but in a few days a large abscess formed on the thigh, which destroyed the patient. Fortunately, however, such a result is by no means common.*

Appearances on Dissection.—On examination of the bodies of persons who die in consequence of recent dislocations arising from violence, the head of the bone is found completely removed from its socket. The capsular ligament is torn transversely to a great extent; the peculiar ligaments of joints, as the ligamentum teres of the hip, are torn through: but the tendinous origin of the biceps, in dislocation of the os humeri, remains uninjured, as far as I have been able to ascertain by dissection; although I would by no means be understood to say that this is universally the case.†

The tendons which cover the ligaments are also torn; as the tendon of the subscapularis muscle, in the dislocation into the axilla; and, according to the extent of this laceration, is the facility with which the accident recurs after reduction,—a circumstance frequently very difficult to obviate.

The muscles are also influenced by the nature of the accident, being in some cases put upon the stretch, even to laceration; as the pectineus and adductor brevis, in dislocations of the thigh downward: and large quantities of blood frequently become extravasated into the cellular membrane.

Unreduced Dislocation.—When, from length of time, or any other cause, the reduction of the limb is rendered impracticable, the bone forms for itself a new socket, and some degree of motion is gradually recovered; although in neglected dislocations of the lower extremity, the patient is ever after lame; and in those of the upper, the motion and power of the limb are very much diminished.

The appearance of joints which have long been dislocated, depends not only on the length of time that has elapsed from the accident, but also on the structure upon which the head of the dislocated bone is thrown; for if it be found embedded in muscle, its articular cartilage remains, and a new capsular ligament forms around it, which does not adhere to its cartilaginous surface. This ligament in dislocations of the femur contains

* A case of the kind is described among the cases of dislocation on the pubes.

† It is sometimes ruptured.—*Ed.*

within it the head of the bone, with the lacerated portion of the ligamentum teres united to it. In these instances, the bones themselves undergo little change. The capsular ligament is formed from the surrounding cellular tissue; which, being pressed upon by the head of the bone, becomes inflamed, thickened, and condensed. By these means a substance is produced somewhat less dense than original ligament, but still possessing sufficient firmness to bear considerable pressure, and to furnish some degree of support.

But if the head of the dislocated bone be placed on the surface of another bone, or upon a thin muscle over it, that muscle becomes absorbed, and the bone undergoes a remarkable change. The pressure of the head of the bone produces absorption of the periosteum, and of the articular cartilaginous surface of the head of the bone; a smooth hollow surface is formed, and the ball becomes altered in its shape to adapt it to this new surface; and

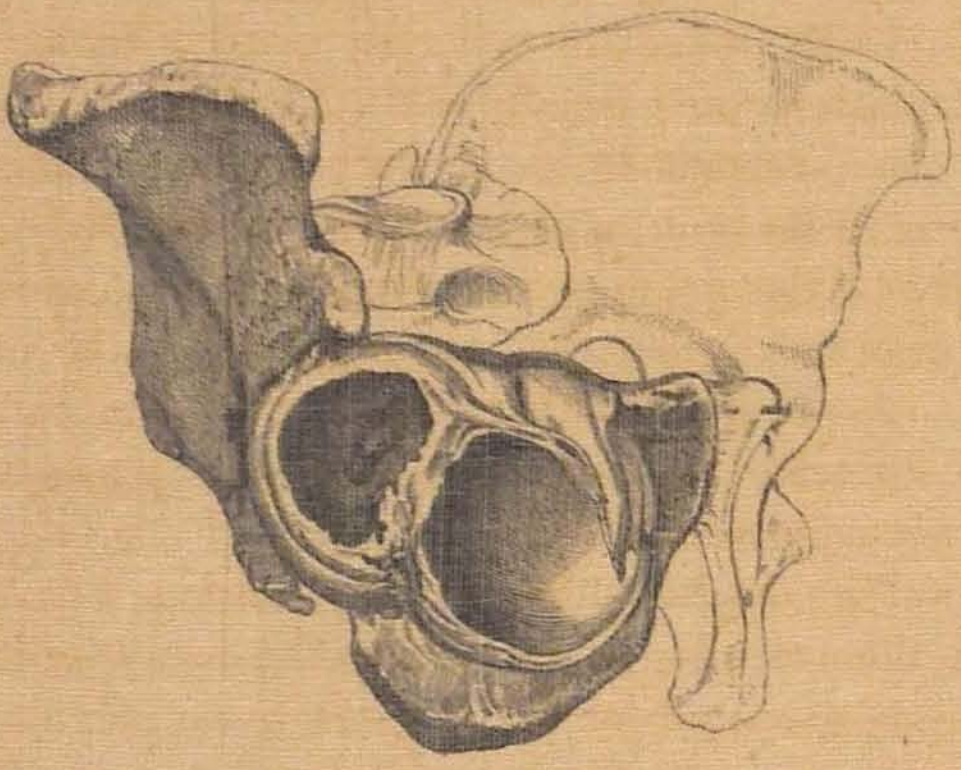

whilst this absorption proceeds upon the part on which the head of the bone rests, an ossific deposit takes place around it from the periosteum, which is there irritated, but not absorbed. By the deposition of this bony matter between the periosteum and the original bone, a deep cup is formed to receive the head of the bone; and perhaps no instances can be adduced which more strongly mark the powers of nature in changing the form of parts to accommodate them to new circumstances, than these effects of dislocation.

The new cup which is thus formed, sometimes so completely

surrounds the neck of the bone, as to prevent its being separated without fracture; and the socket is smoothed upon its internal surface, so as to leave no projecting parts which can interrupt the motion of the bone in its new situation.*

The muscles losing their action, become diminished in bulk, and reduced in their length, in proportion to the displacement of the bone towards their origin; and if the dislocation has been long unreduced, they lose their flexibility, and tear rather than yield to extension.

CAUSES.—Dislocations are generally occasioned by violence, and the displacing force usually takes effect whilst the bone is in an oblique direction to its socket; but the muscles must necessarily have been in a great degree unprepared for resistance, otherwise the greatest force would hardly have produced the effect: whereas, when they are unprepared, the injury will often ensue from very slight accidents. A fall in walking will sometimes dislocate the hip-joint, when the muscles are not exerting their influence to support the part.

While dwelling on this subject in my lectures, I have usually adverted to the execution of Damien, as illustrative of this fact.

Damien was executed for the attempt to murder Lewis XV. Four young horses were fixed to his legs and arms, and were forced to make repeated efforts to tear his limbs from his body, but they could not effect this purpose; and after fifty minutes, the executioners were obliged to cut the muscles and ligaments to produce his dismemberment.

The following is the French account of this execution:—

"Il arriva à la place de Grève à trois heures et un quart,

* Every structure essential to the new articulation seems to be formed excepting articular cartilage, which appears never to be reproduced, but in its stead a bony deposit takes place of peculiar density, and possessing the smoothness of porcelain.—*Ed.*

regardant d'un œil sec et ferme le lieu, et les instrumens de son supplice. On lui brula d'abord la main droite; ensuite on le ténailla, et on versa, sur ses plaies, de l'huile, du plomb fondu, et de la poix-résine. On procéda ensuite à l'écartellement. Les quatre chevaux firent pendant cinquante minutes des efforts inutiles pour démembrer ce monstre. Au bout de ce tems-là, Damien, étant encore plein de vie, les bourreaux lui coupèrent avec de bistouris les chairs et les jointures nerveuses des cuisses et des bras; ce qu'on avoit été obligé de faire en 1610 pour Ravaillac. Il respiroit encore après que les cuisses furent coupées, et il ne rendit l'âme que pendant qu'on lui coupoit les bras. Son supplice depuis qu'il fut mis sur l'echafaud, jusqu'au moment de sa mort, dura près d'une heure et demi. Il conserva toute sa connoissance et releva sa tête sept ou huit fois, pour regarder les chevaux; et ses membres ténaillés et brulés. Au milieu des tourmens les plus affreux de la question il avoit laissé échapper des plaisanteries."*

Dislocation from Relaxation. — Dislocations happening from violence are accompanied by laceration of the ligaments of the joint. But they may occur from relaxation of the ligaments only, of which the following cases are examples.

Case I.—A girl came to my house who had the power of throwing her patellæ from the surfaces of the condyles of the os femoris. Her knees were bent considerably inwards; and when the rectus muscle acted upon the patella, it was drawn from its natural position, and laid nearly flat upon the external condyle of the femur. She came from the south of Europe, where she had been brought up as a dancing girl from her earliest years, gaining her daily bread, as we see children in the streets of London, by dancing upon elevated platforms: and she imputed to these continued and early exertions the weakness under which she laboured.

I have seen more than one person capable of dislocating the first phalanx of the thumb from the metacarpal bone by the action of the muscles, the ligaments being relaxed.

I received the following curious case from Mr. Brindley, surgeon, at Winkhill.

Case II.—John Broadhurst, æt. fifty, rather of spare habit, has the power of dislocating and reducing either hip-joint at will.

* Dictionnaire Historique.

The way in which he effects it is by turning the limb considerably inwards, and bending the knee slightly, when the head of the femur immediately with a crack slips out in the direction backwards, and a little upwards, the neck resting upon the edge of the acetabulum, and by reversing the position of the limb the bone returns into its natural position, leaving only a little aching for a day or two. During the displacement the length of the limb varies but little, and that perhaps arises more from the knee being rather bent than from any real difference. The luxation is obvious across the room. The period when the dislocation first occurred he cannot precisely remember, nor that any particular accident occasioned its first occurrence, but believes it to be six or eight and twenty years ago, and that a simple change of position first produced it when it was rectified without surgical aid. The man is a common labourer in a saw-mill, but is subject to asthma, and he has also a hernia, showing a degree of relaxation in his system. It is worthy of remark that he can turn his toes in, and place his feet parallel, and also cross his legs and put his toe behind his heel. In either of these positions dislocation does not occur. Perhaps an hereditary laxity may be remarked, his brother being able to luxate any joint of his fingers at will. This man has not the power of dislocation in any other direction than what I have described.

Case III.—Miss Marshall, æt. twelve, had a fever; a month after which the head of the humerus easily slipped from its socket, but was easily replaced. I ordered a blister and small doses of oxymur. hydrargyri with tinct. cinchonæ. Electric sparks, cold affusion, sea-bathing, and vigorous friction, are other remedies that should be resorted to in similar cases.

A similar relaxation of ligaments is also produced by chronic inflammation with accumulation of synovia in joints, of which the following case is an example.

Case IV.—Anne Parish was admitted into Guy's Hospital in the autumn of 1810, for a dislocation of the left patella from relaxation of the ligaments. She had for four years previously a large accumulation of synovia in that knee, causing some pain, and much inconvenience in walking, and had been under the care of Mr. Shillito, surgeon at Hertford. Blisters had been applied without much effect, and other means tried for four months before her admission. When the knee had acquired considerable

size, the swelling spontaneously subsided, and she then first discovered that the patella became dislocated when she extended the limb. She suffered some pain whenever this happened, and she lost the power of the limb in walking, so that she fell when the patella slipped from its place, which it did whenever she attempted to walk without a bandage. The patella was placed upon the external condyle of the os femoris, when thrown from its natural situation, to which it did not return without considerable pressure of the hand. In other respects her health was good. Straps of adhesive plaster were ordered to be applied, and a roller to be worn, which succeeded in preventing the dislocation so long as they were used; but the bone again slipped from its place whenever they were removed. A knee-cap, made to lace over the joint, was ordered for her.*

Dislocation from Paralysis.—Dislocation sometimes arises from a loss of muscular power; for when the muscles are kept long and forcibly extended, their tone becomes destroyed; or if, from a paralytic affection, they lose their action, a bone may be dislocated easily, but it is as readily replaced: of the first of these two causes, the following case is an illustration.

Case V.—A gentleman who had passed some of his early life in the East Indies, happened, as a junior officer on board his ship, to be placed under the orders of one of the mates when the captain was on shore; and for some trifling offence was punished in the following manner:—his foot was placed upon a small projection on the deck, and his arm was lashed tightly towards the yard of the ship, and thus kept extended for an hour. When he returned to England, he had the power of readily throwing that

* Mr. Stanley at the Royal Med. Chir. Soc. on the 12th January, 1841, gave the results of six dislocations of the hip-joint. In the first case, both hip-joints were dislocated in the same individual, as a consequence of disease of the spinal cord, producing spasms, with impairment of motion and sensation in the lower extremities. In the second case, dislocation of the hip-joint occurred as the consequence of an attack of hemiplegia. In the third and fifth cases, rheumatic inflammation of the hip-joint was followed by its complete dislocation. In the fourth case the dislocation of the hip-joint was consequent on pain in the thigh, treated as sciatica. In the sixth case the dislocation of the hip-joint occurred in the sixth week of pregnancy, from a fall. In the second case, the opportunity had been obtained of dissecting the dislocated joint, when the following peculiarities were observed: — The capsule and ligamentum teres were entire, but elongated to the extent of allowing the head of the femur to pass beyond the limits of the acetabulum.—*Lancet*, 1840-41, vol. i. p. 624.—*Ed.*

arm from its socket merely by raising it towards his head, but a very slight extension reduced it; the muscles were also wasted, as in a case of paralysis.

Of the influence of paralysis, the following case is an example.

Case VI.—I was desired to see a young gentleman, who had one of those paralytic affections in his right side which frequently arise during dentition. The muscles of the shoulder were wasted; and he had the power of throwing his os humeri over the posterior edge of the glenoid cavity of the scapula, from whence it was easily to be reduced.*

Dislocation from Muscular Spasm.—Spasm of one set of the muscles connected with a joint, occurring at a time when their antagonists are unprepared to resist them, or when the joint is in a peculiar position, is a frequent cause of dislocation, especially of the jaw. But it must be noticed that dislocation seldom arises from this cause, unless the ligaments are previously relaxed.

Case VII.—Mr. Howard of St. Albans, who was the subject of hemiplegia, was seized with a violent spasm of the muscles of the left arm, during which attack the little finger was dislocated outwards by the action of its abductor muscle.

Case VIII.—Mr. Druitt once saw the little finger dislocated in consequence of an electric shock. An elderly woman was electrified for rheumatic pains in the arm; one metallic conductor being applied above the elbow, and another to the little finger. Upon a stronger shock than usual being given, she suddenly complained of great pain in the little finger, and upon examination it was found to have its second phalanx dislocated forwards on the first.

Dislocation from Ulceration.—Dislocations may arise from ulceration, by which the ligaments are detached, and the bones become altered in the form. We frequently find this state of parts in the hip-joint; the ligaments ulcerated, the edge of the

* There is a set of cases which have been particularly described by M. Dupuytren, in which dislocation of various limbs is produced in the fœtus in utero; hence these cases are styled *congenital dislocations*. They appear to be produced in consequence of a shortened and rigid state of some of the muscles connected with the affected joint—the same state in fact which produces club-foot, wryneck, and other distortions; and this state of the muscles is often connected with deficiency or disease of the brain or spinal cord. Vide a paper by M. Guèrin, Gaz. Méd. de Paris. March 1841.—*Ed.*

acetabulum absorbed, the head of the thigh-bone changed both in its magnitude and figure, escaping from the acetabulum upon the ilium, and there forming for itself a new socket. There is in the anatomical collection at St. Thomas's Hospital, a preparation of the knee dislocated by ulceration, anchylosed at right angles with the femur, and the tibia turned directly forwards. A boy, in Guy's Hospital, had his knee dislocated by ulceration, with the tibia thrown on the inner side of the external condyle of the os femoris; and a girl, in the same hospital, had the knee dislocated by ulceration, the head of the tibia being placed behind the condyles of the femur.

Case IX.—Mr. White, of Parliament Street, had under his care a patient in the Westminster Hospital, who was the subject of dislocation of the os femur on the dorsum of the ilium from ulceration. He sawed off the head of the femur, and the patient was restored to a very useful motion of the limb; he lived twelve years after, and then died of consumption. Mr. White gave the preparation to the College of Surgeons.

Dislocation complicated with fracture. — Dislocations are sometimes accompanied with fracture. At the ankle-joint, it rarely happens that dislocation occurs without a fracture of the fibula; and at the hip-joint the acetabulum is occasionally broken. Of this an example will be seen in the following case.

Case X.—Thomas Steers was admitted into Guy's Hospital on the 28th of October 1805, with a dislocation of the os femoris into the ischiatic notch. The dislocation was reduced by a very slight extension, compared with that which is commonly required: this was imputed to the muscular relaxation caused by nausea, the patient having vomited at the time of his admission. But he soon complained of severe pain extending over his abdomen, and he died on the day following his admission. Upon inspecting his body, the intestinum jejunum was found ruptured;

and upon examination of the hip-joint, a portion of the edge of the acetabulum was discovered to be broken off.*

Dislocations of the os humeri are also accompanied sometimes with fracture of the head of that bone, of which there is a specimen in the Museum of St. Thomas's Hospital. The coronoid process is occasionally broken in dislocations of the ulna; producing a species of luxation which does not permit the bone to be afterwards preserved in its natural situation.

When a bone is both broken and dislocated, it is proper to endeavour to reduce the dislocation without loss of time, taking care that the fractured part be strongly bandaged in splints, to prevent any injury to the muscles; for if the reduction be not accomplished at first, it cannot be afterwards effected without danger of re-producing the fracture.

If a compound fracture of the leg, and a dislocation of the shoulder, happen at the same time, the reduction of the arm should be undertaken immediately after the fractured limb has been secured in splints.

Case XI.—The Rev. Mr. H. being thrown from his chaise, had a compound fracture of the leg, and a dislocation of the shoulder forwards. The dislocation was not at first observed, nor was its reduction attempted till a fortnight had elapsed. The trial, however, proved unsuccessful; for, from a dread of fever and injury to the leg, sufficient extension could not be used.

Many of the accidents which have been called dislocations of the spine, are really fractures of the vertebræ, followed by displacement of the bones: even the articulating processes are broken, as well as the bodies of the vertebræ.†

* This case exemplifies the necessity of carefully investigating every circumstance connected with every injury, before pronouncing our prognosis, or proceeding to treatment. It is evident that the facility with which this dislocation was reduced, depended on the mortal injury to the intestines.—*Ed.*

† But yet the following cases prove that notwithstanding the number and breadth of the attachments of the vertebræ with each other, their firm union by ligaments, and muscles, and the very slight degree of motion that exists between them, still their articulating surfaces may be separated without fracture. The vertebræ most commonly dislocated are the fifth and sixth cervical. Boyer has related cases in which dislocation of the atlas from the vertebra dentata has occurred, and death was the immediate result.

Case XII.—Joseph York, æt. forty-five, was admitted into Guy's Hospital in 1833, with an injury to the spine produced by a barrow full of grains falling upon his head and neck from the height of fourteen feet. He immediately lost all

COMPOUND DISLOCATION.—In *compound dislocation*, not only the articulating surfaces of the bone are displaced, but the cavity of the joint is laid open by a division of the skin and the capsular ligament. The immediate effect of compound dislocation is to occasion the extravasation of blood into the joint, and to allow the escape of the synovia.

Compound dislocations are attended with great danger; for when a joint is opened, and the opening is not healed by adhesion, inflammation of the synovial surface speedily succeeds, and in a few hours is followed by suppuration. The cartilage rapidly ulcerates, and the bones become partially or entirely denuded; at length granulations spring from the extremities of the bones deprived of their cartilages, and fill up the cavity; generally these granulations become ossified, and anchylosis succeeds; but sometimes they remain of a softer texture, and some degree of motion in the joint is gradually regained, if proper attention is paid to passive motion during the cure.

motion and sensation of his lower extremities, and, upon further examination, it was found that all the intercostal as well as the abdominal muscles were paralyzed, so that respiration was carried on wholly by the diaphragm. He had partial priapism, and tympanitic abdomen, and complained of a general sensation of coldness, although the temperature of his body was at the natural standard. Having been placed in the prone position to examine his spine, it was found upon pressure over the sixth and seventh cervical vertebræ, that there was some motion of the bones, producing a pain which only extended upwards along the neck. The patient survived the accident only four days, and twenty-four hours after death he was examined. Upon exposing the cervical vertebræ, a complete laceration of the intervertebral substance between the fifth and sixth vertebræ was discovered, without any fracture; but the articulations between these two bones on the left side were completely dislocated, and their ligaments torn through. Upon removing several of the vertebræ for the purpose of examining the spinal marrow, a slight blush was found on the inner surface of the dura mater, but no læsion of the medulla spinalis.

CASE XIII.—An accident is recorded in the Medical Gazette of the 22nd of January 1831, which was admitted into the London Hospital under the following circumstances:—The patient was labouring under all the urgent symptoms of compression of the spinal marrow, which were attributed to fracture of the spine. He died on the day of his admission a few hours after the accident, when upon examination of his body it was found that the fifth and sixth cervical vertebræ were widely separated from each other, and without any fracture. The separation was so complete as to have admitted of a complete division of the medulla spinalis. Similar cases of dislocation of the fifth and sixth cervical vertebræ are related by Mr. S. Cooper, Med. Gaz. 30th April, 1841; and by Dr. Schuk of Vienna, Med. Gaz. 21st May 1841.—*Ed.*

This process of reparation in joints requires great general as well as local efforts: a high degree of constitutional irritation is usually produced; and, when nature is unable to support these efforts, it often becomes necessary to recommend amputation of the limb in order to preserve life.

In addition to the above circumstances, the violence inflicted on the neighbouring parts, the injury of the muscles and tendons, and the laceration of blood-vessels, necessarily lead to more important and dangerous consequences than those which follow simple dislocations.

I may remark that some joints are more liable to compound dislocations than others. The hip-joint is scarcely ever so dislocated; of the shoulder I have known two instances; but the elbow, wrist, ankle, and fingers, are frequently the seats of this accident; and I have seen an instance of it in the knee.

Partial Dislocation.—Dislocations are not always complete, since bones are sometimes but partially thrown from the articulating surface on which they rested. This species of dislocation now and then occurs at the ankle-joint. An ankle which was dissected at Guy's Hospital by Mr. Tyrrell, and afterwards given to the Museum at St. Thomas's, was found partially dislocated; the end of the tibia still rested in part upon the astragalus, but a larger portion of its surface rested on the os naviculare; and the tibia, altered by this change of place, had formed two new articulating surfaces, with their faces turned in opposite directions towards the two tarsal bones. This dislocation had not been reduced. The knee-joint is, I believe, rarely dislocated laterally in any other way; for its extensive articular surfaces almost preclude the possibility of complete displacement.

Dislocations of the shoulder-joint are also sometimes only

partial when the head of the os humeri rests upon the inner edge of the glenoid cavity immediately to the outer side of the coracoid process of the scapula. In the elbow-joint the lateral dislocations are generally only partial. Some authors have also described as partial the luxation of one side of the jaw; but this should certainly be classed amongst the complete dislocations.

Predisposing Causes.—In consequence of their different formation, we find that in some joints dislocation is much more frequent than in others. Those which have naturally the most extensive motions are the most easily dislocated; and hence the dislocation of the os humeri occurs much more frequently than that of any other bone; and having once occurred, it often happens again readily in the mere natural elevation of the arm. It it wisely ordained that, in those parts to which extensive motion is assigned, and for which great strength is required, there is a multiplicity of joints. Thus, in the spine, in which great strength is necessary to protect the spinal marrow, numerous joints are formed; and although the motion between any two of these bones is but inconsiderable, still from their combined motion a great degree of pliability is permitted, and at the same time the strength of the whole column is preserved.

The carpus and the tarsus are constituted on a similar principle; they allow of considerable motion, yet maintain great strength of union.

Old persons are much less liable to dislocations than those of middle life, because the extremities of bones in advanced age are often so brittle as to break under the force applied, rather than quit their natural situations. Persons of lax fibre are prone to dislocation, because their ligaments easily tear, and their muscles possess little power of resistance. From these circumstances old people would be exposed to frequent dislocations, but for the softened state of the extremities of their bones.

Young persons are also very rarely the subjects of dislocations from violence; but now and then such accidents do occur; and I have described an instance of them in a child at seven years of age. It generally happens that their bones break, or their epiphyses give way, rather than that the parts suffer displacement.

Thus dislocations of the elbow-joint in children are said to be of frequent occurrence. But I believe that most of such cases are, in reality, oblique fractures of the condyles of the os humeri,

which produce the appearance of dislocation, by allowing the radius and ulna, or the ulna alone, to be drawn back with the fractured condyle, so as to produce considerable projection at the posterior part of the joint.

I have read of dislocations of the hip in children, but their history is that of diseases of the hip-joint, in which the dislocation has arisen from ulceration. A child was brought to me from one of the northern counties, with a supposed dislocation of the hip-joint, for which repeated extensions had been made by one of those people called *bone-setters*,—but who ought rather to be called *dislocators.* Upon examination, I found it to be that disease of the hip so common in children; and for this only, was a child ignorantly exposed to a most painful extension. This is but one of the many instances that have come under my observation, of the mischief inflicted by these ignorant adventurers; which, however, is in general richly enough deserved, by those who have the folly to prefer them to the regularly educated surgeon. The manner in which these fellows acquire their reputation is obvious enough. They are called in to some case of mere strain or bruise which is tedious in getting well under the hands of the surgeon; they immediately pronounce it a dislocation, and employ certain manœuvres by which they pretend to reduce it, which, of course, they do easily enough; and then they blame the surgeon for not having detected and reduced it before, and ascribe the patient's slow recovery to his ignorance. I wish that I could say that ignorant quacks only were guilty of these disreputable practices; but, unluckily, there are not wanting even some surgeons, who basely endeavour to increase their own reputation by unjust imputations on their more honest neighbours. The following cases may be examples.

Case XIV. — Submitted to Sir A. Cooper, by J. R. B. June 10, 1839. A. B. about sixty-five years of age, strained, as he supposed, his right shoulder in breaking in a young colt, and three weeks afterwards he applied to me.

Upon stripping and carefully examining him, I found not the slightest deformity, and I could move his arm in all directions, but he could not elevate it himself. I gave as my opinion that he had strained the shoulder joint, which had taken on slight rheumatic inflammation, to which the man is liable. I advised fomentations and a sling, and colchicum with Dover's powder.

In three days afterwards I saw him again: he said he was better. I again examined his arm, and found nothing wrong. I ordered a blister and a continuance of the medicine. On leaving my house, a neighbour whom he met persuaded him to go to a young man lately settled in the town as a surgeon, who told him his arm was dislocated; and without any assistance lifted his arm up, bringing the palm of the hand to the back of the head, pressed his shoulder, and said he had reduced it. This was effected after the arm had been injured three weeks and three days; he was then dismissed without any bandage, and was directed to apply six leeches.

Do you think it possible that even a partial dislocation towards the coracoid process would be consistent with the facts of the above statement? or would the mode of reduction mentioned have been effectual after so long a period had elapsed since the injury? or would the reduction have remained permanent without any bandage?

The answer to these questions is of course negative.

Case XV. — Submitted to Mr. Bransby Cooper, by the late Mr. John Rowe of Winborne. John Islipp, sixty-three years of age, on Thursday, November 29th, fell in alighting from a cart, and very soon found that he had received some injury about the right hip-joint. On the following Sunday he was visited by a surgeon who, upon throwing aside the bedclothes, discovered his patient lying on his back with his left leg extended, the right leg bent, the foot turned out, and the heel approaching to the left leg about the centre of the tendo Achillis. The surgeon, grasping the left foot with his right hand, and the right foot with his left, brought both feet together; this motion occasioned some pain, but not very severe. The right leg spontaneously resumed the situation in which the surgeon had found it. He, therefore, expressed to his patient and his wife his opinion that the neck of the thigh bone was broken. He attended the patient until Wednesday, December 12, when, in consequence of the slow progress of the case, the patient's friends called in another surgeon, but not in consultation. This second surgeon quickly pronounced that the thigh bone was dislocated, and with the assistance of a mechanic, employing manual extension (the body not being fixed), soon succeeded, as he said, in reducing it. The patient continued in great pain a very long time after this opera-

tion. Eleven weeks after he was visited by the surgeon who first attended him, who found him still unable to quit his bed, with a shortened limb and the foot turned out.

This of course was a fracture of the neck of the thigh bone, as the first surgeon had pronounced it to be.*

DIAGNOSIS.—As I have recently observed, fractures near the joints are sometimes mistaken for dislocation. The general rule for distinguishing one accident from the other is this;—that in dislocation, generally speaking, the natural motions of the joint are impeded, not only as regards the patient's own efforts, but also the attempts of the surgeon to produce them; whereas in fracture there is a preternatural degree of mobility. Moreover, the natural length and appearance of the limb may be restored by extension, if there is a fracture, but the deformity will immediately reappear when the extension is desisted from;—whereas

* The following communication respecting the practice of one of these fellows is curious. It was sent to me by Dr. Hutchinson of Nottingham early in the present year.

"A well-known bone-setter in this county has been consulted in two or three cases of obscure accidents to the hip-joint, which baffled the skill and treatment of surgeons of average skill and experience; these accidents being considered by the surgeons as fractures of the neck of the thigh bone either within or without the capsule, and being attended by the usual symptoms characterising such cases, and treated as such unsuccessfully; this ignorant bone-setter, without the employment of other means than slight manipulations about the hip-joint, followed by a certain noise, he pretending these to have been cases of dislocation, has succeeded in affording the greatest benefit. The particulars relating to two such cases might be procured. Now, I know you will excuse an old pupil, and ardent admirer of the great improvements in treatment and extended knowledge of accidents to the joints which you have so eminently effected, in asking your opinion, as to the possibility of such cases being dependent not upon any injury to the joint of the hip itself or to the thigh bone, but whether it is not probable these obscure cases may not occasionally depend upon a separation of the tendon of the glutæus maximus where passing over the trochanter major? this displacement of the tendon being the result of accident occurring during certain positions of the limb. I have been induced to consider this possible, from being informed by one of these patients (a lady), that the operator pressed very strongly with his thumb over the trochanter major, and that she distinctly felt and heard something move, which sensation was immediately followed by a relief to pain and increased power over the movement of the limb; this pain having been constant previously, rendering the lady incapable of sitting for any length of time in the same posture; and supposing any truth in my view of the case, depending upon the pressure of the tendon of the glutæus maximus upon the great sciatic nerve."

in dislocation, it is much more difficult to restore the natural shape of the joint, but when once restored, it is permanent. Lastly, a grating crepitus may be detected by proper manipulation in cases of fracture, which can hardly be mistaken for the slight crackling that sometimes accompanies dislocation.

The following case is a curious example of the effects of spasm mistaken for dislocation.

CASE XVI.—A child, nine years old, complained suddenly of a violent pain in the right leg, and was unable to stand. M. Kluyskiens being summoned immediately, found the little patient in the following condition:—there was "tension douloureuse" of the right hip and knee; the limb was sensibly shortened; the hip bent; the thigh carried across the opposite limb; the thigh, knee, and foot turned inward; the great trochanter near the iliac crest; the fold of the groin was raised; and extension, abduction, and rotation outwards of the limb could not be effected. From these symptoms M. K. pronounced the case to be a dislocation. He was somewhat surprised, therefore, to find that they disappeared in the course of an hour, without any extension. The same shortening and distortion reappeared, however, at intervals during the next few weeks, so that it was manifest that they arose from spasm: they finally were cured by tonics and valerian.*

TREATMENT.—The reduction of dislocations is often difficult; and in some of the joints the form of the bone may occasion impediments. Thus, when the socket is surrounded by a lip of bone, as in the hip-joint, the head of the bone, during the attempt at reduction, stops at this projection, and requires to be lifted over it; another difficulty occurs when the head of the bone is much larger than its cervix; as, for example, in the dislocation of the head of the radius; but still these causes are slight in comparison with others which we have to detail.

The capsular ligaments are by some supposed to resist reduction; but those who entertain this opinion must forget their inelastic structure, and cannot have had opportunities of witnessing by dissection the extensive laceration which they sustain in dislocations from violence. The capsular ligaments, in truth, possess but little strength either to prevent dislocation, or to

* Quoted from the "Annales de la Société de Médecine de Gand," in the French Journal L'Expérience for October 29, 1840.—*Ed.*

resist the means of reduction; and if the muscles and tendons with which they are covered, and the peculiar ligaments of the joints did not exist, dislocation must be of very frequent occurrence.

The joint of the shoulder, and those of the knee and elbow, are strongly protected by tendons; the shoulder by those of the spinati, subscapularis and teres minor muscles; the elbow by the triceps and brachialis; the knee by the tendinous expansion of the vasti: but still some ligaments resist dislocations: these, however, are the peculiar, not the capsular ligaments. For instance, the wrist and the elbow have their appropriate lateral ligaments to give additional strength to these joints. The shoulder, instead of a peculiar ligament, has the tendon of the biceps received into it, which lessens the tendency to dislocation forwards; the ligamentum teres of the hip-joint prevents facility of dislocation downwards; the knee has its lateral, posterior, and crucial ligaments; and the ankle, exposed as it is to the most severe injuries, is provided with its deltoid and fibular tarsal ligaments of very extraordinary strength, to prevent dislocation. The bones of this joint often break rather than their ligaments give way; however, in many of the joints, as these ligaments are torn, they afford no resistance to the reduction of dislocations, as in the hip, elbow, and wrist. But if one of them remain entire, it may produce difficulty in the reduction, as I have seen in the knee and ankle joints; and it is often necessary to twist the foot, for the purpose of relaxing the untorn ligament, before reduction can be effected.

The difficulty of reducing dislocations arises principally neither from the bones, nor from the ligaments, but from the resistance which the muscles present by their contraction, and which is proportioned to the length of time which has elapsed from the injury; it is therefore desirable that the attempt at reduction should not be long delayed.

The common actions of the muscles are voluntary or involuntary; but they have a power of contraction independent of either state.

A muscle, when excited to action by volition, soon becomes fatigued, and requires rest. The arm can be extended, at right angles with the body, only for a few minutes before it feels a fatigue which requires a suspension of action.

But when a muscle is divided, its parts contract; or when the antagonist muscle is cut, the undivided muscle draws the parts into which it is inserted into a fixed situation. Thus, if the biceps muscle be divided, the triceps keeps the arm constantly extended; if the muscles on one side of the face be paralytic, the opposing muscles draw the face to their side. This contraction, which used to be called the *vis tonica*, is not succeeded by fatigue or relaxation, but will continue an indefinite time, even until the structure of the muscle becomes changed; and its contraction increases from the first occurrence of the accident. Thus it is, that when a bone is dislocated, the muscles draw it as far from the joint as the surrounding parts will allow, and there retain it by their contraction. It is this resistance from muscles, aided by their spontaneous contraction, which the surgeon is required to counteract. If an extension be made almost immediately after a dislocation has happened, the resistance produced by the muscles is easily overcome: but if the operation be postponed for a few days only, the utmost difficulty occurs in its accomplishment.

Mr. Forster, son of the surgeon of Guy's Hospital, informed me that in a fatal case of fracture of the thigh-bone, which he had an opportunity of dissecting before its union, the ends of the bones overlapped, and the muscles had acquired a contraction so rigid, that he could not, even in the dead body, bring the bones to their natural position, after employing all the force he was capable of exerting. It is this state of muscles in dislocations which gives rise to the difficulty in their reduction, and which, even in the dead body, is still capable of presenting a very considerable resistance.

That the muscles are the chief opponents to reduction, is strongly evinced by those cases in which the dislocation is accompanied by injury to any vital organ, and in which the power of muscular action is consequently diminished; for it is then found that a very slight force is sufficient to return the bone to its situation. Thus, in the case already mentioned, of the man who had an injury to his jejunum, and a dislocation of his hip, the bone was reduced with little difficulty.

When a dislocation has long existed, difficulties arise from three other circumstances. The extremity of the bone con-

tracts adhesion to the surrounding parts, so that even when in dissection the muscles are removed, the bone cannot be reduced. In this state I found the head of a radius, which had been long dislocated upon the external condyle of the os humeri, and which is preserved in the collection at St. Thomas's Hospital; and in a similar state I have seen the os humeri when dislocated. The socket is also sometimes so filled with adhesive matter, that if the bone were reduced, it could not remain in its original situation, and the original articular cavity is in part filled with ossific matter, so as to

render it incapable of receiving the head of the bone. Lastly: a new bony socket is sometimes formed, in which the head of the bone is so completely confined, that nothing but its fracture will allow it to escape from its new situation. This was exemplified by a figure in a preceding page (6).

The means to be employed for the reduction of dislocations are both constitutional and mechanical; force alone is in general objectionable, since it would be required in so great a degree as to occasion violence and injury; and it will in the sequel be shown, that the most powerful mechanical means often fail when unaided by constitutional remedies. The action and direction of the larger muscles are, in the first instance, to be duly appreciated, as these form the principal causes of resistance; and every surgeon ought to be fully acquainted with the precise action of each muscle, in order that he may apply his extending force to the best advantage.

Constitutional Remedies.—The constitutional means to be employed for the purpose of reduction, are those which produce a tendency to syncope, and this necessary state may be induced by one or other of the following means: viz. *bleeding*, *warm-bath*, and *nausea*. Of these remedies, I consider bleeding the most powerful; and, that the effect may be produced as quickly as possible, the blood should be drawn from a large orifice, and the

patient be kept in the erect position; for by this mode of depletion, syncope is produced before too large a quantity of blood is lost. However, the activity of this practice must be regulated by the constitution of the patient; if he be young, athletic, and muscular, the quantity removed should be considerable; but if the constitution be weak and irritable, a great loss of blood might induce a fatal debility; instances of which will be found in some of the cases which I shall hereafter relate.

In those cases in which the warm-bath may be thought preferable, or where it may be considered improper to continue the bleeding, the bath should be employed at the temperature of 100° to 110°; and, as the object is the same as in bleeding, the person should be kept in the bath at the same heat till the fainting effect is produced, when he should be immediately placed in a chair, wrapped in a blanket, and the mechanical means be employed which I shall presently particularly describe.

The third mode of lowering the action of the muscles consists in exhibiting small and repeated doses of nauseating medicines, of which tartarized antimony is the most convenient. It should be given in half grain doses, dissolved in a wine-glassful of water, every ten minutes, but should not be given to the extent of producing vomiting. It may be necessary to give one, two, or even five or six grains in this way; but at last it generally produces a complete state of faintness and languor and entirely overcomes the tone of the muscles. By these three measures united, dislocations may be reduced with much less effort, and at a much more distant period from the accident than in any other way.

The two cases related in the following pages, one from Mr. Norwood, surgeon at Hertford, and the other from Mr. Thomas, apothecary to St. Luke's Hospital (Cases XXII. and XXIII.), will illustrate the efficacy of the treatment recommended. By the combination of bleeding, the warm-bath, and nauseating doses of tartarized antimony, these dislocations were reduced at a more distant period from the accident than I had ever before known in any other example. One of these cases occurred at Guy's, and the other at St. Thomas's Hospital, at the time when these gentlemen were officiating as dressers.

The effect of opium I have never tried, but it would probably

be useful in a large dose in the case of a nervous, irritable, or debilitated patient.

Sometimes the tartar emetic produces little or no effect on persons of a powerful frame, even though given in considerable quantities. Seven and even ten grains have been given without effect. In some such cases it may be expedient to give the patient a pipe of tobacco to smoke, or a little of it to chew; and if he is not habituated to the use of this pernicious poison, it will soon produce the desired relaxation; but this must be done with caution.

Mr. Wilkinson, of Portsmouth, informed Mr. Bransby Cooper that he had employed the tincture of digitalis in the dose of a drachm for the same purpose. I should not myself, however, feel inclined to employ this hazardous remedy in preference to those which I have already mentioned.

Before quitting this part of the subject, I may observe that a surgeon who sees a patient immediately after a dislocation has occurred, may often effect reduction with perfect ease if he sets about it before the patient has recovered from the faintness and shock of the accident.

Mechanical Means.—When the resistance of the muscles has been properly diminished, the surgeon should proceed without delay to apply his mechanical means. These consist of an *extending* apparatus for the purpose of drawing the head of the bone into its socket, and of a *counter-extending* apparatus in order to fix the articular cavity from which the bone was dislocated.

It is now generally agreed among the most eminent surgeons, that force should be only gradually applied; for sudden violence is as likely to tear sound parts as to reduce those which are dislocated; and it is apt to excite all the powers of resistance in opposition to the efforts of the surgeon. Hence it becomes necessary to produce gradually that state of fatigue and relaxation which is sure to follow continued extension, and not to attempt to overpower the action of the muscles by sudden force.

One great cause of failure in the attempt to reduce dislocations arises from insufficient attention to the fixing of that bone in which the socket is placed. For example, in attempting to

reduce a dislocation of the shoulder, if the scapula be not fixed, or if one person pull at the scapula and two at the arm, the scapula will be necessarily drawn with the os humeri, and the extension will be very imperfectly made; the one bone, therefore, must be firmly fixed, or drawn in the opposite direction, while the other is extended with an equal force.

The force required may be applied either by the exertion of assistants, or by a compound pulley; but as the object is to extend the muscles by gradual, regular, and continued efforts, in cases of difficulty recourse should always be had to the pulley. Its effect may be gentle, continued, and directed by the surgeon's mind; but when assistants are employed, their exertions are sudden, violent, and often ill directed; and the force is more likely to produce laceration of parts than to restore the bone to its situation. Their efforts are also frequently uncombined, and their muscles as necessarily become fatigued as those of the patient, whose resistance they are employed to subdue.

In dislocation of the hip-joint, pulleys should always be employed; and also in those dislocations of the shoulder which have long remained unreduced. I do not mean to doubt the possibility of reducing dislocations of the hip by the aid of men only, but to point out the inferiority of this mode to the mechanical means. The employment of pulleys in dislocations is not a modern practice. Ambrose Paré (who died in 1590) frequently had recourse to them, and good practical surgeons have used them since his time: most writers on surgery have also mentioned their use, but they have not duly appreciated them. Mr. Cline, whose professional judgment every one must acknowledge, always strongly recommended them.

During the attempt to reduce luxations, the surgeon should endeavour to obtain a relaxation of the stronger opposing muscles. The limb should therefore be kept in a position between flexion and extension, as nearly as that medium can be obtained. Who has not seen, in the attempt to reduce a compound fracture in the extended position of a limb, the bone, which could not be brought into apposition under the most violent efforts, quickly replaced by an intelligent surgeon, who has directed the limb to be bent, and the muscles to be placed in a comparative state of relaxation?

A difference of opinion prevails, whether it is best to apply the extension on the dislocated bone, or on the limb below. M. Boyer, an eminent French surgeon, preferred the latter mode. But as far as I have had an opportunity of observing, it is generally best to apply the extension to the bone which is dislocated. There are, however, exceptions to this rule in the dislocation of the shoulder, which I generally reduce by placing the heel in the axilla, and by drawing the arm at the wrist in a line with the side of the body.

In the reduction of dislocations, great advantage is derived from attending to the patient's mind; for the muscles opposing the efforts of the surgeon may be made to desist from that action by directing the mind to other muscles. Several years since, a surgeon in Blackfriars' Road, asked me to see a patient with a dislocated shoulder, which had resisted the various attempts he had made at reduction. I found the patient in bed, with his right arm dislocated. Sitting down on the bed by his side, I placed my heel in the axilla, and made extension from the wrist; the dislocated bone remained unmoved. I said, "Rise from your bed, sir:" he made an effort to do so, whilst I continued my extension, and the bone snapped into its socket. For a similar reason a slight effort, when the muscles are unprepared, will accomplish the reduction of dislocation after violent measures have failed.

The reduction of the limb is ascertained by the restoration of its natural form, by the recovery of its original motion, and by a snap or sudden sound, which is heard when the bone returns into its cavity; but the snap is not often heard when the muscles have been much relaxed.

After a bone has been reduced by the protracted use of the pulleys, it will not remain in its situation without the aid of bandages to support it, until the recovery of muscular action. In the hip, however, dislocations rarely occur a second time; but the shoulder and the lower jaw very frequently slip again from their sockets, owing to the little depth of the cavity into which the head of the bone is received; and therefore they require bandages for a considerable period.

Rest is necessary for some time after the reduction of the limb, in order to permit union of the ruptured ligament, which would be prevented by exercise. The strength of the muscles

and ligaments may also be greatly promoted by affusion of cold water upon the limb, and by subsequent friction.

I believe that much mischief is produced by attempts to reduce dislocations of long duration in very muscular persons. I have seen great contusion of the integuments, laceration and bruises of muscles, and tension of nerves, inducing an insensibility and paralysis of the hand, occasioned by an abortive attempt to reduce a dislocation of the shoulder; so that in such cases, even when the bone has been replaced, it has often proved rather an evil than a benefit from the violence of the extension.

I have also heard of cases occurring in the practice of others, in which the whole side of the trunk became paralysed from injury to the cervical vertebræ during a violent extension; and of more than one instance in which the axillary artery was ruptured; and some of these cases were fatal. And there are plenty of cases on record of fatal abscesses from violent attempts at the reduction of dislocated hips. Mr. Skey has mentioned a fatal case of phlebitis following protracted extension of a dislocated hip, during which one hundred and twenty ounces of blood were taken from the patient.*

In those instances in which the bone remains in the axilla, in dislocations of the shoulder, a serviceable limb, and very extensive motions of it, may be regained, although reduction has not been effected. Captain S——, who had dislocated his shoulder four years before, called to show me how much motion he had recovered, although the arm still remained unreduced.

I am of opinion that three months after the accident for the shoulder, and eight weeks for the hip, may be fixed as the period at which it would be imprudent to make the attempt at reduction, except in persons of extremely relaxed fibre, or of advanced age. At the same time I am fully aware that dislocations have been reduced at a more distant period than that which I have mentioned; but in many instances the reduction has been attended with the evil results which I have just been deprecating.†

* Lancet, 1840-41, vol. i. p. 767.

† I would respectfully submit to the author whether there be not a better criterion by which to judge of the propriety of the attempt at reduction of a dislocated limb than the mere length of time since the accident had occurred. Should not the principal consideration be the precise condition of the new joint, especially as to the degree of motion of which it is capable, for by this a fair

In cases of unreduced dislocation, the best course the surgeon can adopt, after the inflammation which the injury necessarily produces has subsided, is to advise friction of the injured parts, and free motion of the limb in every direction of which it is naturally capable; the former to promote absorption and remove the swelling and the adhesions which the accident had occasioned; while the latter tends to produce a new cavity for the head of the bone, to assist in the formation of a new capsular ligament, and to restore the action to the muscles, which they would otherwise lose by repose.

There is, however, one other expedient that has recently been resorted to by the eminent surgeon and myotomist of Berlin, Herr Dieffenbach, as the following case will exemplify.

Case XVII.—A man of rigid muscular habit had dislocated his shoulder two years previously, and it had never been reduced. The head of the humerus lay in front of the chest, close to the clavicle, and two inches from the sternum. In drawing the arm outwards, the pectoralis major, latissimus dorsi, and teres major and minor muscles became tense. An attempt to reduce such a dislocation without dividing these muscles and the new joint would have been extremely dangerous, even if by chance successful; but, says the Professor, "I expected success from the subcutaneous section of everything that resisted me. The patient being placed on a table with one folded sheet passed under the right axilla, and held by six assistants; another fast-

judgment may be formed as to what extent nature has altered the surfaces of the bones in contact to fit them for the functions of a joint in their new situation. If any useful motion can be performed, then I believe it may be considered as ill judged to attempt to restore the dislocated bone to its former articulating cavity, for it seems invariably to happen that as a new joint becomes fitted for use, so the structures of the old one are rendered incompetent to restoration. Nor do these changes depend so much upon time as upon the attempts which have been made to use the supplementary articulation; for if an unreduced dislocation be maintained in a perfect state of rest, the changes which take place are very slow, and in such cases months may elapse, and yet it may be quite proper to attempt reduction; while, on the other hand, if continued efforts have been made to employ the limb, and a useful motion acquired, more permanent injury is likely to be sustained by the restoration of the bone to its original situation than if it be allowed to remain, and means employed to perfect the adaptation of the recently formed structures. Some observations on this subject will be found in the Guy's Hosp. Rep. vol. i. p. 99.—Ed.

ened round the hand, and held by six more; and a third round the upper part of the humerus, and held by three more: the two first sets of assistants were ordered to pull against each other. I bade them make a slowly-increased extension, and then stop. I then passed a small scythe-shaped knife through the skin, and divided the most tense portion of the pectoralis major close to its tendon, which yielded with a crackling sound. I then again introduced the knife at the posterior border of the axilla, and divided one after the other the latissimus dorsi and teres major and minor muscles. All these muscles gave way with a crackling sound, which was increased by the resonance of the chest. I next passed the knife into three places by the head of the humerus, and divided in a similar way, under the skin, the dense and hard false ligaments which surrounded the new joint; and, lessening the extension, I loosened the head of the bone by a few rotations. A powerful extension was now again commenced on both sides, and the three assistants behind the patient pulled suddenly, whilst I conducted the humerus towards the joint, into which it suddenly slipped without again springing out. The shoulder now looked like the other." A starched bandage was applied; the wounds bled only a few drops; no unpleasant symptom ensued; the bandage was removed on the ninth day, and at the date of the report the limb was quite restored.*

Treatment of Compound Dislocation. — A compound dislocation implies a wound of the soft parts communicating with the interior of the joint, through which the articulating surface of the dislocated bone may or may not have protruded. The objects to be attained in such a case are, first, to arrest bleeding if any vessel of importance has been ruptured, to wash away every extraneous substance from the surface of the wound or the bone if protruding, and then to restore the bone as quickly as possible to its natural situation, and immediately to close the wound with a piece of lint dipped in blood. The limb is then to be placed upon a pillow in the easiest and most relaxed position, and every attempt to be made as quickly as possible to render the dislocation a simple one, by promoting adhesion of the wound. When the opening through the skin is so small as to render it difficult to return the bone to its natural situation, the wound should be enlarged in the direction of the long axis

* Lancet, May 9th, 1840.

of the displaced bone, unless the situation of some large blood-vessel renders it necessary to deviate from that direction. When the bone is fractured as well as dislocated, and comminuted portions are detached, they should be carefully picked out; or if a sharp spicula should project, it should be sawn off smoothly. In every attempt to reduce the dislocated bone, the limb should be first placed in such a position as to relax those muscles and untorn ligaments which would contend against the force necessary to its reduction. These objects having been attained, lint dipped in blood is to be applied to the wound as already recommended, and if there be any tendency to severe inflammation, as would be indicated by redness and pain, evaporating lotions should be kept constantly applied, and be continued, if necessary, until the wound is healed. When spasms of the muscles occur, preventing the patient from maintaining the proper position of his limb, a many-tailed bandage should be applied, to afford a general support rather than pressure to the muscles; and the limb thus adjusted may be placed upon some simple kind of splint, so as to maintain it securely, free from undue pressure, and capable of admitting the ready inspection of the surgeon. This support offers the best means of subduing these involuntary contractions. In this state the limb should be allowed to remain undisturbed for several days, the surgeon taking care, however, to ascertain that there has been no change of position, which, however produced, interrupts the adhesive process in the wound, and induces a tendency to suppuration. Of all practices I most deprecate the application of poultices and fomentations in the treatment of compound fractures, as they encourage general secretion, lead to the suppurative process, and prevent the early healing of the wound, the object of all others desirable to be obtained. Exfoliation of bone, notwithstanding every precaution, may, however, retard the cure; and when it does occur, the removal of the dead portions of bone should be accelerated, either with forceps, or by the application of dilute nitric acid, which stimulates the living bone, and facilitates the separation of the dead. When abscesses form they should be opened as soon as fluctuation can be discovered, so as to prevent their extension, as well as the constitutional irritation which frequently follows the formation of matter, often to a degree that produces delirium and the most urgent symptoms.

The constitutional treatment in compound dislocation is, under common circumstances, of the most simple kind; but at other times the most discriminating judgment may be required to combat all the difficulties that may arise. When the irritative fever is excessive, great care is required as to the extent that depletion can be safely adopted; and general blood-letting must indeed be very sparingly had recourse to, for the abstraction of blood too frequently leads to an increase of irritability, with a diminution of constitutional power. Calomel, opium, and antimony are the best remedies under such circumstances, as they restore secretion, and at the same time assuage irritation. Should these means, however, prove inefficient, cautious bleeding may sometimes be advisable in robust patients, and in the country more frequently than in large towns. When purgative medicines are required, such should be administered as tend least to keep up a continued action upon the bowels, as their frequent operation produces great disturbance of the injured limb. Enemata may therefore be judiciously employed, unless there be a reason for prescribing some peculiar medicine for a specific purpose. The room in which the patient is placed ought to be capable of being easily ventilated, and his covering should be light; his diet of a nutritious but not of a stimulating quality, unless a necessity for stimulants is indicated, as may occur when suppuration is extensive. The surface of the patient's body should be frequently sponged with tepid water, as ablutions are not only useful for the sake of cleanliness, but also as they promote the natural functions of the skin. By such constitutional and local treatment I can confidently state that both the limbs and lives of patients may be preserved under very severe accidents. I feel not a little proud to assert that when I first became surgeon to Guy's Hospital in 1800, it was the general practice to amputate limbs in cases of compound dislocations, and I was much censured at that time for recommending the attempt to save them. I have, however, ever since persisted in the practice I then recommended, and have lived to witness its general adoption by every surgeon of eminence throughout the country, followed, too, by a success which has now permanently stamped the soundness of the principles upon which the doctrine was established. Cases do, however, occur in which it may be very improper to risk the life of the patient by the attempt to save the limb. Extensive

laceration of the soft parts, rupture of blood vessels and nerves, comminution of bone, and, added to these untoward circumstances, the age and peculiar constitution of the patient, may render amputation necessary. It now and then happens in these very severe cases that the surgeon's mind is so abstractedly directed to the obvious accident, that he overlooks some concomitant injury of great importance, which may afterwards lead, from being undetected, to fatal consequences; such, for instance, as a blow upon the head, or fracture of the pelvis, which, producing no immediate symptoms, may, without strict investigation, only be detected when their effects are past remedy. I need not remark, then, on the necessity of such examinations being invariably made in every case of severe local injury.

CHAPTER II.

ON DISLOCATIONS OF THE HIP-JOINT.

SECTION I.—ANATOMY OF THE JOINT.

THE hip-joint is formed by the reception of the head of the thigh-bone into the acetabulum of the os innominatum; but the acetabulum in the recent subject is a very different kind of cavity from what it appears in the skeleton, for it is much deepened by a ridge of fibro-cartilage (the cotyloid ligament) which surrounds its brim, and which fills up the notch on the inner side of it. Moreover, it closely embraces the head of the bone, the smooth surface of which being everywhere in close contact with that of the acetabulum, is retained in the cavity by a considerable amount of atmospheric pressure; so that when all the ligaments are completely severed, it still requires some little force to dislodge it.

LIGAMENTS. — The principal ligaments of this joint are the capsular, and the ligamentum teres, besides the fibro-cartilaginous rim or cotyloid ligament of which we have just spoken.

The capsular ligament arises from the whole circumference of the acetabulum, and, passing outwards, is inserted into the neck of the femur. In front it is inserted into that line which extends from the greater to the lesser trochanter; poste-

riorly, it does not extend so far outwards, but is inserted into the neck of the bone about midway between its head and the trochanter major; at its insertion it is incorporated with the periosteum. It is thickest and strongest at its upper and anterior part, where it is further strengthened by the *accessory* or *ilio femoral* ligament, which passes across the front of the joint from the anterior inferior spinous process of the ilium to near the lesser trochanter. But in its inferior part its fibres are weaker, and often so much separated as to allow of the passage of blood vessels between them.

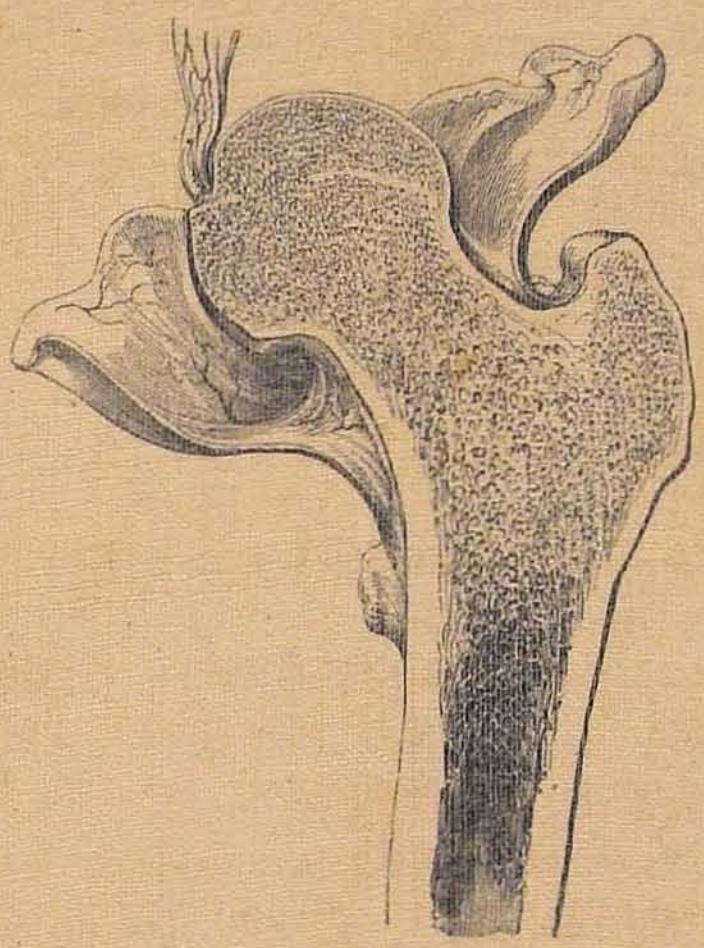

The ligamentum teres, or interarticular ligament, is somewhat triangular in figure, and is attached by its apex to a depression on the head of the femur, and by its base to the notch of the acetabulum. Its base is bifurcated, and divided into two flattened bands, which are continuous with the fibrous part of the cotyloid ligament.

The cotyloid ligament, as we have already said, completely surrounds the edge of the acetabulum, and passes over the notch on its inner side, so as to convert it into a foramen, through which pass the vessels that supply the synovial membrane. It is prismatic in shape, being attached by a broad base to the edge of the acetabulum, while its apex is a free border, a little inclined inwards, so as to embrace the head of the bone closely. It is invested on both surfaces with synovial membrane.

Of the synovial membrane we need only say that it covers the head and neck of the femur and the ligamentum teres, and that at its reflection from the inside of the capsular ligament to the neck of the femur it is curiously folded. There are under it at this part certain small granular bodies of a fatty appearance, and that depression in the acetabulum near the insertion of the

ligamentum teres, which is not covered with cartilage, is filled with a similar fatty matter, which is supposed by some people to be composed of synovial glands or follicles.

VARIETIES OF DISLOCATION.—The thigh-bone I have seen dislocated in four directions:—First, upwards, or upon the dorsum of the ilium; secondly, downwards, or into the foramen ovale; thirdly, backwards and upwards, or into the ischiatic notch; and, fourthly, forwards and upwards, or upon the body of the pubes. Besides these four, two other anomalous dislocations have been described, of which we shall speak in the proper place.

SECTION II.

DISLOCATION UPWARDS, OR ON THE DORSUM ILII.

This dislocation is the most frequent of those which happen to the hip-joint: and the following are the signs of its existence.



SYMPTOMS.—The dislocated limb is from one inch and a half to two inches and a half shorter than the other, as will be seen by supporting the patient in the erect position and comparing the inner ankles. The toe rests upon the tarsus of the other foot; the knee and foot are turned inwards, and the knee is a little advanced upon the other. When an attempt is made to separate the leg from the other, it cannot be accomplished, for the limb is firmly fixed in its new situation, so far as regards its motion outwards, although the thigh can be slightly bent across the other. If the

bone be not concealed by extravasation of blood, the head of it can be perceived moving upon the dorsum ilii during rotation of the knee inwards; and the trochanter major may be felt much nearer than natural to the anterior and superior spinous process of the ilium, and is less prominent than on the opposite side; upon a comparison also of the two hips, the roundness of the dislocated side will be found to have disappeared. A surgeon then called to a severe and recent injury of the hip-joint recognises a dislocation on the dorsum ilii when the motion of the joint is diminished, when the limb is rotated inwards, and its length decreased nearly two inches; when the natural projection of the trochanter is lost, and when there is a diminution of roundness in the injured hip.

Diagnosis.—The accident with which this dislocation is liable to be confounded is the fracture of the neck of the thigh-bone within the capsular ligament. Yet the marks of distinction are, in general, sufficiently strong to be unequivocal to a person commonly attentive. In fracture of the neck of the thigh-bone, the knee and foot are generally turned outwards; the trochanter is drawn upwards and backwards, resting upon the dorsum ilii; the thigh can be readily bent towards the abdomen, although with some pain; but above all, the limb, which is shortened according to the duration of the accident, from one to two inches, by the contraction of the muscles, can be made the length of the other by a slight extension: and when the extension is abandoned, the leg is again shortened. If the limb when drawn down be rotated, a crepitus can often be felt, which ceases to be perceived when rotation is performed under a shortened state of the limb. Fracture of the neck of the thigh-bone, within the capsular ligament, rarely occurs but in advanced age; and the most trifling accident is sufficient to produce it, in consequence of the interstitial absorption which this part of the bone undergoes at advanced periods of life. Fractures externally to the capsular ligament, occur at any age, and they are easily distinguished by the crepitus which attends them, if the limb be rotated and the trochanter compressed with the hand. The position is the same as in fractures within the ligament. Fractures of the neck of the thigh-bone are very frequent accidents when compared with dislocations.*

* In fact, shortening is the only symptom common to them both.—*Ed.*

The effects of diseases of the hip-joint can scarcely ever be confounded with dislocations from violence, but by those who are ignorant of anatomy, and who are very superficial observers. The gradual progress of the symptoms, the pain in the knee, with the apparent elongation at first, and real shortening of the limb afterwards, and the capacity for motion, although with great pain, are diagnostic symptoms which would strike the most careless observer. The consequences of a disease of this kind, when it has existed for a great length of time, are, ulceration of the ligaments, acetabulum, and head of the bone, which allows of such a change of situation of parts, as sometimes to give the limb the position of dislocation; but the history of the case at once explains to the medical attendant the nature of the disease.

CAUSE.—This dislocation may be caused by a fall when the knee and the foot of the patient are turned inwards, or by a blow whilst the limb is in that position; but it most commonly occurs in consequence of the person falling whilst carrying a heavy weight on his shoulders; or from a heavy weight, such as a mass of earth, falling on the back whilst the body is bent forwards in a stooping posture.

TREATMENT.—In the reduction of this dislocation, the following plan is to be adopted:—let the patient lose from twelve to twenty ounces of blood, or even more if he be a very strong man; then place him in a warm-bath, at the heat of 100°, and gradually increase it to 110°, and give him half a grain of tartarized antimony every ten minutes, until he feels some nausea. The patient should now be wrapped up in a blanket and be placed on his back upon a table of convenient height between two staples; a strong padded leathern girth should be passed round the hip, with an opening in it sufficiently large to admit the injured extremity and to press upon the perinæum on one side, and the crista of the ilium at its other point of bearing, the extremities of this girth being firmly fixed to one of the staples so that they form a line continuous posteriorly with the direction of the dislocated thigh. This part of the apparatus is for the purpose of firmly fixing the pelvis, and forms what is termed the counter-extending force. A wetted linen roller is next to be tightly applied just above the knee, and upon this a leathern strap is to be buckled, having two short straps with rings at right angles with the circular part; or instead of this, a round

towel made into the knot called the clove hitch. The knee is to be slightly bent, but not quite at a right angle, and to be brought across the other thigh a little above the knee, which position not only places the extremity in the best direction for the extension, but also prevents the apparatus from slipping. The pulleys are now to be fixed to the two rings of the circular girth (or to

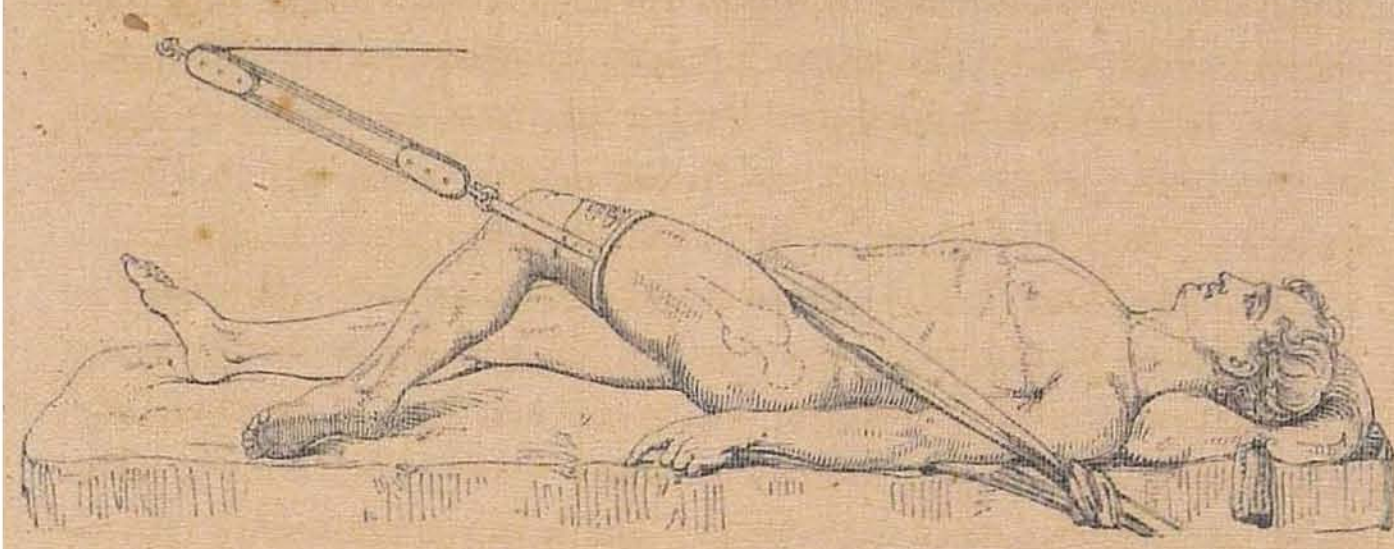

the towel), and to the opposite staple, thus completing the arrangement of the extending force. The surgeon should now draw upon the cord of the pulleys so as to tighten the whole apparatus, the patient having been so placed that the direction of the extending and counter-extending forces together form a straight line in the direction of the long axis of the dislocated limb. The extension should be continued by drawing upon the pulleys so as to tighten even to stretching every part of the apparatus, and should the patient now complain of the severity of the pain the surgeon should wait a little to give the muscles time to become fatigued; he then renews the extension, and when the patient suffers much, again rests, until by degrees the muscles yield and the bone approaches the acetabulum. When it reaches the lip of that cavity he gives the pulleys to an assistant and desires him to preserve the same state of extension, while the surgeon rotates the limb gently inwards, but not with a violence to excite opposition in the muscles, during which act the bone usually slips into its place.

When the pulleys are employed, the head of the femur does not usually return with a snap into its socket, in consequence of the continued extension to which the muscles have been submitted having overcome their contractile power. The surgeon has no other means therefore of ascertaining whether or not the

reduction has been effected, than by loosening the bandages and comparing the length of the two limbs, unless he be able to ascertain it from measuring the distance of the trochanter major from the anterior and superior spinous process of the ilium and sacro-coccygeal articulation. If it be ascertained that these distances are the same on both sides, it may be inferred that the dislocation is reduced. Such precaution should always be taken before the apparatus is removed; for nothing can exceed the distress which is invariably expressed if the patient be obliged to submit to its second adjustment.

It often happens that the bandages get loose before the extension is completed, an accident which should be carefully prevented by having them well secured at first; but if they require to be renewed, it should be expeditiously performed to prevent the muscles having time to recover their tone.

A considerable difficulty sometimes occurs in raising the bone over the edge of the acetabulum, to overcome which a towel should be passed under the thigh as near the joint as possible to enable an assistant to lift it. When the reduction is completed, the injured limb should be kept parallel with the sound one by the aid of a bandage; for, in consequence of the relaxed state of the muscles, there is great liability to the recurrence of its displacement unless such precaution be adopted. It is also necessary as after treatment, when much force has been employed, to administer both constitutional and local means to subdue the subsequent inflammation. The patient, under all circumstances, should be kept in bed for at least a fortnight after the accident to allow of the reparation of the injured structures of the joint; and even then, before he be allowed to use the limb, passive motion should be employed.

I may here observe, and I trust without ostentation, that the methods which I have recommended are the result of considerable experience; that they have been successful in a great number of cases; and that they have very rarely failed under the most disadvantageous circumstances. They may require a little variation, from some slight difference in the position; but this will only be an exception to a general rule, and will very rarely occur.

The following cases will serve as illustrations of the history and treatment of dislocations on the dorsum ilii. The first of

them points out, in a striking manner, the evils that ensue when dislocation of the hip-joint remains unreduced, and the advantages arising from the use of pulleys in effecting its reduction. It shows also that such dislocation may happen in a strong healthy man, even after he has attained the age of sixty.

Case XVIII.—James Ivory, aged sixty-two, of Pottersend, Herts, on the 7th of February, 1810, was working in a clay-pit, twenty-five feet below the surface of the earth, when a large quantity of clay fell in upon him, while he was in the act of stooping with his left knee bent rather behind the other; and he was, in this postion, buried under the earth. Being soon removed from this perilous situation and carried home, a surgeon was sent for, who, discovering the accident to be a dislocation, directly employed some men to extend the limb, whilst he attempted to push the head of the bone into the acetabulum; but all his efforts were unavailing, as, unfortunately for the patient, pulleys were not employed. The appearance of the limb, after nine years have elapsed since the accident, are these: — the limb is three inches and a half shorter than the other, and he is obliged to wear a shoe with an additional sole of three inches on that side, which lessens, though it does not prevent his halt in walking. When he stands, the foot of the injured limb rests upon the other; the toes are turned inwards; and the knee, which is advanced upon the other, is also inverted, and rests upon the side of the patella, and upon the vastus internus muscle of the sound limb; it is also bent, and cannot be completely extended. The thigh, from the unemployed state of several of the muscles, is very much wasted; but the semitendinosus, semi-membranosus, and biceps, in consequence of the shortened state of the limb, form a considerable rounded projection on the back part of the thigh. The trochanter major is seven-eighths of an inch nearer to the spine of the ilium than natural; and on viewing him behind, it appears to project much farther than on the other side, from the wasting of the muscles; the situation of the head of the bone on the dorsum ilii is easily perceived; and when the limb is rotated inwards, it is still more obvious. The spinous processes of the ilia are of an equal height. In the sitting posture, the foot is turned very much inwards, and the knee is placed behind the other, whilst the toe only reaches the ground. If fatigued, he experiences pain in

the opposite hip, and in the thigh of the injured limb. This unfortunate man finds it an arduous task to gain his bread by his labour, as he cannot stoop but with the greatest difficulty; for when he attempts to take anything from the ground, he bends the knee of the injured limb at right angles with the thigh, and throws it far back. He can now stand for a few seconds upon the dislocated limb, but it was twelve months before he could endure that posture. When in bed, he finds it painful to lie on the injured side. His hip, without any apparent cause, is much weaker at some times than at others. When sitting down to evacuate his fæces, he is obliged to support himself by resting the injured knee against the tendo Achillis of the other leg, placing his right hand on the ground. He now walks with two sticks: at first he employed crutches, and these he used for twelve months, after which he was enabled to trust to one crutch and a stick, until his limb acquired greater strength. In getting over a stile, he raises the injured limb two steps, and then turns over the sound limb; but this he cannot accomplish when the steps are far apart; and he is frequently obliged either to turn back, or to take a circuitous route. When lying with his face downwards, the dislocated hip projects very much. He sometimes falls in walking, and would very frequently fall, but that he takes extreme care, as the least check to his motion throws him down. The knee is bent, and the shortening of the limb partly originates in that circumstance.

The following cases illustrate the method of reduction detailed in the preceding pages, and show in strong colours the advantages to be derived from constitutional treatment, and the use of pulleys.

Case XIX.—John Forster, aged twenty-two years, was admitted into the Chester Infirmary July 10, 1818, with a dislocation of the thigh on the dorsum ilii, occasioned by a cart passing over the pelvis. Upon examination, Mr. Bennett found the leg shorter than the other, and the knee and foot turned inwards. The patient being firmly confined upon a table, I extended the limb by pulleys for fifty minutes without success, and he was returned to bed for three hours; after which he was put in the warm bath for twenty minutes, and the extension was repeated for fifteen minutes unsuccessfully; I therefore took twenty-four ounces of blood from him, and gave him forty drops of tinct.

opii. Continuing the extension, but not succeeding in producing faintness, I gave small doses of a solution of tartrate of antimony, which in a quarter of an hour produced nausea: in ten minutes afterwards I succeeded in reducing the limb, and in less than a fortnight he left the Infirmary quite well.*

The next case was sent me by Mr. Nott, of Collumpton, Devon.

Case XX.—John Lee, aged thirty-three, of a strong and robust constitution, in passing over a foot bridge, October 9th, 1819, fell from a height of about four feet on a large stone, and dislocated his left hip. I did not see him until the fourth of December, when I found the limb full three inches shorter than the other, the knee turned in, the foot directed over the opposite tarsus, and the trochanter major brought nearer the spinous process of the ilium. On laying the man on his face, the head of the femur and trochanter could be distinctly seen on the dorsum ilii, so as to leave not the slightest doubt of the nature of the injury. With the assistance of a neighbouring practitioner, I immediately set about to reduce it. A girth was applied between the legs, and a bandage over the knee, to fix the pulleys, &c. in the usual manner. I then made the extension downwards and inwards, crossing the opposite thigh two-thirds downwards; and immediately when the extension was commenced, I gave him a solution of two grains of tartar emetic, which was repeated five times every ten minutes, but it produced very slight nausea. I shortly after bled him to sixty ounces without syncope; and after keeping up the extension gradually for about two hours, with all the force one man could employ with the pulleys, we found the limb as long as the opposite; we then endeavoured to lift the head of the bone over the acetabulum, by means of a towel under the thigh and over one of our heads, at the same time rotating the limb outwards with all the force we were able to exert: the foot at length became somewhat turned out, and the head of the bone was less distinctly felt, and in about half an hour we heard a grating of the head of the bone, when the man instantly exclaimed it was replaced;

* This case well illustrates the necessity of taking advantage of constitutional means as well as of mechanical before any attempts at reduction be made; for there can be no doubt but that the first attempt would have proved successful if the means had been adopted which were subsequently effectual.—*Ed.*

and, upon examination, finding the foot turned out, the limb of its natural length, and no appearance of the head of the bone on the dorsum ilii, we concluded it must be within the acetabulum, and desisted from any further violence, put the man to bed, and tied his legs together; his foot immediately became sensible, which it had not been before since the accident, and he altogether felt easier. A large blister was applied over the trochanter, and he slept well in the night, and complained only of pain in the perinæum and just above the knee, where the bandages had been applied; there was no subsequent fever, nor any unpleasant symptom whatever.

In a few days the man could bear slight flexion and extension without pain, and in a week some degree of rotation; the limb became gradually stronger, and the power of motion so increased, that on the twelfth day he could by himself bring the thigh at right angles with the body. He was now taken out of bed; bandages were applied round the thigh and pelvis; and he could stand perfectly upright, so as to walk with his heel on the ground with the assistance of crutches; and from exercise, he grew so rapidly stronger, that on the twenty-second day he left off one crutch, and on the twenty-fifth the other. In a month he was able to walk without a stick; and in five weeks, having particular business, he walked nearly twenty miles, perfectly upright and without the least limping.

I attended the following case, which forms a striking contrast to the preceding, and to some of those hereafter related.

Case XXI.—I was desired to visit a man aged twenty-eight years, who, by the overturning of a coach, had dislocated his left hip more than five weeks before; and who had been declared not to have a dislocation, although the case was extremely well marked. His leg was full two inches shorter than the other; his knee and foot were turned inwards; and the inner side of the foot rested upon the metatarsal bones of the other leg. The thigh was slightly bent towards the abdomen, and the knee was advanced over the other thigh. The head of the thigh-bone could be distinctly felt upon the dorsum of the ilium; and when the two hips were compared, the natural roundness of the dislocated side had disappeared. I used only mechanical means in my attempts at reduction; and although I employed the pulleys, and varied the direction of repeated extensions, I could not suc-

ceed in replacing the bone; and this person returned to the country with the dislocation unreduced.

The next case was communicated to me by Mr. Norwood, surgeon, Hertford.

Case XXII. — William Newman, a strong muscular man, nearly thirty years of age, was admitted into Guy's Hospital on Wednesday, December 4, 1812, for a dislocation of the hip-joint. In springing from the shafts of a waggon, on Thursday, November 7th, his foot slipped, and his hip was driven against the wheel with considerable force. He immediately fell, and being unable to walk, was carried to Kingston Workhouse, near the place where the accident happened. On the evening of that day he was examined by a medical man, but the nature of the accident was not ascertained. He remained at Kingston until the 30th of November, and was then removed to Guildford, his place of residence, and on the 4th of December to Guy's Hospital. On examination, the head of the thigh-bone was found resting on the dorsum ilii; the trochanter was thrown forward towards the anterior superior spinous process of the ilium: the knee and foot were turned inwards, and the limb was shortened one inch and a half; the great toe rested upon the metatarsal bone of the other foot, and there was but little motion in the limb.

On Saturday, the 7th of December, thirty days after the accident, an extension was made to reduce the limb; and previously to the application of the bandage, he was bled to twenty-four ounces from his arm; in about ten minutes after he was put into a warm bath, where he remained until he became faint, which happened in fifteen minutes; a grain of tartarized antimony was then given him, and repeated in sixteen minutes, as the first dose did not produce nausea. The most distressing nausea was now quickly produced, but he did not vomit; and while under the influence of this debilitating cause, he was carried into the operating theatre in a state of great exhaustion. Being placed on a table on his left side, the bandage was applied in the usual manner to fix the pelvis, and the pulleys were fastened to a strap around the knee: the thigh was drawn obliquely across the other, not quite two-thirds of its length downwards, and the extension was continued for ten minutes, when the bone slipped into the socket. The man was dis-

charged from the hospital in three weeks from the period of his admission, making rapid progress towards a recovery of the perfect use and strength of the limb.

For the history of the following case, I am obliged to Mr. Thomas, apothecary to St. Luke's Hospital.

CASE XXIII.—William Chapman, aged fifty years, was admitted into St. Thomas's Hospital on Thursday, September 10th, 1812, with a dislocation of the left hip upon the dorsum ilii, which was occasioned by the mast of a ship falling upon the part and throwing him down, *six weeks* prior to his admission into the hospital. It was reduced on Friday, the 11th of September, in the following manner:—The patient was bled by opening a vein in each arm, and thirty-four ounces of blood were taken away. He was then put into a warm bath, and a grain of tartarized antimony given to him, which was repeated every ten minutes: this, with the previous means, produced fainting and nausea. The patient was then placed on a table on his right side, and a girth was carried between his thighs and over his pelvis, so as completely to confine it; a wetted roller was applied above the knee, and upon it a leathern belt, with rings for the pulleys. The extension was then made in a direction causing the dislocated thigh to cross the other below its middle, and in half an hour the reduction was accomplished.

From the following cases it will be seen we are not to despair of success, even when a considerable time has elapsed after the accident.

CASE XXIV.—William Honey was admitted into the Winchester Hospital in August, 1812, under the care of Mr. Charles Mayo, with a dislocation on the dorsum ilii. The dislocation had taken place seven weeks before, and was reduced the day after his admission. He was discharged cured on the 18th of November.

The following instances prove, indeed, that the dislocation on the dorsum ilii may be reduced without pulleys; but they show at the same time how desirable that mechanical aid would have been, especially in the two first instances.

CASE XXV.—William Piper, aged twenty-five years, sustained an injury from the wheel of a cart, laden with hay, which passed between his legs, and over the upper part of his right thigh. Mr. Holt, surgeon at Tottenham, was sent for nearly a

month after the accident: he found him in great pain, attended with fever, and with much local inflammation and tension. He bled him largely, purged him freely, and applied leeches. The injured leg was shorter than the other, and the head of the bone was seated upon the dorsum ilii: the knee and foot were turned inwards.

As I visited Tottenham frequently at that time, Mr. Holt asked me to accompany him to see the man, and we agreed on the propriety of making a trial at reduction. Mr. Holt and myself, assisted by five strong men, exerted our best endeavours for that purpose. Repeatedly fatigued, we were several times obliged to pause and then renew our attempt. At length exhausted, we were about to abandon any further trial, but agreed to make one last effort; when at fifty-two minutes after the commencement of the attempt, the bone slipped into its socket.

Case XXVI.—In a case also, which I attended with Mr. Dyson, in Fore-street, I succeeded in reducing the limb without the use of pulleys; but the violence used was so great, and the extension so unequal (our fatigue being nearly as severe as the sufferings of the patient), that I am confident no person who had used pulleys in dislocation of the hip, would have recourse to any other mode, excepting in dislocation into the foramen ovale.

To Mr. Daniel, one of Mr. Lucas's dressers, I am obliged for the particulars of the following case of dislocation in a very young person.

Case XXVII.—Mary Bailey, aged seven years, was admitted into Guy's Hospital, June 16th, 1819, for a dislocation of the os femoris upwards on the dorsum ilii. This accident was occasioned by the child swinging on the shaft of a cart, which, being insecurely propped, suddenly gave way, and she fell to the ground upon her side. The nature of the accident was perfectly evident; the limb on the dislocated side was at least two inches shorter than the other; the toe rested on the tarsus of the opposite foot, and was turned inwards; the knee was also inverted and rested on the other. The child was admitted into the hospital at half-past five in the afternoon, the accident having happened rather more than half an hour before. Where so little resistance was expected the pulleys appeared unnecessary, and

towels were substituted, one being applied above the knee, and the other between the pudendum and thigh; then, the knee being bent, and the thigh brought across the other just above the knee, gradual extension was made, and in about four minutes the head of the bone suddenly snapt into its socket. On the seventh day the child was walking in her ward, and suffered little inconvenience.

In the following case, sent me by Mr. Oldknow of Nottingham, the extension was made at the ankle; it is consequently worthy of notice.

Case XXVIII.—William Sharpe, an athletic young man, in wrestling received a fall; his antagonist falling with and upon him, their legs were so entangled that he cannot say how he came to the ground. He complained of great pain in the hip, and was incapable of rising. About twenty minutes after the accident, I found him lying on his belly in the field where it had occurred, and the left limb in a trifling state of abduction, shortened, and the knee and foot turned inwards; the prominence of the trochanter gone, and the head of the bone obscurely felt on the dorsum ilii. He was conveyed home; and in order to reduce the dislocation,—for such I considered it,—I placed the man on his right side diagonally across a four-post bedstead. The centre of a large sheet rolled up, was passed in front and behind the body, and fastened to the upper bed-post as low as possible. The centre of a napkin, rolled in like manner, was then applied upon the dorsum ilii, between its crista and the dislocated bone, and each extremity being brought under the sheet, forwards and backwards, was reflected over it and tied in the centre, by which means I hoped to keep the pelvis secure. The counter-extending force was applied above the ankle (it appearing to me to interfere less with the muscles upon the thigh), first by rolling round a wetted towel, and then placing upon this the end of a long or jack-towel. Three men were now directed to pull gradually and steadily; and when I perceived that the head of the femur was brought down to the edge of the acetabulum, I raised it a little with my clasped hands placed under the upper part of the thigh, and immediately the head of the bone entered the cotyloid cavity with a smart snapping noise. The man had considerable pain about the hip and knee for some time, but is now quite well.

Mr. Badley had the kindness to send me the following particulars of two cases of dislocation of the femur complicated with fracture.

Case XXIX.—A youth, about sixteen or eighteen years of age, while at his work in a pit, was buried under a fall of coals; and besides being severely injured in several other parts of his body, had one hip dislocated on the dorsum of the ilium, and the same thigh broken about the middle of the bone. As the reduction of the hip was of course impracticable, the thigh was bound up in the usual manner, and treated without any reference to the dislocation of the joint, with a hope that when the thigh-bone was re-united, the hip might possibly be reduced. At the end of five weeks, the bone appearing tolerably firm, I had a very careful but unremitting extension of the limb made by means of pulleys, and in less than half an hour had the satisfaction of feeling the head of the bone re-enter the socket. It is very probable that the reduction would have been accomplished in less time had I dared to allow a more powerful extension of the limb, but I very much feared lest a separation of the newly-united bone should be produced by it. The patient became so upright as to show scarcely any signs of lameness afterwards.

I have met with several instances of these accidents conjoined with another injury, which at first sight presented a complication sufficiently embarrassing, but without being, in reality, productive of much additional difficulty. I allude to cases in which, with dislocation of one hip, there has been a fracture of the bone of the opposite thigh. In such circumstances I have fixed some splints temporarily, but very firmly, upon the broken limb, and then, turning the patient on that side, have proceeded to the reduction of the dislocated hip in the usual way. After this has been accomplished, I have taken the splints from the broken limb, and bound it up again in the customary manner; and every case which I have seen has done well, without any additional inconvenience.

Case XXX.—I once witnessed a case, which I mention rather for its singularity than for any practical inference which it furnishes.—A man had received, I forget how, a severe hurt on one of his hips. When laid on a bed for examination, the thigh-bone was found not to be broken, and the limbs were exactly of

the same length; but the foot of the injured side turned somewhat inwards, and any attempt to move the hip-joint was extremely painful. On a more careful examination of the parts about the hip, it was plain that the thigh-bone was dislocated, and that its head was on the dorsum of the ilium, and yet the limb seemed not at all shortened. A brief enquiry, however, led to an explanation of this apparent anomaly. It appeared that the opposite thigh-bone had been formerly broken, and had united in such a way as to leave the limb several inches shorter than it had originally been, and the dislocation of the other thigh upwards had now brought that to a corresponding length. It is scarcely needful to add that the reduction of the dislocation restored the patient to his former lameness, and to the deformity produced by limbs of unequal length.

Case XXXI.—Abraham Harman, aged thirteen years, a patient under Mr. Forster in Guy's Hospital, gave the following account of his accident:—About four months prior to this time he drove his master's horses to a chalk-pit; he went down into the pit to pack the chalk, and to break it into small pieces, and while he was thus occupied the side of the pit gave way, and a large piece of chalk striking him violently on the hip, knocked him down. Being immediately taken to a neighbouring public-house, a surgeon was sent for. The thigh was discovered to be fractured near its middle, but very considerable contusions prevented the dislocation from being at first discovered. Fomentation and other means of reducing the swelling at the hip having been employed, it was ascertained that the thigh was also dislocated, and some attempts were made to reduce it; but the fracture would not then bear the extension, and the boy was sent to the hospital. No attempt has since been made to reduce the bone.

This case certainly presented great difficulties, and the probability is that dislocation, complicated with fracture, will frequently not admit of reduction, as extension cannot be made until the bone has united so as to admit of the application of the necessary force, unless indeed the solution of continuity in the bone be so distant from the dislocated head that a sufficient share be left above the fracture for the adjustment of the apparatus, and then I am of opinion it would be better to reduce the dislocation immediately after the accident, carefully

enclosing the fractured extremities of the bone in splints and bandages.

The following case, which was communicated to me by Mr. T. Maurice, of Marlborough, illustrates one of the manners in which this dislocation may be produced.

Case XXXII.—George Davies, aged thirty-five, on the first of the present month, in descending a flight of steps at a mill in this neighbourhood, with a sack of wheat on his back, missed a step or two, and in endeavouring to regain his footing, the whole weight of the load fell upon him, and the violence of the shock bore him down several steps lower, where he lay totally incapable of further motion till assistance was procured. He was then conveyed to the adjoining village, and on examination he was found to have a dislocation of the hip.

The two following cases were communicated to Mr. Bransby Cooper by Mr. Elliot, surgeon to the Forces; and they show that an able surgeon may succeed, even with inferior means, if he has the right principles to guide him.

Case XXXIII.—In the year 1807, while stationed on duty with a detachment at the island of Capri in the Mediterranean, I was requested to see a lad, a native of the island, who, while employed in the construction of a field fortification, was suddenly half buried by the falling in of a quantity of earth: after he was extricated the thigh-bone was found dislocated upwards on the ilium. I ordered him home, and made preparations for its reduction, and not being supplied with pulleys I adopted the following plan to effect a permanent and continued extension. Being aware that soldiers implicitly obey whatever instructions are given them, I sent a corporal to select and bring from an adjoining barrack eight or ten of the most steady men he could pick out, whom I instructed how to make the extension, and to relieve each other without diminishing or increasing the same. Others were directed in the same manner to confine and fix the sheet which supported the pelvis. They were desired strictly to attend to my instructions. The patient was placed on a low bedstead, with boards at the bottom, in the middle of the room; a sheet was passed between the thighs, and the ends secured by men behind; the extension was then conducted in the usual manner, at the same time I stood upon the bed, and attempted to elevate somewhat the head of the bone, by means of a towel

carried under the upper part of the thigh. The extension and fixing of the pelvis was so well conducted by the soldiers, that within ten minutes the bone suddenly returned into its situation with a kind of snap. This lad was about sixteen years of age, and of rather lax fibre.

Case XXXIV.—The second case occurred in the year 1810, while I was stationed at Gibraltar as surgeon of the 82nd regiment. A soldier was brought into the regimental hospital with a dislocation of the thigh-bone upwards on the ilium. He was a grenadier, and one of the most muscular men in the regiment; he was much intoxicated, and very ungovernable. I took thirty ounces of blood from him, when he became more tranquil. Not having pulleys, I resorted to the same mode as in the former case, and having collected as many soldiers as were required for the reduction, I fixed the pelvis, and had the extension made, at the same time endeavouring to elevate the head of the bone by means of a towel passed under the upper part of the thigh-bone. To my surprise the extension had not been long continued, and as far as I can recollect about ten minutes, or a little more, when the head of the bone suddenly snapped into its situation.

Having assisted in reducing two or three dislocations of this nature when a dresser to Sir Astley Cooper in 1800 at Guy's Hospital, I had some confidence in the first case, as the patient was young, and of lax fibre; but I certainly did not anticipate such success in the latter case without the use of pulleys, as the man was of a strong robust make.

Case XXXV.—John Day, a strong and healthy Irish labourer, twenty-eight years of age, while walking along a plank with a basket of sand upon his head, fell several feet into an empty barge, when upon attempting to rise he found himself incapable of doing so, suffering considerable pain in the left thigh in the attempt. About four hours after the accident he was brought into Guy's Hospital, where I immediately saw him, and drew the attention of the pupils to the following diagnostic marks of dislocation of the femur upon the dorsum of the ilium. In the sitting posture the right knee was inclined inwards towards that on the opposite side, the thigh was flexed upon the pelvis, and the whole limb inverted. When standing, the trochanter major could be plainly felt behind, and a little above its

natural situation; the whole limb appeared much shortened, and upon measurement proved to be an inch and a half shorter than the other; the point of the great toe of the injured side rested upon the instep of the opposite foot; the thigh admitted of flexion to a great degree, but neither rotation, adduction, or abduction could be produced. From the degree of shortening of the limb, as well as from the perfect impossibility of producing rotation outwards, in consequence of the head of the femur striking upon the ilium, I was at once led to pronounce it a dislocation upon the dorsum, and not, as some believed, into the ischiatic notch. The following means were then employed for its reduction.

Twenty-six ounces of blood were drawn from a large orifice; he was then made to smoke a pipe (to which he had not been accustomed). These means brought on a state approaching to syncope, in which he was carried into the operating theatre; here he was placed upon the table on his back, between two posts, where the extending and counter-extending forces were fixed. The counter-extension was made by means of the padded girth, with the opening for the injured limb; this being passed between the thighs and over the crista of the ilium was fastened to a cord, which made, with the axis of the body, an angle of about thirty degrees. The extension was produced by means of pulleys, attached to a jack-towel, fastened round the thigh over a wetted bandage. Half a grain of tartarized antimony was given, and the dose repeated in about ten minutes. The cords were gradually tightened for a quarter of an hour, when, notwithstanding that the knee was flexed, the towel had a tendency to slip; I therefore requested, for the purpose of assisting by the application of a new force, that my dresser should stand upon the table, and by means of a cloth passed under the patient's thigh and over his own shoulders, attempt to raise the dislocated femur, while I directed the head of the bone into the acetabulum. While this attempt was making, the towel slipped completely over the knee, apparently rendering all our attempts abortive, and at the same time the necessity for the readjustment of the apparatus. Before, however, they were again applied, I took the opportunity of examining whether the limb had undergone any change from the extension which had been made, and was surprised to find, upon every investigation that I could make in

the recumbent posture, that the limb had regained its natural situation. I immediately directed the patient to stand up, upon which he at once expressed his conviction that the bone was replaced, as he had the power to bear weight upon the limb, which was now of an equal length with the other, and was capable of motion in every direction, losing therefore all the signs of dislocation. It was my opinion that the reduction had occurred upon the first application of the apparatus; for at that moment it was observed that the trochanter was influenced by the extending force. That noise should not indicate the coaptation of the bones, can hardly be a circumstance for surprise, when we consider that the muscles were so stretched by the mechanical means employed, as to destroy their natural contractile power, without which no collision of articulating surfaces could happen. The patient was immediately ordered to bed, and to have the limbs confined to each other by a bandage above the knees, more for the purpose of preserving the hip-joint in a perfect state of rest, than from any view of preventing the recurrence of displacement.

On the following morning he was able to move the limb in all its natural directions, although not without complaining of pain and stiffness; twelve leeches were therefore ordered to be applied over the hip-joint, from which he obtained almost immediate relief. From that period to the 29th of June, occupying a space of three weeks, he required no more medical care than attention to the extent he used his limb; and when he left the hospital, not a month after the reduction of his dislocation, he was enabled to walk perfectly well.*

Case XXXVI.—Mrs. M'Ewen, æt. twenty-three, was admitted under the care of Mr. Liston in the Edinburgh Royal Infirmary, July 5, 1831, having been more than a month the subject of dislocation of the right hip. Upon her admission the injured extremity was found more than two inches shorter than the left, the foot turned inwards, the knee resting upon the lower and inner part of the left thigh. She was capable of moving the dislocated limb freely inwards and forwards, but motion outwards and backwards was extremely limited and attended with much pain. The head of the right femur was distinctly felt on the dorsum ilii, and the trochanter major was placed near the anterior

* From Mr. B. Cooper's Surgical Essays.

and superior spinous process of the ilium. The hip and thigh were much swollen and occasionally the seat of lancinating pain. She states that the accident happened more than a month ago in consequence of her limb being forcibly drawn outwards from the body, at the time being sensible of a jerking sensation of the thigh, accompanied by a noise resembling that produced by a sudden extension of the finger joints. From the catamenia having appeared since her admission the attempt at reduction was delayed till the 9th. The pulleys were applied, and on a very slight extending force being employed the head of the bone was easily restored to the acetabulum, the femur at the time being rotated and its head pushed downwards and forwards. Considering the duration of the displacement the facility of reduction was remarkable, but may have been attributable to the patient having led an extremely dissipated life. A pad was placed between the knees and a roller applied around them. During the night she had been extremely restless, getting frequently out of bed, and the next morning the head of the bone was found again lodged on the dorsum of the ilium. Reduction, however, was accomplished with even greater facility than previously. The knees and ankles were now bound firmly together, and the horizontal position strictly enjoined. No untoward circumstance afterwards occurred, and the patient was soon dismissed enjoying the free use of her limb.

Case XXXVII.—A fractured cervix femoris produced by an attempt at reducing a dislocation on the dorsum ilii. George Flaxman, aged fourteen, of strumous diathesis and spare habit, was admitted into the Brighton Hospital, January 1st, 1831, under the care of Mr. Gordon Gwynne, in consequence of an injury to the shoulder, and partial paralysis of the lower extremities; the former arising from a blow, the latter without any obvious cause. The accident occurred about a week before admission. There was a large abscess about the shoulder, extending for some distance down the arm; it created great constitutional irritation, and an opening was made into it, when about a pint of pus made its escape. A large quantity of matter continued to be secreted, which found exit from various sinuses in the neighbourhood of the joint. He was ordered tonics and good diet, and the discharge decreasing, in about six weeks his health improved. He was then ordered to use the warm bath. One morning the nurse

whilst making his bed observed a tumor above and behind the left hip, which, upon being examined was found to be caused by a dislocation of the femur upon the dorsum ilii. The limb was about three inches shorter than the other, the knee and foot were turned inwards, and the head of the bone could be distinctly felt resting upon the dorsum ilii. The patient being questioned as to the cause of the accident, said he had met with it about a month before, whilst getting into the bath, from a fall on his knee; but as it had occasioned little pain, he had not mentioned it. A trial at reduction was proposed on the 27th of April, and the following plan adopted:—he was placed in a bath at 100°, increased to 110°, and remained there till he felt faint; he was then taken out, wrapped in a blanket, and placed upon a bed; tartarized antimony was given until it produced nausea; a linen roller was placed above the knee, over which the strap was applied for fixing the pulleys, a coarse towel being placed in the groin. We commenced by making gentle extension till the patient complained of pain, when we ceased; after the lapse of a few minutes we again tightened the pulleys, and gently rotated the limb; these means were tried for about three quarters of an hour, when a sudden snap was distinctly heard, as though the head of the bone had slipped into the socket; but on examination it was still found resting on the dorsum ilii, a fracture of the cervix femoris being produced. The limb remained much shorter than the other; and on rotating it a crepitus was heard, as though one portion of bone grated against another. The patient was put to bed, and some tinct. opii given him. Next morning there was a good deal of tension about the limb, and he complained of pain, for which some leeches were applied. All febrile symptoms soon disappeared, and after the expiration of six weeks he was ordered passive motions of the limb, by which he acquired great power of moving the leg, and was able in a short time, with the assistance of a stick, to walk tolerably well; He left the hospital on the 22nd of September, since which time I have had an opportunity of seeing him; the leg had become much stronger, and he could bear the weight of the body on it without any inconvenience.

Case XXXVIII. — J. Harris, æt. thirty-nine, a coachman, on the 20th of December, 1836, whilst exercising his master's carriage horses was thrown off and fell upon his back, his

thighs being flexed upon his abdomen. The led horse stumbling at the same moment struck his left knee with great force, producing such injury to the limb that he was unable to rise without assistance, which was quickly afforded him. He was immediately carried home, when it was discovered that the head of the femur had been driven from the socket. He was bled thirty ounces in the recumbent posture, and small doses of tartarized antimony were administered, but without these means producing syncope. He was then placed upon a large table and his pelvis fixed in the usual manner, by long jack-towels passed between the perinæum and the injured joint; the extending apparatus, composed also of a round towel, was then applied above the knee, and to it were attached weights, to the amount of one hundred and twelve pounds, fastened to a rope which was rove through a pulley; to the influence of this weight he was submitted for four hours, but without any effect being produced, he was therefore then sent to Guy's Hospital. At half-past seven P.M. he was taken into the operating theatre. The pelvis was fixed by the common padded bandage, whilst to the knee was attached the circular bandage and pulleys, and gradual extension was made across the lower third of the opposite thigh for the space of twenty minutes, during which period he was given three grains of tartarized antimony in solution. The head of the bone was soon found to descend, when the pulleys were suddenly slackened so as to allow of the limb being quickly rotated inwards, and the bone was heard to slip into its socket. The limb immediately regained its natural length and position, the patient was put to bed and the knees fastened together, some leeches were applied to the hip-joint, but he recovered so rapidly that he was able to leave the hospital on the 17th of January, and to walk with but little inconvenience with the aid of a stick. This dislocation was reduced by Mr. Callaway.

Case XXXIX.—Bennett Jones, æt. twenty-seven, a strong young muscular labourer, was admitted into Guy's Hospital on September the 2nd, 1839, under Mr. Key. Shortly before admission, he was struck by a three ton weight on the back of his right leg and thigh, in such a manner as to force the right knee in advance of and across the other leg. On admission there was considerable swelling of the hip, and pain on motion. The case was treated as a bruise till September 7th, when on careful

examination the following appearances were found:—When the patient lay on his back the right leg appeared shortened two inches, the knee in advance of the other; the foot inverted and lying over, but not in contact with the dorsum of the left foot; the trochanter was unusually prominent, and nearer the anterior superior spinous process of the ilium than natural; and the anterior inferior spinous process could be distinctly felt. The patient had considerable motion of the hip, and could in some degree bend his knee but could not evert it. After some exertion he could, when standing, bring the heel of the right foot within an inch of the ground, the toes remaining inverted. By employing gentle extension, the limb could be elongated to its proper dimensions, and the prominence of the trochanter was considerably diminished, but returned as soon as the extension was discontinued. On rotating the femur, with one hand applied to the knee, a very distinct crepitus could be felt at the hip. The crepitus could be felt only by the hand applied to the knee, not being discovered when the hand was placed on the hip. The trochanter on rotation moved with the femur, which could be bent and inverted; but could not be so much everted as to turn the toes out. The head of the femur could not be felt on the dorsum ilii.

The man was brought into the theatre and reduction was attempted by Mr. Morgan, with the heel against the perinæum, on the same plan as in dislocation into the axilla, extension being made from a bandage attached to the knee. On making very moderate extension the head of the bone returned into the acetabulum, the projection of the trochanter disappeared, and the inferior spinous process of the ilium could no longer be felt. The return was accompanied with a jerking, grating motion, not with an ordinary snap; and as soon as the extending force was taken off, the head of the bone slipped from the acetabulum, and the prominence of the trochanter returned. Mr. Morgan at once declared it to be a case of fractured acetabulum. He again reduced it two or three times with ease, but the bone would not remain in its position, and immediate displacement followed the removal of the extending force. By continued extension and pressure on the trochanter, so as to preserve the proper position, the limb had its normal motion and

the toes could be everted. The man was placed in bed, with both legs extended; a bandage was applied, so as to bind the legs together immediately above the knees. Twenty leeches were applied to the hip; and an opiate was given to prevent action of the bowels. He remained in bed with this bandage applied for a week, keeping at perfect rest, the injured limb retaining nearly its proper length and position. When the bandage was removed he could move the right leg, could evert the foot, but not the knee, and there was a little shortening and inversion: he had during the week suffered considerable pain in the hip, aggravated on the slightest change of position, and the part was hot and swollen. Leeches were again applied, and the patient was placed on a double inclined plane.

At present (September 25th) he still continues on the plane; there is slight shortening and inversion of the foot; he can evert the foot, but not the knee. There is no pain in the hip; and the joint has its natural shape.

Mr. Charles H. Todd, surgeon to the Richmond Surgical Hospital, and Professor of Anatomy and Surgery at Dublin, has lately published "An Account of a Dissection of the Hip-joint after recent Luxation, with Observations on the Dislocations of the Femur upwards and backwards;" from which the following case is extracted.

Case XL.—In the summer of 1818, a robust young man, in attempting to escape from his bed-room window, in the second floor of a lofty house, fell into a paved area; by which accident, his cranium was fractured, and his left thigh dislocated upwards and backwards.

The dislocation was reduced without difficulty; however, an extensive extravasation of blood having taken place on the brain, the patient lingered in a comatose state for about twenty-four hours, and then died. On the next day, dissection was performed, and the following appearances were observed in the injured joint and the parts contiguous to it.

On raising the gluteus maximus, a large cavity, filled with coagulated blood, was found between that muscle and the posterior part of the gluteus medius: this was the situation which had been occupied by the dislocated extremity of the femur. The gluteus medius and minimus were uninjured. The pyriformis,

gemini, obturatores, and quadratus were completely torn across. Some fibres of the pectinalis were also torn. The iliacus, psoas, and adductores were uninjured. The orbicular ligament was entire at the superior and anterior part only, and it was irregularly lacerated throughout the remainder of its extent. The interarticular ligament was torn out of the depression on the head of the femur, its attachment to the acetabulum remaining perfect. The bones had not sustained any injury.

SECTION III.

DISLOCATION DOWNWARDS, OR INTO THE FORAMEN OVALE.

The foramen ovale is situated between the rami of the pubes and the ischium, somewhat below and on the inner side of the acetabulum. It is filled up by a ligament, which is attached to the sharp edges of the foramen, and which has an oval aperture at its upper and anterior part to permit the passage of the obturator vessels and nerves. By its external and internal surfaces it gives attachment to the obturator muscles.

Causes.—Dislocation of the femur into the foramen ovale is generally caused by a heavy weight falling upon the pelvis, whilst the back is bent forwards, and the thighs are separated from each other. The ligamentum teres and the lower part of the capsular ligament are torn through, and the head of the bone becomes placed in the posterior and inner part of the thigh, upon the obturator externus muscle.

It has been erroneously supposed, that the ligamentum teres is not torn through in this dislocation; because in the dead body, when the capsular ligament is divided, and in the living body in certain cases of relaxation, the head of the bone can be drawn over the lower edge of the acetabulum without tearing the ligamentum teres. But this ligament is of necessity torn through in the ordinary dislocation from violence.

Symptoms.—In this dislocation the limb is two inches longer than the other. The head of the bone can be felt by pressure of the hand upon the inner and upper part of the thigh towards

the perinæum, but only in very thin persons. The trochanter major is less prominent than on the opposite side. The body is bent forwards by the tension of the psoas and iliacus internus muscles. The knee is considerably advanced if the body be erect; it is widely separated from the other, and cannot without great difficulty be brought near the axis of the body so as to touch the other knee, in consequence of the extension of the glutei and pyriformis muscles. The foot though widely separated from the other, is generally neither turned outwards nor inwards, although I have seen it varying a little in this respect in different instances; but the position of the foot does not in this case mark the accident. *The bent position of the body, the separated knees, and the increased length of the limb*, are the diagnostic symptoms. The position of the head of the bone is below, and a little anterior to, the axis of the acetabulum; and a hollow is perceived below Poupart's ligament.

There is an excellent preparation of this accident in the collection at St. Thomas's Hospital, which I dissected many years ago. The head of the thigh-bone was found resting in the foramen ovale, but the obturator externus muscle was completely absorbed, as well as the ligament naturally occupying the foramen, now entirely filled by bone. Around the foramen ovale bony matter was deposited so as to form a deep cup, in which the head of the thigh-bone was enclosed, but in such a manner as to allow of considerable motion: the cup thus formed, surrounded the neck of the thigh-bone without touching it, and so completely enclosed its head, that it could not be removed from its new socket without breaking its edges. The inner side of this new cup was extremely smooth, not having the least ossific

projection at any part to impede the motion of the head of the bone, which was only restrained by the muscles from extensive movements. The original acetabulum was half filled by bone, so that it could not have received the head of the thigh-bone if an attempt had been made to return it into its natural situation. The head of the thigh-bone was very little altered; its articular cartilage still remained; the ligamentum teres was entirely broken, and the capsular ligament was partially torn through; the pectinalis muscle and adductor brevis had been lacerated, but were united by tendon; the psoas muscle and iliacus internus, the glutei and pyriformis, were all upon the stretch. Nothing can be more curious, or, to the surgeon and physiologist, more beautiful, than the changes produced by this neglected accident.*

TREATMENT.—The reduction of this dislocation is in general very easily effected. If the misfortune be of recent occurrence, it is requisite to place the patient upon his back, to separate the thighs as widely as possible, and to place a girth between the pudendum and the upper part of the luxated thigh, to which is fixed the hook of the pulleys, which are to be attached to a staple placed on the same side as the injured limb of the patient;—while the counter-extending force for fixing the pelvis is composed of a girth, which is completely to surround both ilia; and one end of which is to be admitted through the noose formed by the girth attached to the dislocated limb. It then being attached to the opposite staple, the two girths, during the application of the extending power, are made to fix each other. The apparatus

* See the figures at page 6.

being now properly adjusted, the surgeon should direct that extension should be gradually made with the pulleys until the head of the femur can be felt moving from the foramen ovale. He is then to pass his hand behind the ankle of the sound limb, and to grasp the ankle of the dislocated extremity, and draw it inwards towards the middle line of the patient's body. He thus acts upon the dislocated femur with the most powerful lever of the first order, and usually readily reduces the dislocation. I saw a dislocation thus reduced, which had happened very recently, and which was subjected to an extension in St. Thomas's Hospital, almost immediately after the patient's admission. In a similar case, the thigh might be fixed by a bedpost received between the pudendum and the upper part of the limb, and the leg be carried inwards across the other. But in general it is required to fix the pelvis by a girth passed around it, and crossed under that which passes around the thigh, to which pulleys are to be attached, otherwise the pelvis will move in the same direction with the head of the bone.

In those cases in which the dislocation has existed for three or four weeks, it is best to place the patient upon his sound side; to fix the pelvis by one bandage, and to carry under the dislocated thigh another bandage, to which the pulleys are to be affixed perpendicularly; then to draw the thigh upwards, whilst the surgeon presses down the knee and foot, to prevent the lower part of the limb from being drawn with the thigh-bone. Thus the limb is used as a lever of very considerable power. Great care must be taken not to advance the leg in any considerable degree, otherwise the head of the thigh-bone will be forced behind the acetabulum into the ischiatic notch, from whence it cannot be afterwards reduced; this accident I once saw happen.—*Vide* Case XLIII.

Case XLI.—A gentleman was riding on horseback on the 4th of January, 1818, when the horse suddenly started to the right side; and in endeavouring to keep his seat by the pressure of the right thigh against the saddle, he was thrown, and the fall occasioned a severe contusion upon his head, which produced alarming symptoms. On the following day it was observed that the right thigh was useless, and that the knee was raised and could not be brought into a straight line with the other, having at the same time a direction outwards, which required it to be tied to

the other knee: the symptoms of injury to the head precluded, at this time, any attempt at reduction. In fourteen days he was so far recovered that he was able to rise from his bed, and in a month he began to walk with crutches.

On November 1st, 1818, I first saw him; and the appearances of the injured limb were then as follow: — The thigh was longer than the other by the length of the patella; the knee was advanced; and when he was in the recumbent posture, the injured leg could not be drawn down to the same length with the other. The upper part of the thigh-bone was thrown backwards, so as to render the hollow of the groin on the injured side deeper than that on the other. The toes were rather everted; but when the body was erect, were capable of resting on the ground, though the heel was not. The head of the bone could not be felt, and the trochanter was much less prominent than usual. When the upper part of the thigh-bone was pressed against the new acetabulum and moved, there was a sensation of friction between two cartilaginous surfaces, which, although not easily described, is readily distinguished from the crepitus occasioned by a fractured bone. In a sitting posture the injured leg was two inches longer than the other; and to that degree the knee was projected beyond the sound one. In progression the knee was bent; and the body being thrown forwards, the patient rested chiefly upon his toe, and halted exceedingly in walking, presenting the gait of a person in the act of mowing. The sartorius and gracilis muscles were put very much upon the stretch. At first he suffered from pain in the dislocated hip and thigh, but that is not now the case unless he attempts to stand on that limb only. His toe at first was with difficulty brought to the ground, but he is now improved in walking; for on the first trial, with the assistance of a crutch and stick, he could not exceed half a mile, but is now able to walk two miles. In flexion his thigh admits of considerable motion, but he cannot extend it further than to bring the ham to the plane of the other patella. The knees cannot be brought together, but he advances one before the other in the attempt. He can sit without pain, but the jolting of a carriage hurts him exceedingly; and the attempt to sit on horseback produces excessive suffering. He cannot straighten his leg when his body is erect, nor can he stoop to tie his shoe on the injured side. Pain is produced by resting on that hip in

bed. No attempt was made to reduce the limb; the injury to the head might have rendered it dangerous in the commencement, and at the time when I saw him there was no chance of success.

The subjoined case was kindly forwarded to me by Mr. Daniel, of Leadenhall Street, whose knowledge of his profession, and zeal in the pursuit of it, I have had frequent opportunities of observing.

CASE XLII.—Mr. Thomas Clarke, a farmer, about fifty years of age, was driving home in his cart from market, when the horse took fright and ran away with him. In his endeavour to stop the horse, he fell over the front of the cart on his face, and the knee struck against some part of it in the act of falling, by which means the thighs were separated; the wheel, he also states, passed over his hip.*

My friend, Mr. Potter, of Ongar, in Essex, whose ability as a surgeon in that neighbourhood is justly appreciated, was consulted in this case, between two and three weeks after the accident happened. The nature of the accident was extremely evident: the limb was full three inches longer than the other, the body bent forwards, the knees separated, and the foot rather inclined outwards; these were the leading diagnostic marks. Mr. Potter having clearly ascertained the position of the dislocated limb, I accompanied him the following morning, in order to assist in the reduction; and the following were the means employed.

Our first object was to produce relaxation; and finding the patient was sufficiently strong to bear the plan usually recommended in cases of dislocation, where much resistance is expected, we drew away some blood from the arm; this, however, was not sufficient for our purpose, and a solution of tartar emetic which we had brought with us was administered. The patient was laid upon his side, close to the edge of the bed (that being the most convenient place), a girth was passed round the pelvis, and carried through the frame of the bedstead, which completely prevented the possibility of the body moving whilst extension was going on; a second girth was applied between the thighs, fixed to the one above, to which the

* *Query.*—Was this, or the extended state of the limbs, the cause of the dislocation?

pulleys were attached. Whilst extension was making, Mr. Potter took hold of the limb at the knee, and drew it rather upwards, and towards the sound thigh, occasionally rotating the limb. When the extension had been continued about ten minutes, the nausea produced by the tartar emetic was so excessive, that the patient begged of us to desist until the morrow, observing, he felt so bad that he was fearful of falling off the bed; this exclamation, it hardly need be said, was a stimulus to our proceeding; and in five minutes after, the limb was suddenly heard to snap into its original cavity. The patient was put to bed, a roller being applied round the pelvis. At the end of five days, he felt so well that he left his room; and in a short time suffered no other inconvenience than stiffness in the joint.

Although a dislocation into the foramen ovale may be occasionally reduced by attempts made in a very inappropriate direction, yet an instance has occurred that shows the mischief that may arise from an error in this respect. I subjoin the following.

Case XLIII.—A boy, sixteen years old, had a dislocation of the thigh into the foramen ovale; he was placed upon his sound side, and an extension of the superior part of the thigh was made perpendicularly; the surgeon then pressed down the knee, but the thigh being at that moment advanced, the head of the bone was thrown backwards, and passed into the ischiatic notch; from which situation it could not be reduced.

I am indebted to Mr. Key for the particulars of the annexed case, which was admitted into Guy's Hospital under Mr. Forster.

Case XLIV.—Stephen Holmes, aged forty-one, while working in a gravel-pit at Camberwell, was suddenly overwhelmed by a large mass of gravel, and remained buried under it till dug out by his companions. When the gravel was removed he was found in a sitting posture, with his legs widely separated, and unable to approximate them. In this position he was brought to the hospital, about seven o'clock in the evening, an hour after the accident had happened, and placed under the care of Mr. Carey, dresser to Mr. Forster.

Being undressed and placed in bed in the recumbent posture, he was seen lying with his left thigh bent upon the pelvis, his knee consequently elevated and the whole limb fixed at a con-

siderable distance from the other. On carrying the eye to the upper part of the thigh near the hip-joint, a considerable change in form was manifest: the projection of the trochanter was entirely lost, and in its place a deep hollow was perceptible; while, at the inner part of the thigh, near the pubes, a distinct projection appeared, having the form of the head of the bone covered by the abductor muscles. From these general appearances, we regarded the accident as a dislocation of the femur into the foramen ovale, and proceeded to make a more minute examination of the limb, to ascertain the precise nature of the injury.

The man was desired to rise from his bed and sit on the edge of it, which he did without inconvenience or pain; in this position his left knee projected at least two inches and a half beyond the sound limb; this apparent elongation of the leg arose principally from the oblique bearing of the pelvis, the real elongation being afterwards ascertained to be not more than an inch and a quarter. In the attempt at the erect posture, which he maintained with some difficulty, his body was bent forward in consequence of the projection of the pelvis over the thigh: the knee was bent, and the toe, which was slightly inverted, rested on the ground; the whole limb was advanced before the sound one, and remained in a state of abduction. He was then laid upon a firm table on his back, and the capability of motion in the limb was carefully noted. His knee was first bent toward his breast without any difficulty, and to as full an extent as the opposite limb; the power of abduction was also complete, and the attempt was unattended with pain; but extension and adduction of the thigh were the motions most impeded. When the limb was made to approximate to the sound one, which could not be done without producing pain and numbness on the inner side of the thigh, the patellæ remained eleven inches distant from each other; and as soon as the hand was withdrawn from the ankle, the leg flew outward with a spring from the reaction of the two lesser glutæi muscles. The limb could not be carried backward, but remained permanently bent at the hip-joint; and when any attempt was made to fix it, the patient complained of great pain in the direction of the psoas and iliacus muscles. The depression observed at the site of the trochanter was such as to render it difficult to feel that process; while on the inner

side of the thigh a distinct projection was formed by the head of the bone, which could be felt under the adductors. These latter muscles were rendered very tense by the projecting bone. The nates appeared to preserve their usual form.

Reduction.—Having never had an opportunity of witnessing this kind of dislocation since my attendance at the hospitals, during the last eight years, I wished to see how far the method of reduction which you have laid down was applicable in the present case. Your "Treatise on Dislocations and Fractures" being in the hands of one of the students, we referred to the plate, and proceeded to apply the pulleys and bandages in the manner there delineated. The apparatus being once carefully and securely adjusted, require no alteration, as it neither slipped from its situation nor occasioned any inconvenience to the patient. Extension was then made by drawing the displaced limb across its fellow, while the pulleys drew the head of the bone outwards; but in doing this we ran some risk of throwing the head of the femur into the ischiatic notch: for the thigh being large and fleshy at the back part, was, when drawn across the other, necessarily carried somewhat forwards, and thus tilted the head of the bone backward. Had any alteration taken place in the situation of the head of the femur during this extension, it would have been carried under the acetabulum into the ischiatic notch; it was therefore thought advisable to carry the leg behind the sound one; and as soon as this was done the head returned, with an audible crack, into the acetabulum. The whole extension occupied fifteen minutes.

This species of dislocation of the femur is by far the most easy of reduction of any that has come under my observation; and it may be presumed, that had the leg at first been carried behind instead of before the other, the replacement of the limb might have been effected immediately. Where the limb is large it is impossible to carry it in a right line across its fellow; and perhaps, in order to avoid the danger to which I have alluded, and which I have often heard you point out in your lectures, it would be as well to adopt the line of extension which in this instance answered so well. This patient could stand by the side of his bed, without support, in a week after the accident.

Case XLV.—George Bell, æt. thirty-four, a healthy labourer,

was admitted on the 28th of March, 1834, under the care of Mr. B. Cooper, into Guy's Hospital. He stated that while digging in a sand-pit a quantity of earth fell upon him, and forced him down a precipice to the depth of eighty feet. He thinks he fell upon his hip, and found upon the attempt to rise that he was unable to do so without assistance; he experienced extreme pain, and total inability to move the left thigh, and expressed a desire to be immediately conveyed to Guy's Hospital. I saw him about two hours after his admission, and upon examination, readily recognised a dislocation into the foramen ovale. I immediately ordered the patient to be bled in the erect posture, from a large orifice, and as soon as he became faint a grain of tartarized antimony was exhibited, and repeated every ten minutes, so as to maintain a state of approaching syncope. In this condition he was taken into the operating theatre, and the apparatus for fixing the pelvis and making extension on the displaced limb was applied precisely as directed by Sir Astley Cooper. The extension was gradually made, and maintained for a quarter of an hour. I then placed a towel under the upper part of the thigh, requesting an assistant to stand over the patient and to raise the head of the bone from the foramen ovale: this plan did not however succeed, and was not for many minutes persisted in, but while in the act of removing the towel, it seemed as if the patient's attention was directed to the change that was taking place, for the bone instantly slipped into the acetabulum. The patient was then conveyed to his bed, and in three weeks after the accident he left the hospital perfectly well, although some constitutional remedies had been required during the progress of his cure to overcome some slight functional disturbance.

CASE XLVI.—*Dislocation of the right femur into the foramen ovale.*—A man between thirty and forty years of age, on the afternoon of February the 10th, 1834, having slipped from the top of a dung-cart with his legs separated, had his right thigh-bone dislocated into the foramen ovale. He was sent up from the neighbourhood of Ilford, and arrived at the London Hospital about eight hours after the accident occurred. The legs were found to be widely separated from each other, and could not be brought together; there was a considerable depression in the situation of the great trochanter, and the limb was much bent

upon the trunk, but did not appear at all lengthened.* The head of the bone could be indistinctly felt by pressure with the hand at the upper and inner part of the thigh. Attempts were made to reduce the dislocation by fixing the pelvis and making extension across the opposite limb, at the same time that a fulcrum was made by a towel passed around the upper part of the thigh. They were continued for some time unsuccessfully, when the pulleys breaking, and it being late at night, further proceedings were deferred till the next day.

11th. The patient having taken two doses of tartar emetic without any effect upon the stomach, was carried into the operating theatre at two P. M. Attempts at reduction were again made, and powerful extension employed for upwards of an hour without success. The tartar emetic was repeated in large doses, and the man becoming faint was placed in a sitting posture upon the lower bench of the operating theatre, with one of the posts supporting the rail, defended by pads, closely applied to the upper and inner part of his right thigh, being supported behind by the back of the bench, and on his right side by an assistant. Extension was then made with the pulleys in a direction across the corresponding thigh, and after a short time the bone slipped into the acetabulum, unperceived at the moment.

The inflammation about the joint afterwards was very slight, and soon subsided. The skin was excoriated at the part where the towels were attached, and a small portion of it sloughed. In less than a month he regained the complete use of the limb, and was consequently discharged.

CASE XLVII. — Hugh Murray, æt. 55, a labouring man, while working in a gravel pit was buried by the falling in of the side of the pit, and according to his account he was thrown upon his face. I saw him the next day, and found he had a comminuted fracture of the left femur, and a dislocation of the right into the foramen ovale. The shaft of the other thigh-bone being broken, it was difficult to distinguish the lengthening of the dislocated limb. The reduction was effected in the usual way.

In this case the diagnosis may be said to have been somewhat more difficult than usual, from the fracture of the opposite thigh, as it could not be well determined whether the dislocated limb

* The man mentioned that the injured limb had always been shorter than the other.

was lengthened, and from the almost total absence of the bent position of the body, which Sir A. Cooper has given as one of the first diagnostic symptoms; however, the great separation of the knee and foot from the other limb, the turning out of the toes, the depression where the great trochanter should project, the protuberance caused by the head of the bone on the inner side of the thigh, the knee being flexed and the impossibility of extending it, together with the seat of the pain being referred to the situation of the foramen ovale, left no doubt of the nature of the accident.

This case was published by Dr. Bellingham in "The Lancet," No. 560.

SECTION IV.

DISLOCATION BACKWARDS, OR INTO THE ISCHIATIC NOTCH.

The space which is called the ischiatic notch, is bounded above and anteriorly by the ilium, posteriorly by the sacrum, and inferiorly by the sacro-sciatic ligament. It is formed for the purpose of giving passage to the pyriformis muscle and to the sciatic nerve, as well as to the three arteries — the glutæal, the ischiatic, and the internal pudic. In the natural position of the pelvis, it is situated posteriorly to the acetabulum and a little above its level. When the head of the bone is thrown into this space, it is placed backwards and upwards, with respect to the acetabulum; therefore, although I call this the dislocation backwards, it is to be remembered that it is a dislocation backwards and a little upwards.

In this dislocation the head of the thigh-bone is placed on the pyriformis muscle, between the edge of the bone which forms the upper part of the ischiatic notch, and the sacro-sciatic ligaments, behind the acetabulum, and a little above the level of the middle of that cavity.

This dislocation is the most difficult both to detect and to reduce: to detect, because the length of the limb differs but little from nature, and its position, in regard to the knee and foot, is not so much changed as in the dislocation upwards: — to reduce, because the head of the bone is placed deep behind the aceta-

bulum, so that it is lifted with difficulty over the edge of that cavity.

SYMPTOMS. — The signs of this dislocation are, that the limb is from half an inch to one inch shorter than the other, but generally not more than half an inch; that the trochanter major is behind its usual place, but is still remaining nearly at right angles with the ilium, with a slight inclination towards the acetabulum. The head of the bone is so buried in the ischiatic notch, that it cannot be distinctly felt, except in thin persons, and then only by rolling the thigh-bone forwards as far as the comparatively fixed state of the limb will allow. The knee and foot are turned inwards, but less than in the dislocation upwards; and the toe rests against the ball of the great toe of the other foot. When the patient is standing, the toe touches the ground, but the heel does not quite reach it. The knee is not so much advanced as in the dislocation upwards, but is still brought a little more forwards than the other, and is slightly bent. The limb is so fixed that flexion and rotation are in a great degree prevented.*

DISSECTION.—There is a good specimen of this accident in the collection at St. Thomas's Hospital, which I met with accident-

* I have heard it a matter of discussion between equally competent surgeons respecting a case of dislocation, whether the head of the bone was placed upon the dorsum of the ilium or in the ischiatic notch, the dispute arising as to the extent of shortening of the limb, which, in my opinion, does not form a very perfect diagnostic mark; for the limb becomes invariably shorter as the space of time increases since the accident has occurred, so that it may vary from half an inch at first to a subsequent shortening of three inches. The best sign of this accident, I believe, is the greater displacement of the head of the thigh-bone backwards, and the consequent obliquity of the shaft, so as to direct the knee across the middle of the opposite thigh instead of just above the patella. —*Ed.*

ally, in a subject brought for dissection. The original acetabulum is entirely filled with a ligamentous substance, so that the head of the bone could not have been returned into it. The capsular ligament is torn from its connection with the acetabulum, at its anterior and posterior junction, but not at its superior and inferior. The ligamentum teres is broken, and an inch of it still adheres to the head of the bone. The head of the femur rests behind the acetabulum on the pyriformis muscle, at the edge of the notch, above the sacro-sciatic ligaments. The muscle on which it rests is diminished, but there has been no attempt made to form a new bony socket. Around the head of the thigh-bone there is a new capsular ligament; it does not adhere to the cartilage of the head of the bone which it surrounds, but could, when opened, be turned back to the neck of the thigh-bone, so as to leave its head completely exposed. Within this new capsular ligament, which is formed of the surrounding cellular membrane, the broken ligamentum teres is found. The trochanter major is placed rather behind the acetabulum, but inclined towards it.

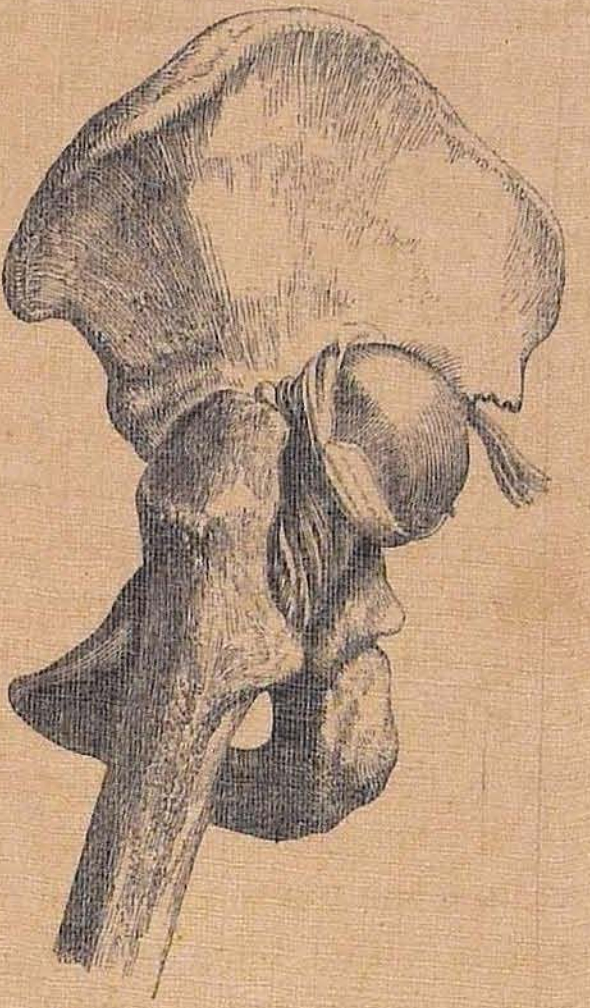

In this specimen, from the appearance of the parts, the dislocation must have existed many years; the adhesions were too strong to have admitted of any reduction, and if reduced, the bone could not have remained in its original socket.

CAUSE.—This species of dislocation is produced by the application of force, when the body is bent forward upon the thigh, or when the thigh is bent at right angles with the abdomen; in which positions, if the knee be pressed inward, the head of the bone is thrown behind the acetabulum.

The reduction of the dislocation into the ischiatic notch is, in general, extremely difficult, but is to be effected in the same manner as directed for the reduction of a dislocation on

the dorsum ilii, excepting that the direction of the extending force is to cross the middle of the sound thigh instead of one-third above the knee, and moreover, the patient is placed on his side, instead of on his back; but the mode of fixing the pelvis

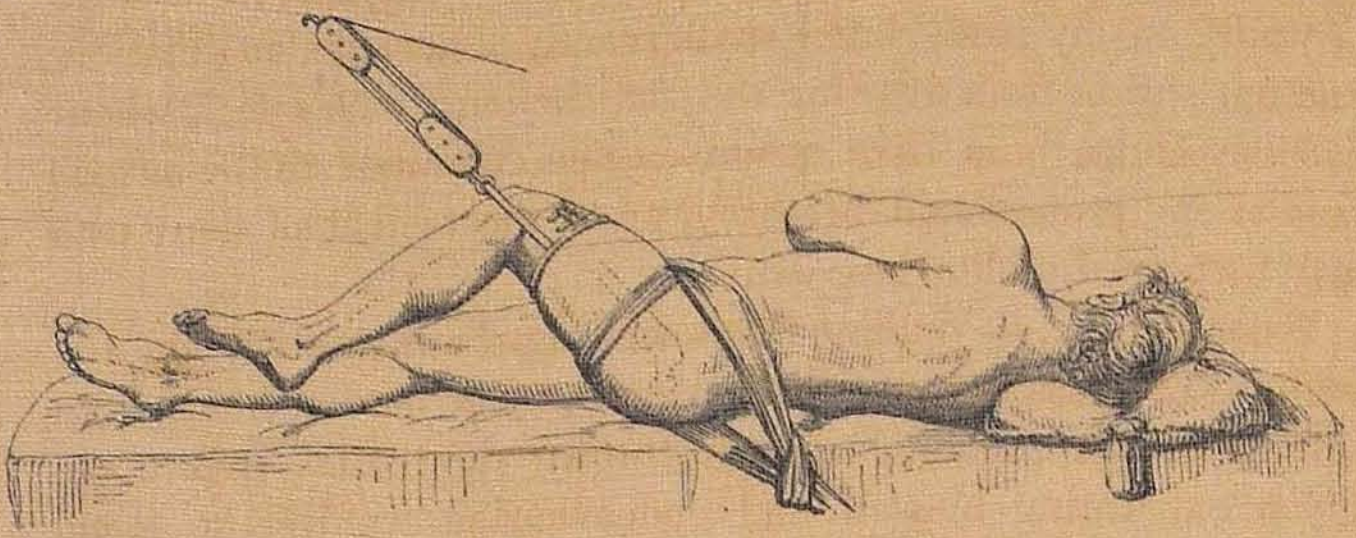

and the apparatus for extension, is precisely the same in both dislocations. Whilst the extension is in progress, the head of the femur should be lifted out of the notch, and over the edge of the acetabulum by means of a round towel placed under the upper part of the thigh, and over the shoulders of an assistant, who at the same time, resting both his hands on the patient's pelvis, obtains a great power over the dislocated head of the femur.

Although the preceding is the method in which this dislocation is most easily reduced, yet I have seen a different mode practised; and I shall mention it here, as it shows how capable the muscles are themselves of drawing the head of the bone to its socket, when it is lifted from the cavity into which it has fallen, if the accident has not occurred so long as to render them permanently contracted.

Case XLVIII.—A man, aged twenty-five, was admitted into Guy's Hospital under the care of Mr. Lucas: upon examination, the thigh was found dislocated backwards; the limb scarcely differed in length from the other, being not more than half an inch shorter; the groin appeared depressed; the trochanter was resting a little behind the acetabulum, but inclined towards it; the knee and foot were turned inwards, and the head of the bone could, in this case, be felt behind the acetabulum. An extension was made by pulleys in a right line with the body; at the same time the trochanter major was thrust forward with the hand, and the bone

returned in about two minutes into its socket with a violent snap.

The following case I received from Mr. Rogers, a very intelligent surgeon at Manningtree. My insertion of the flattering manner in which he has expressed himself may savour a little of vanity on my part; but I shall readily suffer this imputation, and not shrink from avowing the satisfaction which I feel, whenever my endeavours have in any degree conduced to the advantage of my professional brethren, or to the benefit of those who may be placed under their care.

Case XLIX.—William Dawson, aged thirty-four, on the 15th of August, 1818, while spending his harvest-home with several of his companions, was thrown down and trod upon. Upon extricating himself and endeavouring to rise, he found some serious injury to his right thigh rendered him incapable of standing; in this state he was dragged by his associates for many hundred yards into a stable, where he lay till the next morning. I then saw him lying upon a mattress, with the hip and thigh on the right side prodigiously swollen and painful; and was particularly struck with the appearance of the knee and foot on the same side, which were very much turned inwards, but the limb was scarcely shortened. I ordered him to be carefully conveyed home upon a shutter, supported by six men, a distance of about half a mile. From the immense swelling and general enlargement of the whole thigh, and of the soft parts around the pelvis, it was impossible to ascertain exactly the state of the injury; but I was fully impressed there was some unusual dislocation of the head of the thigh-bone. He was accordingly bled, both by general and topical means, and emollient poultices applied to the whole of the swollen parts; brisk purgatives were also administered, succeeded by saline medicines, and a quiet position was enjoined for eleven days, by which time the swelling began somewhat to subside. Still the precise nature of the injury was not satisfactorily evident; but it was thought by Mr. Nunn of Colchester, and Mr. Travis of East Bergholt, who had kindly come over to witness it, that there was a luxation. The only difficulty we had in reconciling ourselves to this notion was, the belief in our minds that no author adduced an instance of this accident, without an alteration in the length of the limb, except it might be Mr. Astley Cooper, in his new publication,

which neither of us had yet seen. We accordingly had recourse to a minute examination of the skeleton; when we immediately fancied we could account for the absence of the usual marked signs of displacement of the head of the bone, excepting the inversion of the knee and foot, in this kind of luxation; for we noticed, that if the head of the bone be luxated sideways into the ischiatic notch, it will produce scarcely any difference in the length of the limb. Trusting that a little further delay might not be attended with any material disadvantage, but give a chance for the entire subsidence of all the inflammation and swelling, we proposed meeting again as soon as we conveniently could, by which time we might consult Mr. Cooper's work. We accordingly met on Sunday, the 30th of August, which was fifteen days after the accident; and from the complete removal of all swelling, the whole of the femoral bone was satisfactorily traced to its rounded head, which was lodged in the ischiatic notch.

Upon referring to the book, which we had now before us, we found the case delineated and described; and as it was exhibited in a plate, we had only to imitate, in order to accomplish the reduction of the bone. In the presence of two or three other medical gentlemen we commenced the operation; but as it would be unnecessary to state every particular, considering the manner in which the position of the patient, and the fixing of the pulleys and towels, are demonstrated by that publication, suffice it to say, that after ten or twelve minutes of gradual extension, the reduction of the bone was most readily and admirably accomplished.

Preparatory to commencing the operation we took thirty ounces of blood from the arm *ad deliquium*, and afterwards, while fixing the pulleys, etc., we gave four grains of tartarized antimony at intervals to produce nausea. Immediately after the operation, we gave one grain of opium, applied sedative lotions to the parts, and proceeding carefully for about a fortnight, the patient was enabled to move upon crutches, and shortly after went home perfectly well.

The dislocation into the ischiatic notch has been as far as I know, in every author who has written on the subject, incorrectly described; for it has been stated, that the limb was lengthened in this accident, and I need scarcely mention the mistakes

in practice which have originated in so erroneous an opinion; one instance, however, of such an error I must here give. A gentleman wrote to me from the country in these words:—"I have a case under my care of injury of the hip, and I should suppose it a dislocation into the ischiatic notch, but that the limb is shorter, instead of being longer, as authors state it to be." Into this error those authors must have fallen from having examined a pelvis separated from the skeleton, and observed that the ischiatic notch was below the level of the acetabulum when the pelvis was horizontal, although it is above the acetabulum in the natural oblique position of the pelvis, at least as regards the horizontal axis of the two cavities.

I am indebted to Mr. James Chapman, dresser at Guy's Hospital, for the following case.

Case L.—John Cockburn, a strong muscular man, aged thirty-three, was admitted into Guy's Hospital on the 31st of July, 1819. While carrying a bag of sand at Hastings on the 24th of July, he slipped, and dislocated the left hip-joint. The foot on the affected side was plunged suddenly into a hollow in the road, which turned his knee inwards, at the same time that his body fell with violence forwards. On the day of the accident two attempts were made to reduce the dislocation by pulleys, but without success; and on the 27th of July, a third, but equally unsuccessful trial was made, although continued for nearly an hour.

It was found upon examination that the thigh was dislocated backwards into the ischiatic notch. The patient was carried into the operating theatre soon after his admission; and when two pounds of blood had been taken from him, and he had been nauseated by two grains of tartarized antimony, gradually administered, extension was made with the pulleys in a right line with the body, and the upper part of the thigh was raised, while the knee was depressed; the extension was continued at least for an hour and half, during which time he took two grains more of tartarized antimony, by which he was thoroughly nauseated: the attempts, however, at reduction did not succeed.

On the 3rd of August, the tenth day after the accident, Mr. Astley Cooper succeeded in reducing it in the following manner:—He ordered so much blood to be taken from the arm as to produce a feeling of faintness. A table was placed in the

centre, between two staples, upon which the patient was laid on his right side; a girth was passed between the scrotum and the thigh, and carried over the pelvis to the staple behind him; and thus the pelvis was, as far as possible, fixed; a wetted roller was carried around the lower part of the thigh, just above the knee, and a leathern strap buckled on it, to which and to a staple before the limb the pulleys were fixed. The body was bent at right angles with the thigh, which crossed the upper part of the other thigh: then the extension with the pulleys was begun, and gradually increased until it became as great as the patient could bear. An assistant was then directed to get upon the table, and to carry a strong band under the upper part of the thigh, by which he lifted it from the pelvis, so as to give an opportunity for the head of the bone to be turned into its socket. Mr. South, who held the leg, was directed to rotate the limb inwards; and the bone, in thirteen minutes, was heard to snap suddenly and violently into its socket.

I believe that in this case I should not have succeeded in reducing the limb, but from attention to two circumstances: first, I observed that the pelvis advanced within the strap which was employed to confine it, so that the thigh did not remain at right angles, and I was obliged to bend the body forward to preserve the right angle during extension; and, secondly, the extension might have been continued for any length of time, yet the limb would never have been reduced, but by the rotation of the head of the thigh-bone towards the acetabulum.

Mr. William Wickham, of Winchester, had the kindness to send me the following particulars of a case of this dislocation which had been admitted into the Winchester Hospital under the care of Mr. Charles Mayo, one of the surgeons of that institution.

Case LI.—John Norgott, aged forty, was brought to the hospital on the 27th of December 1817, from the neighbourhood of Alton, with an injury of the hip: twelve days had elapsed since the accident without his being aware of the nature of the injury. He reported that whilst riding, his horse had fallen on him in such a manner that one leg was on the horse, whilst his body was in a half-bent position, leaning against a bank. He was of middle stature, but very muscular; the leg was a very little shorter than the other, and but little advancing over it; in

fact, the immobility of the limb was the chief criterion of the dislocation, for the head of the bone was thrown into the ischiatic notch. The mode of reduction was simple: Mr. Mayo had the limb extended by the pulleys, so as to bring the head of the bone to the edge of the acetabulum, over which it was then tilted by a towel, fastened round the patient's thigh and the neck of an assistant. The man remained three or four weeks before he was allowed to leave the house, but on the 4th of February he was discharged cured.

The following case was communicated by Mr. Worts, dresser to Mr. Chandler, surgeon to St. Thomas's Hospital.

Case LII.—James Hodgson, a sailor, aged thirty-eight years, a strong muscular man, was admitted into St. Thomas's Hospital on Tuesday, the 18th of February, 1819, for an injury which he had received in his left hip, his foot having been raised from the ground upon a chest of fruit, when another fell upon his thigh, striking the knee inwards; he fell, and being taken up extremely hurt, he was directly brought to the hospital. Upon examination, I discovered that it was a dislocation of the hip-joint, and that the head of the bone was thrown into the ischiatic notch. The leg was three quarters of an inch shorter than the other, and the foot was inverted: but there existed a considerable power of flexion in the limb. Mr. Chandler saw the case on the 24th, and expressed a wish for Mr. A. Cooper to see it, who, at my request, very kindly did so in the evening, and immediately declared it to be a dislocation into the ischiatic notch. He recommended me to take away blood, which I did the next morning, to the amount of sixteen ounces; this considerably relieved the pain the man had previously suffered, and the tension continued to abate till the 29th, when it was thought sufficiently subsided to justify the attempt at reduction. I accordingly made preparations in the following manner:—at about half-past two o'clock, I took sixteen ounces of blood from the patient, which produced no sensible effect, and in forty minutes I took about twenty-seven ounces more, and while the blood was flowing gave him a grain of tartar emetic; this I repeated till he had taken five grains at intervals of a few minutes, and as he was becoming faint, he was taken into the theatre. I applied the bandages and pulleys to the pelvis and to the knee, bringing the thigh over the other; we kept up

the extension about ten or twelve minutes before we used the strap to raise the head of the bone, and until I thought it had made some progress towards the acetabulum. We then continued the extension, gradually increasing it, at the same time endeavouring to raise the head of the bone and turning the knee outwards, for about fifteen minutes. I had now lost the head of the bone, but still, as it had not made the usual noise in its reduction, I thought it would be wrong to remove the pulleys, as the action of the muscles, if the bone had not been reduced, would have again drawn it up, in which opinion Mr Martin, who assisted me, concurred. The man was now very faint; the extension was therefore continued for about twenty-five minutes longer, when the strap at the knee getting rather loose, we removed the pulleys, upon which it was found that the thigh could now be moved in any direction, and that its position was perfectly natural. The bone was replaced, but at what time it had gained its situation no one could judge, neither could the man describe any feeling that could have indicated it. He was carried to bed in a very faint state.

He had no sickness during or after the extension. I gave him a grain and a half of opium at night, which procured him rest. On the following morning he had some pain remaining, but it was greatly abated, and the thigh could be moved in any direction.

The following case of dislocation into the ischiatic notch on one side, with fracture of the femur on the other, was communicated to me by Mr. Roberts of Dudley.

Case LIII.—On the 18th of June, 1823, I was called to visit Thomas Jaundrill, a very muscular young man, aged twenty-six, who had met with an accident that morning in Tibbington colliery in consequence of a large mass of coals falling upon him. He complained of violent pain in his left hip; the knee and foot were turned inwards; the trochanter was behind its natural position; the limb was firmly fixed; the slightest attempt to rotate it outwards produced excruciating pain, and the thigh could scarcely be bent towards the abdomen. A considerable difficulty in ascertaining the precise nature of the injury arose from the circumstance of there being a severe fracture of the right femur, which deprived me of the advantage of comparing the length of the two limbs. After minute examination, and when I had

consulted your invaluable plates, I was satisfied that this must be a dislocation into the ischiatic notch; but not having seen a case of this species of dislocation, I requested Mr. Badley to visit my patient, and he, on examination, coincided with me in opinion. In the presence, and with the assistance of that gentleman, I proceeded to reduce the dislocation, in the manner directed in Sir A. Cooper's Treatise.

The extension was kept up about four minutes, and while I was thrusting forward the trochanter, I gave orders to an assistant to rotate the limb powerfully and suddenly outwards, when the reduction was immediately effected with a loud snap.

The fractured femur was then set; it speedily united, and in a few months my patient perfectly recovered.

For the following case of double dislocation, with fracture of one acetabulum, I am indebted to Mr. Growse of Bilderton, Suffolk.

Case LIV. — On the 6th March, 1829, I was requested to visit Robert Morphew, a short and rather muscular labourer, æt. twenty-seven, who had received an injury by a tree falling upon his pelvis at the time his body was bent forward in the act of making his escape from it. He directed my attention to his right hip as the seat of pain, accompanied with numbness of the right leg. I immediately detected a dislocation backwards in the ischiatic notch, which was exceedingly well marked, excepting that the limb was an inch longer than the other, which we unfortunately attributed to a contraction of the left knee from a disease of that joint. I requested the assistance of two or three neighbouring practitioners, and by making the extension in the manner directed in your valuable publication, we readily succeeded, accomplishing the reduction in about seven minutes. As my patient seemed unable to quit his room so soon as I expected, I called upon him by appointment on the 26th to assist him in going down stairs, when for the first time my attention was directed to the left thigh, where, to my surprise, I discovered all the symptoms of dislocation on the dorsum ilii. I again summoned my friends, and we all concurred in the nature of the accident. The limb was two inches shorter than the other; the foot and knee were turned inwards; the head of the bone could be felt on the dorsum ilii, and the limb could not be abducted. Immediately having recourse to the usual means of producing

syncope, we placed the patient on his back and made extension across the other thigh about three fourths downwards: the extension was maintained for an hour and a quarter, when the action of the muscles appeared overcome, the limb was the same length as the other, and the trochanter had regained its proper distance from the spinous process of the ilium. Rotation of the limb could now be produced, so that although we did not hear the usual snap accompanying reduction, still we hoped the bone was in the acetabulum; but, however, upon relaxing the extension the bone returned into its unnatural position. Without giving the muscles time to recover their tone, we placed the patient upon his side and resumed the extension as before, and after continuing it for five minutes, a jerk similar to that produced by the return of the head of the bone into the acetabulum was audible to all present, and the patient immediately exclaimed "Thank God, it is in!" Upon loosening the pulleys we were much mortified to find the limb again drawn up. The extension was repeated two or three times, but with the same result; and the patient was aware of the bone leaving the socket as the extending force was removed. If the knee was rotated during full extension by the apparatus an indistinct crackling was heard, not like the crepitus of fracture, but as if the head of the bone were passing over a rough surface. From this sound we determined upon making no further attempt at reduction, but to consult upon the further treatment to be adopted. Our opinion is, that it cannot be a fracture of the neck of the thigh-bone, in consequence of the inversion of the knee and foot, and the force required to restore the natural length of the limb:—that it is not fracture through the acetabulum, as no crepitus is perceptible upon pressure on the crista of the ilium, but that it is fracture of the upper part of the rim of the acetabulum so as to prevent it retaining the head of the bone within its cavity.

A subsequent attempt at reduction was made, but with no better result; and the patient was then sent to St. Thomas's Hospital under the care of Mr. Green, but returned two months after, with the limb in the same state. The man has since continued to enjoy excellent health, has never suffered any inconvenience from the right limb, and is capable of taking active exercise with the assistance of a stick and a well-adjusted shoe on the left foot.

Case LV.—James Grace, æt. twenty-five, a stout muscular man, a brewer's drayman, was admitted into St. Thomas's Hospital on the 9th of February 1830, as a patient of Mr. Travers, under the following circumstances:—He states that whilst employed in moving a cask of beer from his dray, weighing upwards of twelve hundred weight, it slipped from the pulley and struck against his right thigh, which knocked him down, and he fell against the curb-stone upon his left hip. Upon examination, it was found that he was the subject of an oblique fracture of the right thigh, immediately above the condyles. A measurement of the two extremities being taken from the anterior and superior spinous processes of the ilia to the bases of the patellæ, that on the fractured side was found to be eighteen inches, whilst the left measured only half an inch more; but the knee and foot on that side were inverted, with the whole limb more directed inwards than is natural. The head of the left femur could not be felt, but the trochanter was considered to maintain its natural position. Abduction could only be performed with difficulty, and to a small extent; and on endeavouring to produce abduction of the limb, or rotation outwards, a sudden check was perceived. Flexion could be easily produced to nearly a right angle with the trunk without causing pain; but when carried to a greater extent he expressed considerable suffering, and referred it to the back part of the thigh underneath the glutæi muscles. There was no pain on the anterior part of the limb, but a considerable and unusual depression was obvious in the groin. On the day after his admission he had twenty-five leeches applied around the hip-joint, which afforded considerable relief. On the 12th the fractured limb was firmly bound up in short splints, twenty ounces of blood were abstracted from the arm, and the patient taken into the operating theatre for the purpose of reducing the dislocation; a consultation having been previously held by the surgeons of both hospitals, and after a deliberate examination, all agreed that the head of the femur was lying in the ischiatic notch. To effect the reduction, the patient was placed on the table, lying on his right side, with the dislocated limb bent across the right thigh, and a girth passed between the perinæum and limb for the purpose of fixing the pelvis. A wetted roller was then wound around the thigh just above the knee, and a leather pad fastened over it, to which the pulleys were affixed in the usual manner.

Extension was now steadily kept up for about twenty minutes, and the head of the bone at the same time was attempted to be brought towards the acetabulum by a round towel, which was placed under the upper part of the thigh. At this time the circular pad around the knee gave way, but was immediately replaced by another; and during the second extension twelve ounces more of blood were taken from the arm, which produced a considerable depression, approaching fainting. Abduction was then tried, at the same time the limb was raised and rotated outwards. Finding all these attempts ineffectual, extension was again made, and more forcibly applied than hitherto for half an hour, when the pulleys were again loosened, and abduction and rotation again tried. The toes could now be everted; but there still seemed to be a check when the limb was abducted. The pulleys were therefore once more had recourse to, and extension kept up for another quarter of an hour, when, upon being relaxed, it was found that every natural motion of the joint was easily effected, leaving no doubt that the head of the bone was restored to its natural position, although it had not been indicated by any sudden snap or motion of the limb. During the time the patient was on the table he took nine doses of the solution of the tartarized antimony, each containing a grain of antimony, but which did not produce vomiting until he was placed in bed, when it operated freely. The time occupied in the reduction was very nearly two hours.

The patient had some sloughing of the scrotum, and a slight attack of delirium tremens, from which, however, he recovered by the 26th; but at this period nothing like consolidation of the fractured thigh could be discovered.

SECTION V.

DISLOCATION ON THE PUBES.

This dislocation is more easy of detection than any other of the thigh.

CAUSE.—It happens when a person, while walking, puts his foot into some unexpected hollow in the ground; and his body at the moment being bent backwards, the head of the bone is

thrown forwards upon the os pubis. A gentleman who had met with this dislocation in his own person, informed me that it happened whilst he was walking across a paved yard in the dark: he did not know that one of the stones had been taken up, and his foot suddenly sunk into the hollow, and he fell backwards. When his limb was examined, the head of the thigh-bone was found upon the os pubis.

Symptoms.—In this species of dislocation the limb is an inch shorter than the other, the knee and foot are turned outwards, and cannot be rotated inwards, but a slight power of flexion forwards and outward still remains; and in a dislocation which had been long unreduced, the motion of the knee backwards and forwards was full twelve inches; but the striking criterion of this dislocation is, that the head of the thigh-bone may be distinctly felt upon the pubes, above the level of Poupart's ligament, on the outer side of the femoral artery and vein; and it feels as a hard ball there, which is readily perceived to move on moving the thigh.

Although this dislocation is apparently easy of detection, I have known three instances in which it was overlooked, until it was too late for reduction: of one there is a preparation at St. Thomas's Hospital; another occurred to a gentleman from the country, in whom it was not discovered until some weeks after the accident, who then submitted to an extension which did not succeed, and came to London to ask my opinion, when I advised him against a further attempt, to which indeed he himself was disinclined. The third, was a patient in Guy's Hospital, who was admitted for an ulcerated leg, and found to have a dislocation upon the pubes, which had happened some years before. It really must be great careless-

ness which leads to this error, as the case is so strikingly marked.

Dissection.—I dissected the first of these dislocations, and it is preserved in our anatomical collection. It shows changes of parts nearly equal to those of the dislocation into the foramen ovale. The original acetabulum is partly filled by bone, and partly occupied by the trochanter major, and both are much altered in their form. The capsular ligament is extensively lacerated, and the ligamentum teres is torn through. The head of the thigh-bone had torn up Poupart's ligament, so as to penetrate between it and the pubes. The head and neck of the bone were thrown into a position under the iliacus internus and psoas muscles, the tendons of which, in passing to their insertions over the neck of the bone, were elevated by it, and put on the stretch. The crural nerve passed on the fore part of the neck of the bone upon the iliacus internus and psoas muscles. The head and neck of the thigh-bone were flattened, and much changed in their form. Upon the pubes a new acetabulum is

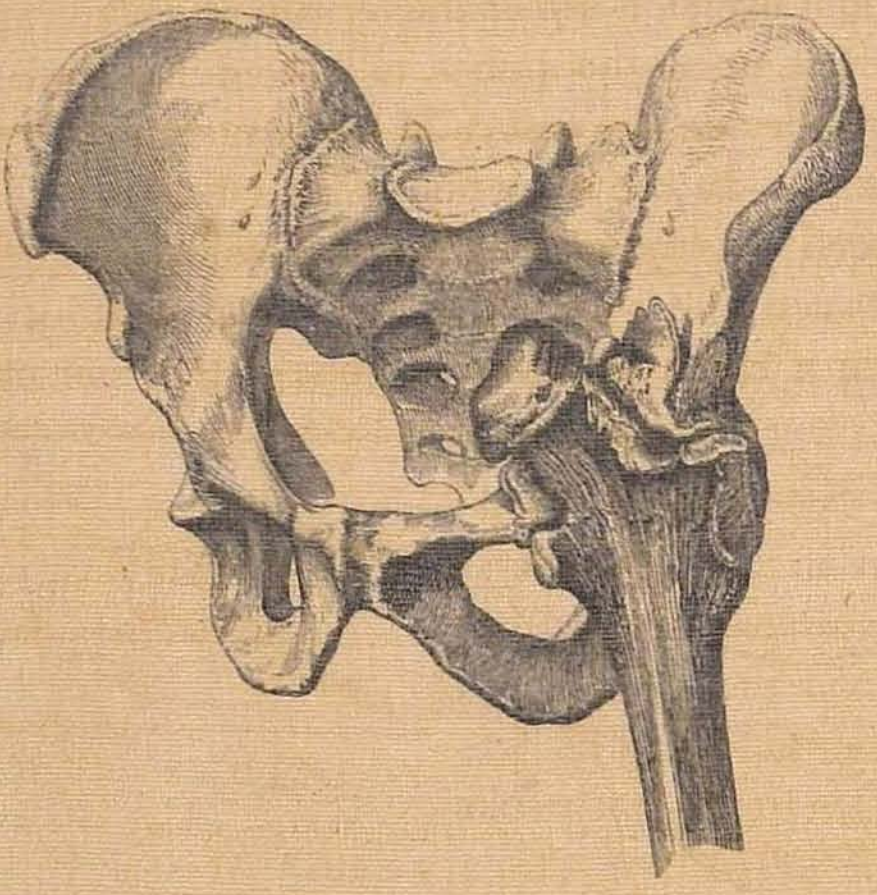

formed for the neck of the thigh-bone, the head of the bone being above the level of the pubes. The new acetabulum extends upon each side of the neck of the bone, so as to lock it laterally upon the pubes. Poupart's ligament stretched across it on the fore part, whilst the femoral artery and vein were placed

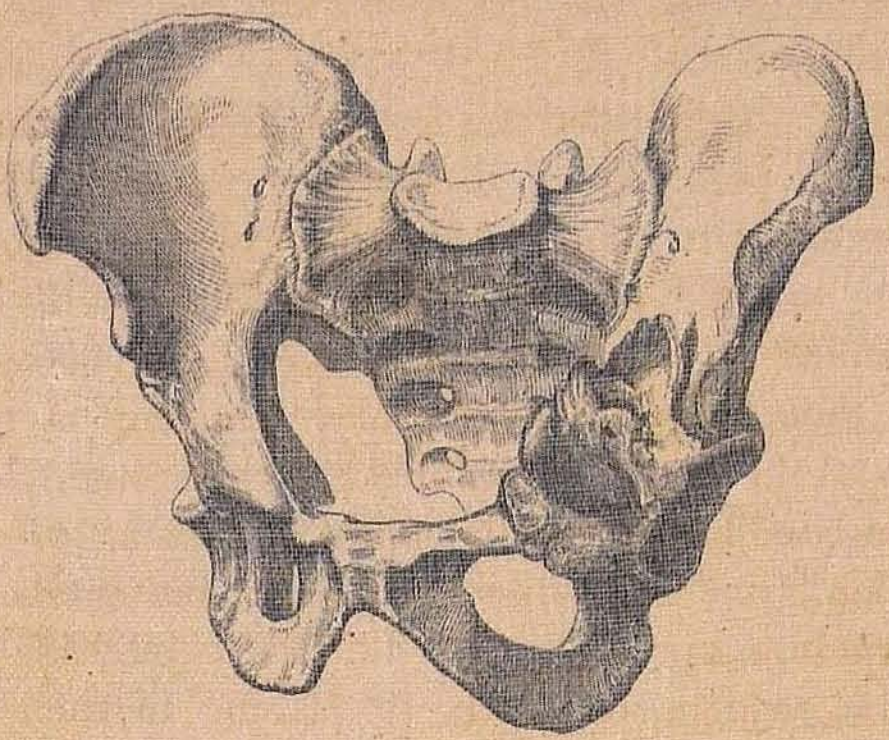

on its inner side, so that the head of the bone rested between the crural sheath and the anterior and inferior spinous process of the ilium.

DIAGNOSIS.—This accident might, by an inattentive observer, be mistaken for a fracture of the neck of the thigh-bone, as shortening and eversion are characteristic of each; but the head of the bone felt upon the pubes, and the diminished mobility of the joint, will decide the nature of the accident.

TREATMENT.—In the reduction of this dislocation, the patient is to be placed on his sound side on a table; a girth is to be carried between the pudendum and inner part of the thigh, and fixed in a staple a little in front of the line of the body.

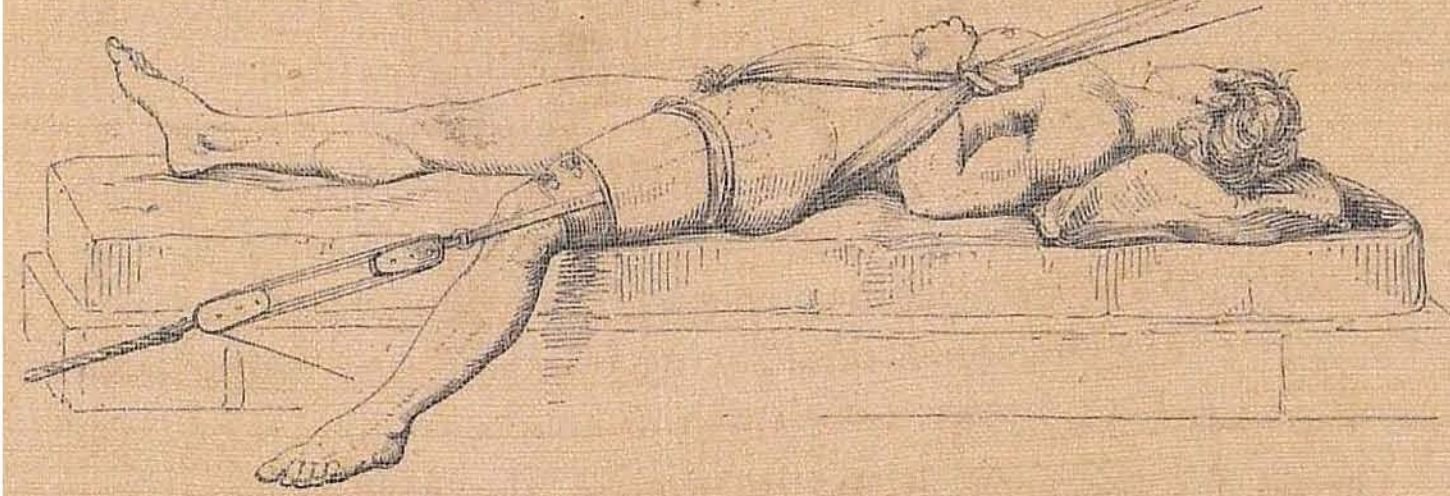

The pulleys are fixed above the knee, as in the dislocation upwards, and then the extension is to be made in a line behind the axis of the body, so as to draw the thigh-bone backwards. After

this extension has been for some time continued, a towel is placed under the upper part of the thigh, and an assistant, pressing with one hand on the pelvis, lifts the head of the bone, by means of the towel, over the pubes and edge of the acetabulum.

The following case, which occurred in Guy's Hospital, at the time when my friend Dr. Gaitskill of Bath was dresser to Mr. Forster, will best exemplify the mode of reduction. He was a dresser in the years 1803 and 1804.

Case LVI.—A. B. was admitted into Guy's Hospital, under Mr. Forster, with a dislocation of the os femoris upon the pubes.

The length of the limb was somewhat diminished; the foot and knee were turned outwards; but the circumstance which more clearly evinced the nature of the accident was, that the head of the thigh-bone could be distinctly perceived under the integuments near the groin, where its shape could be ascertained, as well as its motion felt, when the thigh was moved. The accident had happened from a slip or fall he had sustained about three hours before.

With respect to the reduction:—As the man was brought into the hospital in the evening, when Mr. Forster was absent, I considered it to be my duty to attempt to replace the bone immediately. I therefore ordered the patient to be carried into the operating theatre; whilst this was doing, I invited my three brother dressers into the surgery, informed them of the accident, and, to avoid confusion, requested each to take some particular part in the process of reduction. The patient was placed on his sound side on a table, the pulleys were applied to the thigh in the usual manner, and extension was begun in a straight line, with the design of raising the head of the bone into its socket, but without success. Reflecting then a moment on the mechanism of the bones, and their new relative situation, I changed the line of extension to a little backwards and downwards, and passing a towel over my own shoulders, and under the superior part of the man's thigh, raised it by extending my body. The leg being kept bent, as from the beginning of the operation, nearly to a right angle with the thigh, I requested one of the dressers to take hold of the ankle and raise it, keeping the knee at the same time depressed, by which means the thigh was turned over inwards, and in a very short time the head of the bone snapped into its acetabulum.

The following case was admitted into St. Thomas's Hospital, under the care of Mr. Tyrrell, surgeon to that institution.

CASE LVII.—Charles Pugh, aged fifty-five, a cooper, about the middle size, on the evening of the 23rd of January, while standing at the corner of a street, was struck on the back part of the right hip by the wheel of a cart, which knocked him down. He was taken up by some persons passing, who, finding that he was not able to walk, took him to St. Thomas's Hospital. The accident happened about nine o'clock in the evening, and I was sent for between twelve and one o'clock, when I found a dislocation of the right femur on the pubes, the particulars of which were as follow.

The head of the bone could be distinctly felt below Poupart's ligament, immediately on the outer side of the femoral vessels. The foot and knee were turned outwards, with very little alteration in the length of the limb. The thigh was not flexed towards the abdomen, and almost immovable, admitting only of partial adduction and abduction. The limb could be rotated outwards, but not at all inwards. I immediately had the man taken into the operating theatre, and speedily succeeded in reducing the dislocation by the following means:—The patient was placed on his left side, a broad band was passed between the thighs, and, being tied over the crista of the ilium on the right side, was made fast to a ring fixed in the wall. A wet roller having been put on above the right knee, a bandage was buckled over it, and its straps attached to the hooks of the pulleys, by which a gradual extension was made, drawing the thigh a little backwards and downwards. When this extension had been kept up a short time, I directed another bandage to be applied round the upper part of the thigh, close to the perinæum, by means of which the head of the bone was raised, and in the course of a few minutes the reduction was easily accomplished. The patient had not been bled, or taken any medicine; he suffered but little after the reduction, and was able to walk without pain or inconvenience five or six days afterwards. On the day following the accident he could move the limb freely in all directions without pain, but did not attempt to walk until the period I have mentioned.

CASE LVIII.—William Bennett, æt. thirty-six, a healthy but not very muscular man, was admitted December 26, 1831, into

Guy's Hospital, under the care of Mr. Morgan. He says that he was knocked down by a cab, which struck his left arm and hip while in the act of crossing the street. Upon examination an oblique fracture of the upper third of the humerus was discovered, and a dislocation of the left femur on the pubes. The diagnostic marks of the dislocation were plain; the head of the bone could be felt on the pubes, pressing Poupart's ligament upwards, *and was placed upon the femoral artery so as to stop the pulsation*; while the pressure at the same time upon the anterior crural nerve produced numbness of the thigh. The projection of the trochanter major was entirely lost, and the whole limb everted and shortened one inch and a half. The limb admitted of slight flexion and extension, but no rotation. The patient was bled to sixteen ounces, and solution of tartarized antimony administered until nausea was produced, in which state he was carried to the operating theatre. He was placed upon his sound side, and the extension was made in the direction of the dislocated limb downwards and a little backwards. In about a quarter of an hour the head of the bone moved from its new situation, so as to admit of the return of the pulsation of the artery, and then appeared to be stationary for the next half hour, during which rotation was frequently employed, and an attempt was also made to draw the head of the bone outward and forward by means of a round towel; but as these means failed, notwithstanding the muscles seemed perfectly wearied by the continued extension, the apparatus was removed, and the patient was placed on his back so as to bring his pelvis quite to the edge of the table, and the knee of the dislocated limb was forcibly pushed backwards in the direction under the table for the purpose of thrusting the head of the bone forwards, and at the same time the limb, being strongly adducted, the head of the bone snapped into the acetabulum.

The fracture of the humerus was treated in the usual way, and the patient perfectly recovered.

Case LIX. — The particulars of the following case were sent to Mr. Bransby Cooper by his friend and pupil, Mr. Holland, of Manchester.

William Gee, æt. twenty-nine, a stout strong man, employed as a brewer's porter, while driving a cart was struck down by a blow on his head from a form which was in the cart, and, when lying prone on the ground, the wheel passed over the back of his

right thigh, his foot being at the time turned outwards. I saw him about two hours after the accident, when the following indications of dislocation of the femur in the pubes were apparent. The mobility of the joint was lost, the limb was an inch shorter, the thigh flexed, slightly abducted, and rotated outwards; and the head of the femur, notwithstanding the stoutness of the patient, could be distinctly felt in the groin, obedient to the rotatory motions of the limb. I directed the patient to be given small but repeated doses of tartarized antimony until nausea was produced, during which extension was made in the direct line of the body for about ten minutes, but without success. I then altered the direction, making the line of counter-extension pass just before his chest, while the extension was made downwards and backwards. The reduction was thus effected, the head of the femur slipping into the acetabulum with an audible snap. No inflammation followed of any consequence; he occasionally suffers a little pain, but the hip is as strong as ever.*

CASE LX.—William Pridden, aged twenty-five years, a stout muscular young man, was brought to Guy's Hospital on the 7th of August 1831, having fallen into a cellar on that morning. Upon examination, Mr. Callaway found that the right limb was nearly an inch shorter than the other, the knee and foot turned outwards, and the head of the bone could be most distinctly felt, and formed a considerable prominence at the groin. The slightest motion of the limb occasioned great pain, particularly when any attempt was made to bring the knee towards the opposite. The reduction was conducted in the usual manner, by fixing the pelvis with the bandage around it, and extending backwards and downwards. After having kept up the extension with the pulleys for twenty minutes, finding that the muscles were much relaxed, and that the obstacle to the reduction appeared to be the difficulty in tilting the head of the bone from the pubes, the bandage around the thigh not being sufficient in this case for that purpose, the patient was brought to the edge of the table, and, by a forcible depression of the limb, it slipped into the acetabulum

* The extension and counter-extension in the first instance being in the direct line of the body, instead of forming an acute angle with it, prevented the force acting upon the head of the bone so as to lift it from the pubes, and the ready reduction of the dislocation on the adjustment of the apparatus, as directed by Sir Astley Cooper, offers an excellent illustration of the efficacy of his directions. —*Ed.*

with considerable noise: the extension in this case was kept up for nearly half an hour.

He had been bled to thirty ounces, and took three grains of tartar emetic during the time he was on the table, in four doses. He left the hospital perfectly well the following week.

CASE LXI.—William Rozzle, æt. seventeen, a healthy boy, was admitted into Guy's Hospital, 23rd of June, 1834, under the care of Mr. Bransby Cooper, in consequence of an injury to his right hip. He stated that, while driving a waggon the day before, in the attempt to kick a stone out of the way of the wheel-horse, the wheel of the waggon caught his left foot, forced him to the ground, and passed over his right hip. On attempting to rise he found himself incapable of doing so, and was therefore immediately carried into a house, where in about an hour's time he was seen by two medical men, who immediately discovering a dislocation of the hip, bled him largely, and attempted the reduction by the use of the pulleys. They kept up extension for half an hour, without success, and then desisted from any further attempt. An hour after another surgeon made a similar unavailing attempt for twenty minutes, and then sent him to Guy's Hospital. Mr. Cooper saw him about an hour after his admission, and first examined him while he was lying in bed. The injured limb was abducted and everted, and appeared shorter than the other, although it was difficult to appreciate the degree of shortening from the impossibility of bringing the limbs parallel with each other. The head of the femur could be distinctly felt in the right groin, and, what is very unusual, was placed to the inner side of the femoral vessels. Rather an extensive lacerated wound was situated just below Poupart's ligament, a little to the inner side of its centre, which appeared as if it had been caused by his body being forced against the ground by the weight of the waggon passing over him. He had passed his water and his motion since the accident, neither of which were tinged with blood, and as there was no indication of any serious internal injury, Mr. Cooper directed that he should be again bled, that tartarized antimony should be administered, and while in a state of approaching syncope had him removed into the operating theatre. The extending and counter-extending forces were applied, as directed by Sir Astley Cooper; namely, the patient was placed upon his sound side, the counter-extending force being carried

just over the right shoulder, passing in front of the patient's face, while the extending force was applied so as to extend the limb in a direction downwards and backwards; and the extension being kept up steadily for twenty-five minutes, the head of the bone slipped into the acetabulum. The patient was immediately placed in bed, and described himself as feeling perfectly easy.

The injury inflicted on the parts adjacent to the hip-joint, as well as on the ankle, proved too great for the boy's constitutional powers to repair. It is unnecessary, however, to detail the daily reports of the case; and it may be deemed sufficient to state, that the supervening symptoms may be divided into four stages. In the first, including three days, the 23rd, 24th, and 25th, he complained of considerable pain, attended with swelling about the hip and tenderness of the injured limb; there was also a thin bloody discharge from the wound in the groin, accompanied by the usual symptoms of irritative fever, with slight rigors. The treatment consisted of poultices applied to the groin and ankle, and laxatives, diaphoretics, and slight tonics. The second stage, occupying the 26th, 27th, and 28th, was marked by the establishment of a copious and more favourable suppuration, the pus seeming to proceed from the spot where the head of the bone had been placed; there was also some remission of the febrile symptoms, and, in fact, a general improvement in the state of the boy's health. The swelling of the ankle had now sufficiently subsided to admit of a fracture of the fibula being detected. At this time calomel and opium were added to the remedies already mentioned, and a splint was applied on the outer side of the left leg; a pad of lint was also placed upon the abscess in the right groin, in the hope of diminishing the cavity by constantly pressing out the matter.

In the third stage, the discharge became thin, unhealthy in appearance, and very abundant; the patient fell into a state of low fever, marked by a great prostration of power; the tongue became dry and furred, the pulse small and rapid, the skin hot and dry, the bowels inactive, and the mind wandering; and sometimes he might be described as being in a state of coma. Dr. Bright was now requested to visit him, and serpentaria, ammonia, and tincture of opium were ordered, with a diet of beef-tea and porter; for the indications of treatment were now evidently, by all possible means, to support the failing

strength. Thus he proceeded until the 5th of July, when he was allowed four ounces of brandy daily, which appeared to revive him, and his pulse improved. On the 7th his bowels became relaxed and his powers again flagged. On the 8th he passed a large worm, of the lumbricus teres species, by the mouth, and appeared in every respect decidedly worse. The discharge had changed its appearance, and now consisted almost entirely of blood, which did not form a firm coagulum, but a soft, jelly-like, dark-coloured mass: the integuments about the groin became discoloured, and the odour emitted was excessively offensive; the pulsation was scarcely perceptible at the wrist, and he had all the appearance of a dying man. He, nevertheless, continued to take nourishment, and lingered until the morning of the 11th, when he expired.

Post-mortem examination.—The body being placed upon the table, it appeared much emaciated, and emitted a most putrid odour. On opening the chest the lungs appeared pallid, but otherwise healthy. On removing the integuments of the abdomen there was found a sloughing of the tendon of the external oblique muscle, with subcutaneous ecchymosis extending into the right lumbar region. There was also slight ecchymosis under the tendon of the external oblique, implicating the structure of the spermatic cord. Upon examining the seat of injury it was found that the head of the femur had been thrown to the inner side of the femoral vessels and produced an enlargement of the absorbent gland in the course of the external iliac vein; a sinus was also found extending from the external wound into the pelvis to the obturator muscle in one direction, and between the bladder and pubes to within half an inch of the median line in another. The pectineus muscle was completely torn through just at its origin; the adductor longus was remaining, attached at its origin and insertion, but very nearly torn through in its middle third, just where the obturator nerve enters it; the upper part of this muscle was much ecchymosed. The head of the bone had passed above the internal circumflex artery. The inferior glutæal and sciatic nerves were entire. The cutaneous surface of the glutæus maximus muscle was healthy, but the aponeurosis covering the glutæus medius was ecchymosed, and its tendinous insertion was much lacerated, being entirely detached from the trochanter major; the periosteum, and, indeed, a small

lamina of the bone itself, was attached to it. The superior glutæal nerve was not injured. The gemini and half of the quadratus femoris muscles were detached from their insertion; the tendon of the pyriformis was also partly lacerated, but adherent to the tendon of the gemini and obturator internus. The adductor magnus muscle was ecchymosed and softened, but not torn; the obturator externus entire. The capsular ligament was torn through posteriorly, so as to expose the head of the femur and part of the acetabulum, with the cotyloid ligament. A portion of the edge of the acetabulum, for about an inch, with its cotyloid ligament, was detached. The posterior margin of the extensor vaginæ femoris was sloughy; sinuses extended from the anterior to the posterior surface of the joint. In the interior of the pelvis blood was found effused beneath the internal iliac muscle, and the inner aspect of the adductor brevis muscle was sloughy, the psoas parvus uninjured, as well as the origin of the pyriformis. The anterior part of the capsular ligament, where covered by the tendons of the psoas and iliacus muscles, was the only part not torn through. The ligamentum teres was torn from the head of the femur and sloughy, and the head of the bone at the anterior and inner part absorbed. The epiphyses quite loose, but the cartilage of the acetabulum was not ulcerated, although there was a slight change from the ulceration of the ligamentum teres. The trochanter major was still attached to the shaft of the femur by epiphysis.

The details of this case prove, that the dissolution of the patient was attributable partly to the extent of injury inflicted upon the soft parts by the heavy waggon, and the distance to which the head of the bone was thrown from the acetabulum; partly to the repeated bleedings and the attempts at reduction.

Case LXII.—Edward Micklam, æt. nineteen, a sailor, was admitted into St. Thomas's Hospital, November 7th, 1832, labouring under an old standing dislocation of the femur on the pubes; the symptoms that presented themselves were as follows:—The limb (right) was an inch shorter than the other, the foot turned outwards, and a prominence in the groin easily discerned as the head of the bone; the thigh might be rotated slightly outwards, but resisted any attempt to turn it inwards. He states, that on the 26th of April (more than six months

previous to his admission), he fell from the deck of his ship into the hold, a distance of about twenty feet, and in the fall struck his head several times and his hip against a projecting coil of the chain cable, which was lying rolled up in the hold. He was not stunned, but found himself incapable of raising himself up. There being no surgeon on board, he was allowed to remain at rest for the space of eight weeks. He then began to make an attempt to walk about, which attempt caused him excessive pain in the groin. In August he returned to England, and was admitted into the Westminster Hospital, where several attempts were made for the reduction of the displaced bone without effect. No attempt was made at this hospital, and, after remaining some little time, he, according to his wish, was discharged. There was considerable lameness, but he was enabled to walk some distance with tolerable ease, merely assisted by a stick.

The following interesting case of compound dislocation of the femur was communicated to me by my former pupil, Dr. Walker, of Charlestown, near Boston, in North America.

Case LXIII.—The patient, while driving a waggon laden with many tons weight of manure, seated upon the "spine," received a blow which threw him upon the ground, and, as he describes, resting upon his elbows and knees. In this position the waggon passed over the posterior part of his pelvis and right thigh, forcing the head of the femur out of the acetabulum forwards upon the groin, lacerating the soft parts and pressing the head through the integuments. This was, in fact, the state of things when I was called to him. The man was extremely muscular, and having been drinking freely, though not to intoxication, his muscles were greatly agitated. He was restless, and complained of great suffering: the diagnosis was extremely easy, every symptom of dislocation on the pubes being present. By the concurrent advice of my friend Dr. Shurtleff, in whose service the patient had received the injury, I proceeded to make an immediate effort at reduction, in the manner directed in your inestimable treatise, excepting that, having no pulleys, we availed ourselves of manual assistance. The efforts at reduction produced great suffering, but did not succeed in removing the head of the bone from its new situation, notwithstanding the extension was made by several strong men, and in a variety of directions. Foiled in my first attempt, I placed

the patient in bed, had him largely bled, and gave him a powerful dose of laudanum. Early the next morning I visited him, and found him calm, free from pain, and evidently under the influence of opium, and in every way well fitted for a further attempt at reduction, which I determined upon attempting with the use of the pulleys. My friend, Dr. William Ingalls, who was now present, requested he might be first allowed to make an effort without the pulleys, and, to my astonishment, he succeeded in replacing the head of the bone in the acetabulum in the following manner. By his direction an assistant, taking the ankle of the dislocated limb in his right hand and placing his left in the ham, bent the leg at right angles upon the thigh, and the thigh upon the pelvis, then lifting with a power little more than sufficient to elevate the whole limb, he carried it to its greatest state of abduction, at the same time rotating the femur inwards while Dr. Ingalls passed his thumbs through the wound, and pressing upon the head of the femur directed it towards the acetabulum. At this moment he directed the limb to be forced towards its fellow, by which the reduction was effected with the greatest ease and elegance. Whether the same manner would succeed in other luxations upon the pubes I know not, but here I state facts. I regret to add, that extensive suppuration proved fatal to our patient at the end of about three weeks. This and one other luxation of the femur on the dorsum ilii are the only cases which have occurred to me in fifteen years; in that backwards I used the pulleys, as advised in your Treatise, and succeeded in the reduction with the greatest ease.

From what I have had an opportunity of observing on the subject of dislocations, I believe that the relative proportion of cases will be in twenty as follows:—*twelve* on the dorsum ilii; *five* in the ischiatic notch; *two* in the foramen ovale; and *one* on the pubes.

The cases I have here detailed, with the dates at which they were presented, manifest the frequent occurrence of this accident to the thigh. How it escaped the observation of surgeons of eminence of former times, is a matter of surprise that can only be accounted for by the difficulties which then existed in the pursuit of anatomy, and more especially of morbid anatomy; and it is a curious circumstance, that Mr. Sharpe, formerly surgeon

of Guy's Hospital, author of a Treatise on Surgery, and in many respects an excellent surgeon, who had a large share of the practice of this metropolis, did not, as I was informed by Mr. Cline, believe that a dislocation of the thigh-bone ever occurred.

It is gratifying to observe the advancement of knowledge in the profession at the present period, compared with that of fifty years ago. What should we think of a surgeon of the present day, with all his opportunities of seeing disease in the large hospitals of this city, who doubted the existence of a dislocation of the thigh, when we find that our provincial surgeons immediately detect the nature of these injuries, and generally succeed in their attempts to reduce them? Let it never be forgotten, however, that it is to the knowledge of anatomy, and more especially of morbid anatomy, that we are indebted for this superiority.

The following case, which has recently appeared in one of the Medical Journals, from Mr. Cornish, surgeon at Falmouth, I have thought proper to subjoin, though I must observe, that there is reason to suspect some mistake in the relation, not of the narrator of the case, but of the man himself, as I have carefully examined the books of both hospitals at the period specified, and can find no such name.

Case LXIV.—In 1812, MacFadder, a seaman, about twenty years of age, in coming up from Greenwich to London on the outside of one of the stages, fell from the coach and injured his hip. He was carried to St. Thomas's Hospital, and became Mr. Cline's patient. His case was treated as fracture of the neck of the thigh-bone. Having, after the lapse of some months, experienced no relief from the means that were adopted, he was dismissed, with the assurance that the limb would be useless to him as long as he lived.

The man was subsequently taken into Guy's Hospital. Sir A. Cooper, whose patient he became, thought that the head of the femur was out of the socket; and after bleeding him, putting him in the warm bath, and administering nauseating doses of tartrate of antimony, endeavoured to reduce the dislocation. The attempt was unsuccessful, as were also others that were afterwards made, and he was again dismissed an incurable cripple.

In 1813, about twelve months after the accident, the man pre-

sented himself on crutches at the Falmouth Dispensary, when he gave me the foregoing history of his case. On examining him, I found the injured limb about two inches and a half shorter than the other, entirely useless, producing great pain on bringing it to the ground, and the knee and foot turned inwards. There was considerable distortion about the joint; and the head of the bone appeared to have formed a bed for itself among the muscles on the dorsum ilii. In short, he had every diagnostic symptom of the dislocation upwards.

In consequence of the duration of the accident, and the failure of the attempts at reduction under the management of Sir A. Cooper, I considered his case a hopeless one, and therefore did nothing for him.

In March 1818, I met the man carrying a heavy basket on each arm, and walking without the slightest degree of lameness. Although I intimately knew his person, having seen him on crutches about the town for two or three years, I passed him, hardly believing it within the compass of possibility, that he could be my lame patient; but after having walked twenty yards or more, I ran back after him to ascertain the fact. On satisfying myself of his identity, and inquiring into the cause of his cure, he informed me, that in the summer of 1817, *five years after the accident*, whilst on a passage from Falmouth to Plymouth, in a little coasting vessel, "the ship made a lurch," by which he was thrown out of his berth. At the moment he fell, he heard a loud crack in his hip, and from that time he put aside his crutches, and recovered the perfect use of his limb. The man is now doing duty, as an able seaman, on board a ship which trades from this port to London.

The practical importance of this case is not, perhaps, equal to the curious character of its termination. "It proves," says Mr. Cornish, "the possibility of reducing a displaced joint, even after the lapse of years, when every impediment to reduction may be fairly supposed to exist (particularly the obliteration of the acetabulum), and when most surgeons would judge the attempt hopeless; and it serves to illustrate the proposition, that a slight effort when the muscles are unprepared, will succeed in reduction of dislocation, after violent measures have failed."

SECTION VI.

ANOMALOUS DISLOCATIONS OF THE HIP-JOINT.

The account that I have given of the four positions in which the head of the thigh-bone is thrown in dislocations of the hip-joint, I am fully confident is justly formed from accurate observation in practice, and borne out by the anatomy and physiology of the structures of the articulation. But I do not mean to aver that circumstances cannot exist which may alter the usual conditions of these dislocations; and indeed I shall quote some exceptions to the rule, and explain the causes which are liable to produce the deviation, and render it possible for the head of the thigh-bone to be thrown in other positions than those which I have detailed.

There seems something a little anomalous in the frequency of the dislocation of the femur upwards and backwards upon the dorsum of the ilium, for upon examination of the hip-joint it will be found that it is the direction of all others in which there seems to be the greatest protection against dislocation, the capsular ligament being there the strongest, the edge of the acetabulum the most elevated, and the ligamentum teres offering the greatest hinderance to displacement in that direction. There is comparatively a much greater apparent facility to the dislocation into the forāmen ovale, for the under and inner part of the acetabulum is partly formed of fibro-cartilage; the capsular ligament is much thinner here than at the upper part; and the ligamentum teres does not offer the same resistance to the displacement in this direction that it does to that over the upper part of the cotyloid cavity.

With respect to the fixed position of the head of the femur in the four dislocations which have been described, it is not to be considered as a mere matter of chance, but as the natural result of the influence of the muscles which draw the bone into these positions, and that therefore under common circumstances the condition is inevitable. But on the other hand, when fracture of bone occurs at the same time with dislocation, as in Case LXVIII., or when collapse from any cause is present, as in Case LXX., it may then happen that the mere physical force which drives the

head of the bone out of its socket may place it in some other position, which it maintains either from a portion of broken bone resisting its being acted upon by the muscles, or from the muscles themselves having lost all power. It is, then, under these circumstances, and these alone, that such deviations from the usual positions of dislocation can take place, as the ensuing cases will exemplify.

The following case was communicated to me by Dr. Cummins, and is published in the third volume of the Guy's Hospital Reports.

Case LXV.—Thomas S., a carter, about fifty-five years of age, of relaxed and spare habit, on the night of January 8th, 1830, was proceeding homeward in a state of inebriation, when he, unawares, stepped over the side of the road and fell into the adjoining field, which was several feet below the level of the former. On recovering from the shock he was unable to rise, and was conveyed home by some friends. A surgeon saw him about four hours after the accident took place: he found the right hip-joint much swelled and ecchymosed, which, with the intoxicated state of the patient, contributed to prevent his ascertaining the exact nature of the injury. On the 11th, the late Mr. Gibson of New Lanark, with whom I then resided as assistant, saw the patient for the first time; but from the unusual nature of the symptoms, hesitated in his opinion whether the case was one of dislocation of the joint, or fracture of the neck of the femur. On the 17th, the antiphlogistics previously employed having produced considerable abatement of the tumidity, Mr. Gibson thought that the bone was dislocated, and that an attempt might be made to reduce it. Extension by means of the compound pulley was kept up during nearly the space of an hour, while attempts were made to effect the restoration of the joint to its natural state, but they proved ineffectual. The want of success induced Mr. Gibson to doubt the correctness of the opinion which he had formed.

Next day, 18th, being the tenth from the occurrence of the accident, Mr. Gibson took me to see the case, when I found the symptoms as follows, and was informed that they were the same from the first, excepting the diminution of the general tumidity.

The right limb was shortened by fully three inches, and it could not be lengthened in any degree. The knee and toes

were very much turned out, and the attempt to rotate the thigh inward produced exquisite pain, without producing any change in the position of the limb. Abduction and adduction were nearly equally difficult and painful, but flexion could to a certain extent be performed with less difficulty. The hip was flattened, and the trochanter major not to be discovered. There was no hard or distinct tumour on the pubes; but close below the anterior superior spine of the ilium, between it and the situation of the inferior, there was a very distinct hard round tumour, which could be felt moving in unison with the thigh when flexion and extension were performed. There was no crepitus, no possibility of lengthening the limb, and, of course, no successive retraction on the removal of the extending force, as takes place in fracture of the neck of the thigh-bone. The tumour at the anterior superior spine was fixed in its relative position; and between its most prominent part and the point of the spine the distance was only a few lines, and nearly in the perpendicular, as it projected but little into the abdomen.

My opinion being requested, I stated that the case was one of dislocation; that I was satisfied that the tumour, situated immediately under the anterior superior spine of the ilium, was formed by the head of the femur; and that, in consequence, the neck of the bone and trochanter major lay on the contiguous portion of the dorsum ilii, above the acetabulum. It was objected, that such a position of the bone was anomalous and unprecedented; and that if the head of the femur were so dislocated, it was unlikely it would remain in that situation on the sharp ridge of the ilium. However, on returning home and explaining my ideas at length, and placing the dry bones in the same position as they were supposed to occupy in the case, Mr. Gibson was entirely convinced, and we agreed that the reduction ought to be attempted by extending the joint in a direction downward and backward, raising the head of the bone, and rotating the knee inward, so as to turn the head of the bone into the acetabulum.

On the 19th, a grain of tartar emetic having been previously administered at short intervals till sickness and vertigo came on, the extension, by means of pulleys, was gradually increased. Mr. Gibson, having a towel passed under the patient's thigh and over his own shoulder, raised the head of the bone, which now left its position at the anterior superior spine, and gradually

came down, and then turned the knee firmly inward, at the same time pressing it towards the opposite one. The head of the bone glided into the acetabulum without any sound or snapping; the fact being only with certainty ascertained by our finding the prominence of the trochanter returned to its proper situation, the tumour which was formerly at the anterior superior spine entirely removed, the knee and foot in their proper direction, and the limb of equal length with the other. The extending apparatus was removed, the patient's knees bound together, and he was placed in bed. In a fortnight he was sufficiently restored to be able to walk a short way out of doors, and soon entirely recovered from the effects of the injury. The reduction was effected in about twenty minutes.

The accompanying sketch shows the position of the dislocated head of the bone, which lay between the anterior superior and anterior inferior spinous processes of the ilium; the neck of the bone, at its junction to the head, resting on the ridge between these points; while the trochanter major rested on the dorsum ilii, above the acetabulum; thus indicating a variety of dislocation hitherto unknown.

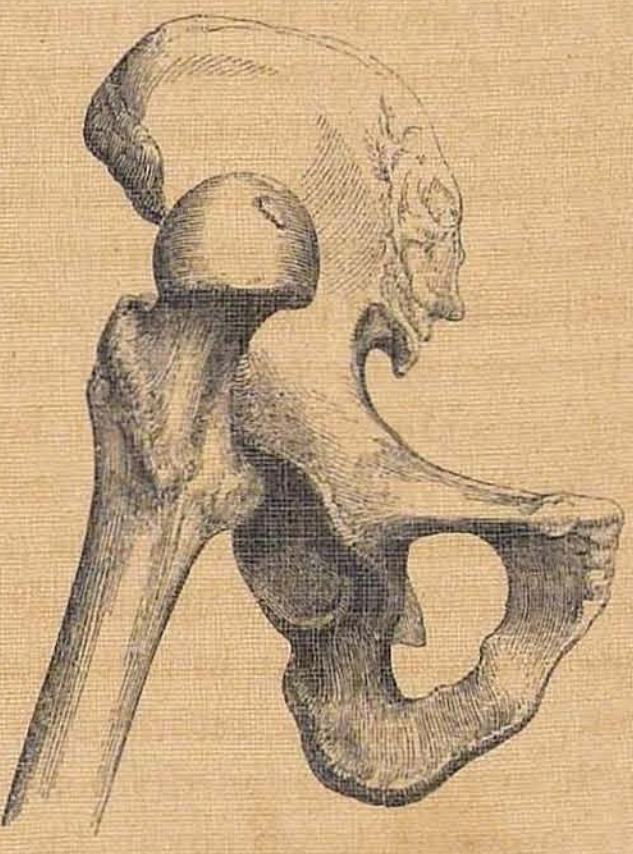

The following case of dislocation upwards and forwards on the ilium is reported by Mr. Morgan in the first number of the Guy's Hospital Reports.

Case LXVI.—J. K. a flabby-looking man, and rather fat, was admitted into Guy's Hospital, 10th December, 1835. About an hour before his admission he was helping to carry a heavy crate down stairs, when his foot slipped, and he fell backwards, receiving the weight on the groin.

The following are the appearances which the limb presented as he lay extended on his back. The left leg was shortened at least two inches, and the foot excessively everted, so as almost to

give the toes a direction backwards. The injured limb had a tendency to cross the sound one, so as to throw the heel of the former over the instep of the latter; nevertheless, when they were placed side by side, they remained in that position. The leg was susceptible of all the natural motions to some extent, with the exception of rotation: but the man complained of great pain while under examination. The projection of the trochanter major was entirely lost, whilst the luxated head of the bone could be felt under Poupart's ligament, just below and to the inner side of the anterior superior spinous process of the ilium, and apparently lying between the anterior inferior spinous process of the ilium, and the junction of that bone with the pubes. It thus rested upon the brim of the pelvis, and projected upwards towards the abdomen. The femoral artery was not displaced, but could be traced on the inner side of the dislocated bone.

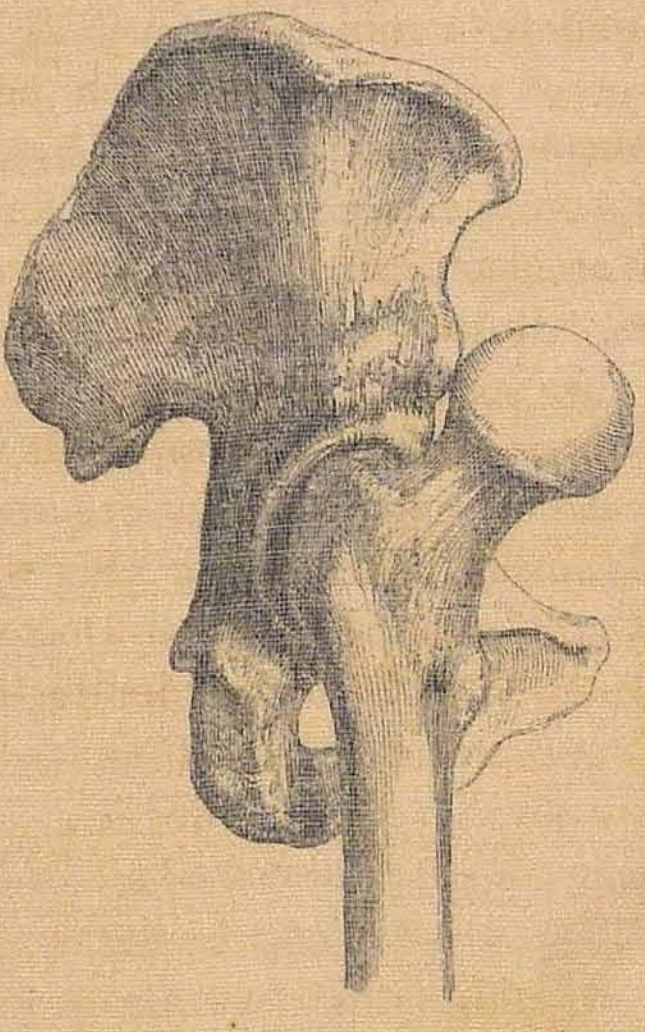

Taking into consideration, says Mr. Morgan, the age of the patient, the recent occurrence of the injury, the depressed condition of the man, and the flabby state of the muscles, I determined to attempt reduction without the pulleys; and accordingly directed that extension should be made downwards from the knee by means of a round towel, whilst I fixed the pelvis by sitting on the bed, and placing my foot between the scrotum and the thigh. Three of our students then steadily employed extension for about three minutes: the patient was then directed to raise his shoulders from the bed; and at the same moment extension was suddenly increased, and the thigh was forcibly rotated inwards, the power of a long lever being obtained by bending the knee at right angles to the thigh, and grasping the knee in one hand and the

foot in the other. This produced the desired effect, as the head of the bone returned immediately with a snap into its socket.

On the following morning the man was free from pain, and he rapidly recovered.

In the Museum at Guy's Hospital there is a specimen of a dislocated femur, in which the head of the bone is thrown upwards, on the brim of the pelvis, just to the inner side of the anterior inferior spinous process of the ilium. The preparation was presented to me by my friend Mr. Oldknow, of Nottingham, who also gave the following history of the case.

CASE LXVII.—"John Fox, æt. 28, died at the Lunatic Asylum at Nottingham. When sixteen years old he was struck on the hip by a swing-boat (such as is used at fairs for the amusement of children), by which he was knocked down, and on attempting to rise, he found himself totally unable to do so. A surgeon was immediately sent for, who discovered the nature of the accident, and made two unsuccessful attempts at its reduction. In two or three days after, the patient left his bed of his own accord; and with the assistance of a stick he began to walk, although from his expressions it seemed to have occasioned him great suffering; his foot was very much everted, and his toes only touched the ground. Six weeks after the accident he was taken to the 'Whitworth Doctor,' Mr. C. Taylor, near Manchester, who told him the thigh-bone was split, part of which

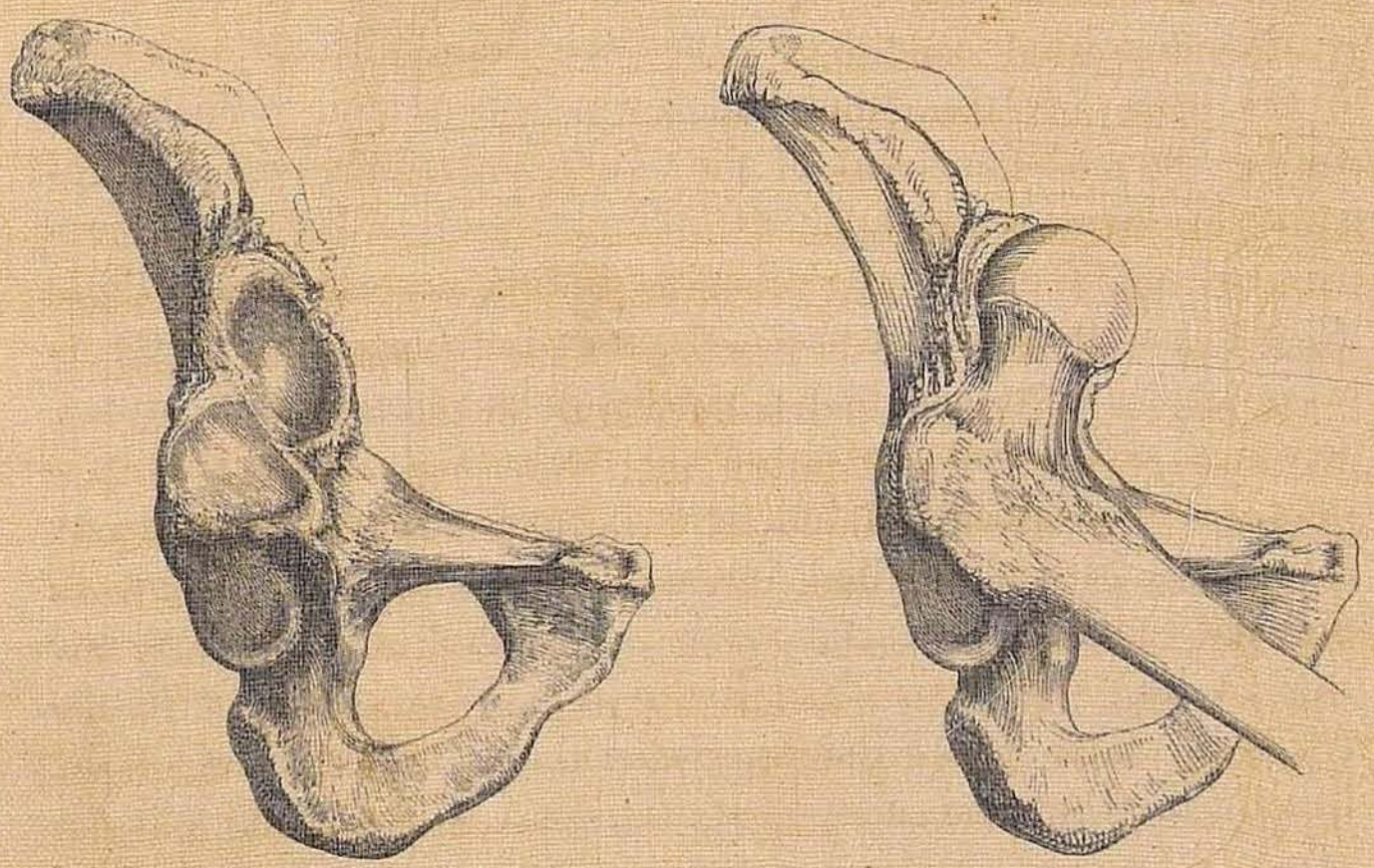

still remained in, and part was thrown out of the socket, and he ordered a plaster to be applied. From that period he had no further medical assistance. Six years after the accident, with the assistance of a stick (which he was never able to lay aside), he walked a distance of forty-two miles in one day, and returned the day but one following. He always complained of great fatigue after a long walk, but never of pain after the first few months."*

The following description is given of a patient some months after a dislocation directly upwards, by Mr. Travers, Jun.

"The left buttock is flattened; the trochanter is felt rather below and to the outer side of the anterior superior spinous process of the ilium. The neck of the bone lies apparently between the two anterior spinous processes, so that when the patient is erect, the limb seems as it were slung or suspended from this point."†

Case LXVIII.—During the summer of 1829 a man about forty years of age was brought into St. Bartholomew's Hospital labouring under pneumonia, of which he died. On examining his body, I observed that the left limb was somewhat everted, a little separated from the right, and shortened to the extent of half an inch. The head of the bone could be felt resting on the ilium, between the acetabulum and the anterior inferior spinous process. On dissecting the muscles of the hip-joint, I found them in a healthy condition, excepting the obturator externus, which was small, of a brown colour, with fat deposited between its fibres, and the tendon was torn from its attachment to the femur. The head of the femur, surrounded by its capsular ligament, rested upon the ilium, between the acetabulum and the anterior and inferior spine, in a cavity which was there formed, partly by a preternatural growth of bone, and partly by what appeared to me to be the upper portion of the cotyloid ligament, which was probably displaced at the time of the accident. The original acetabulum was contracted, and filled up by a fibrous substance. *The ligamentum teres was entire*, elongated, and flattened. The cartilage covering the head of the femur was in its natural condition, where it was in contact with the cavity in which it was lodged, but at the inferior aspect of the head of the bone the cartilage was irregularly absorbed.

* Guy's Hosp. Rep. No. I. p. 97. † Med. Chir. Trans. Vol. XX. p. 113.

On inquiring into the history of the patient, I ascertained that when he was about fourteen years of age he fell from a ladder, which produced the injury I have described. At the time of the accident he experienced considerable pain, and for many months much difficulty in walking; but he eventually recovered, and at the time of the attack of the inflammation of the lungs, which destroyed him, he was actually engaged in carrying out beer for a publican in Portugal-street. In this case, at the time of the accident the cotyloid ligament must have been partially separated, and probably a portion of the acetabulum was separated at the same time, which would allow the head of the bone to occupy the situation which it maintained without the ligamentum teres being necessarily ruptured. I cannot conceive it possible that any dislocation can take place without rupture of the ligamentum teres, provided it be of its usual length, unless indeed a portion of the acetabulum be separated at the same time. In all the other cases which have come under my observation where there has been fracture of the acetabulum, with displacement of the head of the femur, the ligamentum teres has been destroyed. In this case, had any attempt been made to replace the bone, perhaps much difficulty might have occurred in keeping it in its natural position; since in cases where the acetabulum has been fractured, although the head of the femur has been readily replaced, I have seen it impossible to retain it in its proper position. This difficulty I apprehend will depend upon the size of the portion of the acetabulum which is separated.

This accident offers an illustration of the circumstances which may prevent the head of the femur from being maintained in the usual position of dislocation upon the pubes, which there can be no doubt would have been the nature of this luxation had not the unruptured ligamentum teres retained the bone upon the ilium, although the fracture of the acetabulum permitted the head of the femur to leave its cotyloid cavity. But neither this case nor the preceding one can be justly considered as a new kind of dislocation; they are merely proofs of the variety of injuries which may occur simultaneously with dislocation, and which may influence the position of the displaced bone.

Case LXIX.—I was called into the country, says Mr. Keate, on the 13th of February 1832, to see a gentleman who had met

with a very severe accident by his horse having fallen backwards with him and upon him into a deep and narrow ditch, where he had remained, as he supposes, for nearly a quarter of an hour before he was discovered, when he was nearly exhausted by pain and by fruitless exertions in calling aloud for aid. The horse was lying on its back upon him, with his heels struggling in the air; but the gentleman, who is strong and muscular, appears to have retained firm hold of the bridle, and thus to have kept down the horse's head, and restrained in some degree the violent efforts of the animal.

He had been brought home, and was in his bed when I arrived. On examining the limb, I found it unusually elongated, —at least from three to three inches and a half. The thigh was much flexed upon the pelvis; the leg as much bent on the thigh. The whole limb was carried outwards or apart from the other more than I had ever observed in a case of luxation. The knee and the foot were much everted; the trochanter extremely sunk, the soft parts being elevated in a circle around it. I found that the head of the femur was displaced in a very unusual manner, to a situation inferior to the ischiatic notch, and I felt it lying close to and on a level with the tuberosity of the ischium, where it was capable of being freely moved under my fingers.

Without noticing the usual preparations for the reduction of a luxation, it will be sufficient to say that in the first attempt the head of the bone was thrown into the foramen ovale. A second extension enabled me to place it *nearly* in its proper position in the acetabulum, but it could not be perfectly replaced, and on gently moving it, and placing my ear on the trochanter, I felt and heard a distinct grating, as if of ruptured cartilage. By drawing the upper part of the femur outwards (by means of a round towel thrown over my neck), and pressing the knee sharply inwards, the head of the bone was replaced, with a snap, in the acetabulum; but even after this I was enabled to elongate or pull down the limb, and it was evident to me that this was owing to a portion of the cartilaginous labrum having been broken off during the violence of the accident.

The gentleman was quite aware, and mentioned after the first step, as I may call it, of the reduction into the foramen ovale, that the head of the bone was not properly replaced; and

he stated that the luxation had taken place by the same route, first into the thyroid foramen, and afterwards while struggling in the ditch, from thence downwards to the situation in which I found it. The case has proved very favourable; but there was a severe injury at the same time to the knee, which threatens still to be troublesome.*

Case LXX. — A maniac, who eluded the vigilance of his keepers, leaped from a third story window; besides dislocating his thigh, he received other injuries, of which he died in about an hour. On examining the dislocated limb it was found considerably shortened and inverted, forming about half a right angle with the body; the shaft of the femur crossing the symphysis pubis was fixed immoveably in this situation. As the patient was evidently sinking, no attempts were made at reduction.

Twelve hours after death I commenced the dissection by reflecting the gluteus maximus, when I found some of the fibres of the gluteus medius and minimus ruptured at their posterior edges. The pyriformis and gemelli were also partially torn, but the four portions of the tendon of the obturator internus which pass through the lesser ischiatic notch were drawn out and separated from their connections with the muscular fibres. The head of the femur presented itself through a rent in the capsule opposite to the upper part of the tuber ischii, above the quadratus femoris muscle, so that the great ischiatic nerve was somewhat displaced, and pressed against the tuber ischii.

In this case there was no difficulty in detecting the nature of the injury, as, besides the symptoms already described, the head of the femur could be felt resting on the tuberosity of the ischium covered by the glutæus maximus.

If this patient had been in a condition to submit to the attempt at reduction of the dislocation, by fixing the pelvis, and employing extension in the direction of the shaft of the bone, at the same time everting the limb, the head of the femur would have been brought opposite to the rent in the capsule, and would in all probability have been replaced in the acetabulum without greater difficulty than is usually experienced.

This case exemplifies completely how the loss of muscular power permitted the head of the femur to remain in an unusual position after it had been dislocated; and there can be no doubt

* Lond. Med. Gaz. vol. x. p. 19.

but that by the slightest force the dislocation might have been reduced, as there would have been no power to resist the reduction. But besides this efficient cause for the variety of the position in this luxation, I have been informed by Mr. Wormald that the ramus of the ischium and the ilio-pubic symphyses were also fractured, which in itself would be sufficient to produce the anomaly detailed. This case cannot therefore be quoted as a deviation from the usual position of the head of the femur in the dislocations of the hip, in the technical application of the term.

CHAPTER III.

ON FRACTURES OF THE PELVIS.

These accidents will, of necessity, present a great variety of symptoms, and lead to various results according to the direction and extent of the fracture, and to the degree of injury inflicted on the viscera within the pelvis.

The least important variety of these accidents is that in which a portion of the crista of the ilium is broken off, as exemplified by Case LXXVII.

Next to these in importance are cases of fracture through the acetabulum, with displacement of the femur, so as to simulate the appearance of dislocation of the hip-joint, or of fracture of the cervix femoris. Case LXXI. gives an example that was mistaken for dislocation; the limb being shortened, and the knee and foot inverted; and the late Mr. Earle, in the nineteenth volume of the Medico-Chirurgical Transactions, reported two cases of fracture through the acetabulum, that were caused by falls on the hip, and that had some resemblance to fractures of the cervix femoris. For instance, the foot was turned outwards, and the prominence of the trochanter was lost; but the limb was not shortened, and it could be freely abducted, which motion is highly painful after fracture of the cervix femoris. Vide Case LXXXIV.

A third set of cases derives its chief interest from being attended with obstruction to the urethra, by the rami of the ischium or pubes, when fractured; or, as more frequently happens, the urethra or bladder may be lacerated. If the urethra is torn anterior to the deep fascia of the peritonæum, there will be extravasation of urine into the cellular tissue of the perinæum and scrotum, which will lead to extensive abscesses and sloughing, and bring the patient's life into the most imminent danger, unless prompt measures are taken for his relief.—Vide Cases

LXXIV. LXXVI. Laceration of the bladder, laying it open into the peritonæal cavity, must almost necessarily be fatal.

A fourth class of these accidents includes the cases in which the os innominatum is torn from the sacrum, and the pubic symphysis either rent asunder, or the rami of the pubes and ischium extensively broken, as in Case LXXIII. These accidents are produced by such tremendous violence, and are attended with so much injury to the soft parts without the pelvis, and to the neighbouring viscera, that recovery can scarcely be looked for.

The symptoms common to most of these accidents are, that crepitus may be detected by placing the hand upon the crista of the ilium, or by auscultation with the stethoscope, whilst the thigh is moved in various directions; and that there is considerable pain and difficulty in those motions of the trunk which are performed by means of the abdominal muscles: the patient, for example, cannot shift the position of his buttocks as he lies in bed.

In fractures of the crista ilii, considerable motion of the broken parts may sometimes be detected; moreover, the real nature of those cases which simulate dislocation may readily be determined by the preternatural mobility that is present.

But I must caution the surgeon against making too minute an examination, with the view of detecting the precise situation of the fracture, as he may easily do more injury by the examination than the discovery would compensate for.

Treatment.—When there is reason to suspect fracture of the pelvis, the patient should be placed in a perfectly horizontal posture, so as to enable the surgeon to judge accurately of the relative position of the spinous processes of the ilia, as well as of the comparative length of the lower extremities; when, if it be found that a want of symmetry indicates displacement of the bones of the pelvis, I should recommend that a catheter be immediately passed into the bladder, to discover whether or not it or the urethra be injured, before any attempt be made to discover the precise seat of injury; for the force necessary to ascertain that fact might inflict a further laceration of the urinary apparatus. Should bloody urine, or a difficulty in passing the catheter, denote a fracture, the catheter should be left in the bladder and a broad belt be tightly applied around the pelvis, to maintain the bones in perfect apposition. To secure this

desirable object, I usually recommend a second broad girth to be passed under the nates, the ends of which are to be attached to a pulley suspended from the top of the bed, by which the patient may raise himself without any effort of the muscles attached to the pelvis. Besides these mechanical means, the strictest antiphlogistic regimen that is compatible with the powers of the patient is to be adopted to diminish the tendency to inflammation. If the surgeon does not see the case till some hours after the occurrence of the accident, and finds the scrotum tense and swollen, and a difficulty in introducing the catheter, he should make a puncture or two with the point of a lancet to ascertain whether the swelling arises from infiltration with urine; and if the fluid that escapes has a urinous smell, he should make several incisions through the skin of the scrotum and perinæum to let it exude; at the same time the catheter, if it can be introduced, should be retained in the bladder; if it cannot be introduced, the ruptured part of the urethra should be cut down upon from the perinæum.

Case LXXI.—A man was brought into St. Thomas's Hospital, in January 1791, on whom a hogshead of sugar had fallen. Upon examination, the right leg was found about two inches shorter than the left, and the knee and foot were turned inwards; these circumstances induced the surgeon under whose care he fell to think the case a dislocation, although, as he stated, the limb appeared to be more movable than usually happens in such accidents, and there was a great contusion and considerable extravasation of blood. The surgeon used the utmost caution in making a very slight extension, in order to bring the legs to an equal length, in which he did not succeed; and whilst it was performing, a crepitus was discovered in the os innominatum. The man had a remarkable depression of strength, and paleness of countenance, and appeared to be sinking. In the evening he died.

Upon examination of the body, the following appearances were observed: — The posterior part of the acetabulum was broken off, and the head of the thigh-bone had slipped from its socket; the tendon of the obturator internus, and the gemini, tightly embraced the neck of the bone; the fracture extended from the acetabulum across the os innominatum to the pubes; the ossa pubis were separated at the symphysis nearly an inch

asunder, and a portion of the cartilage was torn from the right pubes, and adhered to that on the left side; the ilia were separated on each side, and the pubes, ischium, and ilium broken on the left side; the abdomen contained about a pint of blood, and the left kidney was greatly bruised; the integuments were stripped off the patella and knee on one side, so as to expose the capsular ligament.

Case LXXII. — In a second case of this kind, which was admitted into St. Thomas's Hospital, having the appearance of the dislocation backwards, the patient lived four days. On examination, the fracture was found passing through the acetabulum, dividing the bone into three parts; and the head of the thigh-bone was deeply sunk into the cavity of the pelvis.

The following case of fracture and dislocation of the bones of the pelvis occurred in Guy's Hospital: I am obliged for the particulars to Mr. Sandford, who attended to the patient as dresser.

Case LXXIII. — Mary Griffiths, aged thirty, was admitted into Guy's Hospital in the afternoon of the 8th of August 1817. Her pelvis had sustained a severe injury from her body having been pressed by the wheel of a cart against a lamp-post.

A small quantity of blood had been taken from her arm previous to her admission; and as she was very pale, her pulse extremely weak, and her fæces passing involuntarily, no more blood was drawn.

Soon after admission she was examined; when by placing her on the face, with one of my hands on the back of the right ilium, and the other on the pubes of the same side, a distinct motion and crepitus could be perceived. The posterior spine of the ilium projected upwards, above its usual junction with the sacrum, and it was thought that the ilium was dislocated from the sacrum, with some fracture either of the ilium or the sacrum. When turned on her back, and examined *per vaginam*, the pubes was found passing more into the cavity of the pelvis than usual. A large quantity of blood was effused from the last rib to the upper part of the thigh, on the right side.

It was now a question whether this extravasated blood should not be discharged by making an opening through the integuments, as it appeared to be fluid; but, upon consideration, it was thought that the vessels would still bleed, that she could not bear the loss of blood in her weakened state, and that the blood, when coagulated, would form the best security against further

effusion. All that was done, therefore, was to roll a broad bandage round the pelvis to fix it firmly, to give tinct. opii. gt. xxx., and to draw off the urine from her bladder, which contained about a pint.

In the evening the extravasation of blood was somewhat increased, and she complained of a pricking sensation in the right thigh and leg, which induced her to loosen the bandage. She had vomited; her feet were cold; she had severe pain, and great thirst; her pulse was 90, and small.

On the 9th, she complained of a sensation of one side tearing from the other, and, upon examination of the lower extremities, that on the right side was found shorter than the other; there was numbness also on that side. Her tongue was furred, but her pain and thirst somewhat less; and she had not the same coldness in her feet as on the night previous. As her bowels had not been relieved since her admission, aperient medicine was given; and the bladder being incapable of emptying itself, a catheter was employed. The ecchymosis was of great extent, and it was doubtful whether it could be absorbed. A pillow was placed against the right side to support the pelvis, and another was put under the knee to preserve the limb in an easy position.

On the morning of the 10th, she complained that the bones of the pelvis moved upon each other, even more than at any former period, and that she had suffered severe pain; the tongue was now furred, pulse fuller, but her bowels had been relieved, and her water passed without assistance. At one o'clock this day, her pulse being fuller, and 120 in a minute, with great heat of skin, I bled her to the amount of ten ounces; but the blood did not exhibit any signs of inflammation, nor did the loss of blood produce any apparent effect in relieving her symptoms. In the evening her pain and fever had increased; and as she complained of the tightness of the bandage which still surrounded the pelvis, it was removed. The catheter was then obliged to be employed. Some saline medicine, with opium, was ordered.

On the 11th, she stated that she had passed a good night. Pulse 120 and softer; tongue furred; she was directed to continue her medicines. A stimulating lotion was ordered on the 12th, to produce an absorption of the extravasated blood. Some spots appeared of a very dark colour, where the ecchymosis had been most severe, and the cuticle was abraded upon those parts.

From this day the excoriated parts, which had been excessively bruised, began to slough. On the 21st, the sloughing had increased; the tongue was furred; pulse 120. On the 22nd she was worse; and on the 23rd, her stomach rejected every thing; she had a strong impression that she should not recover; she refused her medicine, and the slough had increased. In the evening of the 24th she died.

Examination. — On the 25th, the body was examined. — A fracture was found passing through the body of the pubes on the left side, and through the ramus of the left ischium.

The right os innominatum was separated from the sacrum at the sacro-iliac symphysis, and a part of the transverse processes

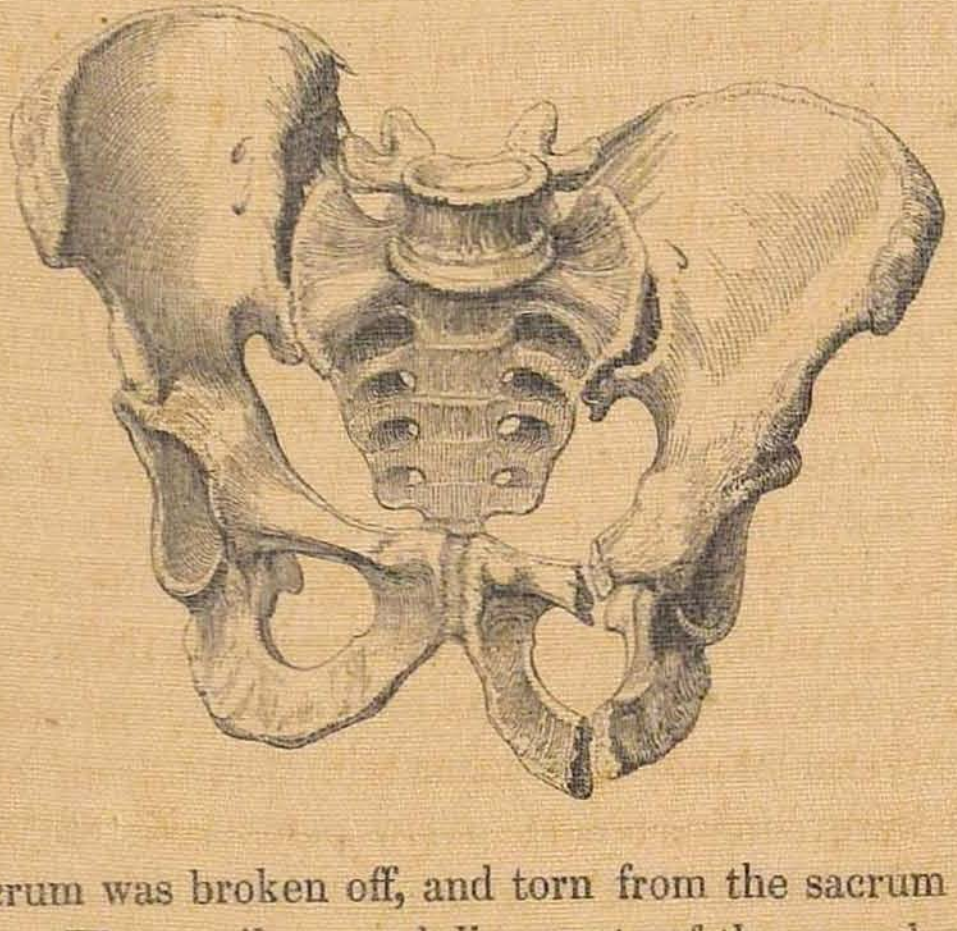

of the sacrum was broken off, and torn from the sacrum with the ligaments. The cartilage and ligaments of the symphysis pubis were torn, and the left sacro-iliac symphysis had given way; the ligament over it being torn, and the bones separated sufficiently to admit the handle of a scalpel being received between them. Blood was found extravasated in the pelvis behind the peritonæum.

I have known three instances of recovery from simple fracture of the os innominatum: two of these were fractures of the ilium, and the nature of the accident was easily detected by the crepitus which was perceived upon moving the crista of the ilium; the third case was a fracture at the junction of the ramus of the ischium and pubes. In the two first a circular roller was applied

upon the pelvis, and the patient was freely bled; but in the latter no bandage was employed. I have also known a compound fracture of the os innominatum recover; but Mr. Hulbert, surgeon, sent me a compound fracture of the ilium, which had proved fatal.

Several cases have also occurred within my knowledge of fracture of the pubes, near its symphysis, accompanied with laceration of the bladder, each of which proved destructive; but when the bones have been broken without injury to the bladder, the patients have recovered. The bladder is liable to be burst or not, in this accident, according to its state of distension or emptiness at the moment; for, if empty, it may escape injury.

Case LXXIV.—On the night of the 18th January 1838, a young man who was driving a cart, in attempting to stop the horses was thrown down, and the wheel passed over him. A medical gentleman who saw him at six in the morning, about six hours after the accident, found a comminuted fracture of the left tibia and fibula, a contusion and excoriation of the integuments of the inner side of the left thigh, great swelling and ecchymosis of the scrotum, and a slight appearance of injury over the pubes and left hypochondrium. No dislocation or fracture of the pelvis could at that time be discovered. The patient was suffering great pain, and was cold and exhausted; the pulse was feeble and quick, and a few drops of blood had escaped from the urethra. Warm brandy and water with forty drops of tincture of opium were administered; a few punctures were made with a bleeding lancet into the scrotum, and warm fomentations were applied to the injured parts. The fracture of the leg was reduced and the limb placed in the straight position.

At three *post meridiem*, the patient felt altogether more comfortable, but was now suffering from an urgent desire to pass water. There had been a considerable oozing of bloody fluid of an urinous smell from the punctures. The surgeon attempted to introduce a silver catheter, but was unable to pass it beyond the bulbous part of the urethra; the obstacle to its progress gave it an inclination towards the right side; and there was a sensation as if the point of the instrument entered some spongy substance, which was probably coagulated blood, as some blood of the consistence of broken up jelly followed the withdrawal of

the catheter. At length, however, the instrument was passed to the bladder, and about four ounces of a grumous fluid of an urinary smell escaped, which gave great relief. A fresh examination was now instituted, but no fracture or dislocation could be discovered. An aperient was given; some saline medicine with opium was ordered every four or five hours; leeches were applied to the scrotum and perinæum; the fomentations of poppyheads and chamomiles was continued; the diet was ordered to be low; and the leg was secured by splints, and kept wet with evaporating lotions.

19th. The patient passed a painful and restless night; the leeches had bled freely; the scrotum, perinæum, and thigh were much swollen and inflamed; there was great desire to pass urine; and the oozing had continued from the punctures in the scrotum. The catheter was again passed, and four or five ounces of the same kind of fluid were drawn off. More leeches and fomentations were applied, and the catheter was passed again in the evening.*

20th. The swelling and inflammation had increased; no urine came by the natural passage, and there was a good deal of constitutional disturbance and restlessness, with a frequent pulse and dry tongue. Saline medicines with aperients, and the fomentations were continued; and the catheter was passed twice daily; the urine was dark, turbid, and offensive.

21st. Suppuration threatens; poultices applied.

26th. An abscess was punctured, which pointed on the left side of the perinæum, and a large collection of pus with an urinary odour escaped. The integuments of the entire left half of the scrotum sloughed, laying the testicle completely bare; and the patient's constitutional powers became very much ex-

* In reviewing the treatment of this case, there certainly is great reason to regret that the catheter was not introduced at the surgeon's first visit, and that it was not retained in the bladder, when it was introduced in the afternoon; because, when there is reason to suspect laceration of the bladder or urethra, the bladder ought to be kept constantly empty, and no urine ought to be allowed to pass the urethra, except through the catheter. The leeches, it is to be apprehended, could do little good to a part infiltrated with urine, and the loss of blood most probably helped to produce the dangerous state of constitutional depression which followed. It is to be regretted also that an incision was not made in the perinæum on the 20th or 21st, without patiently poulticing the part till an abscess pointed there.—*Ed.*

hausted. Wine, bark, and ammonia, with nutritious diet, were therefore administered and continued for a considerable time. The aperture in the perinæum discharged freely, and the whole of the urine escaped through it. On passing his finger into it, the surgeon could distinctly feel the bare catheter just under the arch of the pubes; he also felt the ascending ramus of the ischium fractured, and could trace the oblique course of the fracture with the rough and ragged edge of the upper portion, which was a little in advance of the other. This satisfactorily accounted for the turn given to the catheter.

The subsequent treatment consisted in supporting the powers of the constitution; allaying inordinate irritability, and keeping the pelvis as free from motion as possible. A flexible gum catheter was after a time introduced and secured in the bladder; but it was withdrawn after some days, as no urine flowed through it, when it was found blocked up by earthy deposit, and the gum in part dissolved.* A silver catheter was therefore substituted, and was occasionally withdrawn, to ascertain that it was pervious.

On the 13th of February, urine passed through the natural passage; on the 26th of March the fistulous aperture in the perinæum closed; and in the course of the summer he entirely recovered.

The poor fellow, alone and unaided, managed to crawl with his broken leg and pelvis, from the spot where the accident happened, to a cottage half a mile distant; but he was four hours in doing so.

Case LXXV.—A soldier who was in the Military Hospital at Plymouth being sufficiently recovered from an illness to be allowed to walk upon the rocks, by some accident fell over a precipice upwards of sixty feet in height. Upon examination, it was found he had broken his right collar-bone, and three or four of his ribs, and that he had also received very severe contusion in the glutæal region, which in fact concealed, as was afterwards proved, a fracture of the right os innominatum. This man lived three weeks after the accident, suffering great pain

* This earthy matter consisted of the phosphate of lime, which is always copiously secreted by the mucous lining of the bladder and urethra in these cases; and therefore the catheter ought always to be withdrawn once in every forty-eight hours to prevent it from being obstructed by the phosphatic deposit, or dissolved by the ammoniacal urine.—*Ed.*

in the pelvic region, inability to move himself in bed, and being the subject of frequent rigors. Upon post mortem examination a great effusion of blood was found enveloping the glutæi, and a deep seated abscess was formed upon the innominatum on the right side, which was fractured in several directions.

Case LXXVI.—I was sent for some years ago by Mr. Wilson, a surgeon at Huntingdon, to visit the Honourable M. S., who had received an injury through a fall from his horse while hunting; and being unable from pressure of business to obey the summons, I sent my nephew Mr. Bransby Cooper to the case, to whom I am obliged for the following particulars. The patient was lying in bed without the power of altering his position in the least degree, but his principal suffering seemed to be from not having passed his urine since the accident, a period of upwards of twenty-four hours. Mr. Cooper, therefore, immediately passed a catheter, in which, however, he experienced some little difficulty, and drew off a considerable quantity of urine slightly tinged with blood, leaving an elastic gum catheter in the bladder. A strong belt was applied around the pelvis, the antiphlogistic regimen strictly adhered to, and notwithstanding that the pubes appeared to be extensively fractured, the patient ultimately did well with the judicious treatment of the medical gentleman under whose care he was left.

Case LXXVII.—*Fracture of the right ilium.*—Robert Rozier, æt. 14, was admitted into Guy's Hospital on the 20th of December 1830, being the subject of a severe injury to the pelvis from a fall on board ship. He stated that on the night of the 18th he fell from the rigging of the vessel to which he belonged, and alighted on his hip, the height from which he fell being, he supposed, about forty feet. He was stunned by the fall; and on recovering himself found he was unable to stand, and that any attempt to do so gave him great pain. Upon attempting to raise him from the board on which he was brought, he expressed great anxiety to have some support for his pelvis whilst they were removing him to his bed, seeming to suffer greatly when the abdominal muscles were brought into action to support the lower part of the body. Motion of the right thigh also gave him great pain, but he did not complain when the head of the femur was forcibly pressed against the acetabulum.

He was placed in bed, a catheter passed, and his urine, which

was healthy, drawn off,—indicating the safety of the urinary organs. On pressing firmly on the dorsum ilii with one hand, and grasping the anterior superior spinous process of the right ilium with the other, at the same time moving it, a distinct crepitus was felt; marking evidently a fracture separating the spinous process and about a fourth of the crista of the ilium from the rest of the bone. Although, however, the fractured portion possessed so great an unnatural degree of mobility upon the rest of the ilium, no displacement was evident upon mere inspection.

Twenty leeches were ordered to the injured part; and after the bleeding had ceased, the constant application of evaporating lotions. Calomel and colocynth pills, and a purgative mixture, were also prescribed. A long bandage was applied around the pelvis and upper part of the right thigh, the pressure made by this bandage being sufficiently firm to confine the fractured portion.

January 4th. The antiphlogistic plan has been persisted in, and he is in every respect doing well. He has to-day got out of bed, and can stand very well, but walks lame, keeping the right thigh slightly flexed, so as to bear his weight chiefly on the toes.

On the 10th of February this patient walked up from Deptford to Guy's Hospital to inquire if he might go to sea. He was then perfectly well; but says that after walking to fatigue he feels a slight weakness in the seat of fracture.*

Case LXXVIII. — James Hubble, æt. 50, on the 23rd of April, was endeavouring with some other men to raise by machinery the boiler of a steam-engine, weighing five tons, out of a barge, when one of the chains broke, and a large bar of iron, and a log of wood supporting the weight of the boiler, fell upon him, and threw him backwards into the barge. He was immediately conveyed to Guy's Hospital on a shutter, and placed in bed, when I directly saw him. Upon examination, I found a compound fracture of the pubes, and extensive laceration of the abdominal parietes, so as to expose the anterior surface of the bladder, which also was rent. From the appearance of the left

* This case, as well as the two following ones, were treated by Mr. B. Cooper. They are both narrated in his "Surgical Essays, the result of clinical observations at Guy's Hospital."

thigh, I was led to suspect it was dislocated; but upon examination found that its deformity depended upon the displacement of the ossa innominata, which were so completely comminuted that upon placing the hand upon any part of the pelvis, crepitus was distinctly felt.

The patient's countenance indicated anxiety rather than pain: a cold sweat stood upon his forehead, his face was deadly pale, his pulse scarcely to be felt, and his extremities cold; but he was perfectly sensible, and resigned to his fate, which he seemed to feel no human power could obviate. I immediately ordered him forty drops of laudanum in the julep of ammonia; passed a catheter into the bladder, (which was done, however, with some little difficulty from the displacement of the urethra,) and drew off a small quantity of bloody urine. I also ordered a broad belt to be put around the pelvis, so as to keep the parts in apposition, and prevent any motion from the action of the respiratory muscles. This, however, could not be done; for the motion necessary to pass the bandage around him produced so much suffering, and dissolution was so fast approaching, that it seemed a cruel disturbance to his last moments. In half an hour from the time of his admission he expired, and appeared sensible as he breathed his last.

CASE LXXIX.—*Separation of the Symphysis Pubis.*—Richard White, æt. 22, was admitted into Guy's Hospital on the 30th of July 1832, having sustained a severe injury in consequence of a large quantity of gravel having fallen upon his back while in the act of stooping. It knocked him down; and on rising, which he did with considerable difficulty, he attempted to walk; this produced violent pain in the region of the bladder, extending upwards in the course of the ureters to the kidneys. Upon inquiry he stated that the urine he had voided since the accident was bloody, and passed with difficulty.

On examination, a fissure was found at the symphysis pubis, producing a separation of about two fingers' breadth. On pressure being made upon any part of the ilium he complained of increased pain in the region of the pubes, and of numbness down the left thigh.

A catheter was immediately passed, and the urine which was drawn off was clear and healthy. Leeches were applied over the pubes, and a broad belt was firmly buckled around the pelvis,

sufficiently tight to bring the separated pubes nearly in contact, and the patient ordered to be kept perfectly quiet in the recumbent posture, on low diet. The leech-bites ulcerated, and some slight degree of fever resulted, which, however, readily yielded to the usual treatment.

He remained in the hospital for three months without any check to the progress of his cure; the length of time it required being accounted for by the difficulty of reparation in an amphiarthrodial articulation; and when he left there was some slight separation of the pubes remaining; nor were the two lower extremities, or the anterior and superior spinous processes of the ilia perfectly symmetrical, although he could walk very well.

Case LXXX.—A patient was admitted into the Middlesex Hospital, under Sir Charles Bell, who, having fallen a considerable height, sustained a severe injury to his left hip. Upon examination of the injured part, a crepitus could be felt on rotating the thigh, but was more readily perceived when the hands were pressed upon the crista of the ilia. By this examination a fracture could be discovered passing through the ischium to the acetabulum, and from thence diverging towards the sacrum. The usual treatment was adopted of enjoining absolute rest, and applying a broad belt tightly around the pelvis, and adhering strictly to the antiphlogistic regimen. Not a bad symptom occurred in this case; the excretions were passed without difficulty, and in six weeks the patient left his bed, and was able to walk with the assistance of crutches. At the period of his dismissal, however, from the hospital, there was some difficulty in rotating the injured limb to its natural extent, probably from some irregularity in the acetabulum, produced by the process of reparation.

Case LXXXI.—The following case I consider worthy of narration, in consequence of the extent of fracture of the bones of the pelvis, as well as of those of the lower extremities, as such a complication requires strict examination to ascertain the degree of injury sustained; for however judiciously the treatment might have been applied to the fractures of the lower extremities, it might have proved unavailing, unless active means were employed to subdue the inflammation concomitant with fracture of the pelvis. It is true in this case the patient did not survive; but Mr. Vincent, by ascertaining the full extent of the injury,

was enabled to administer every remedy applicable to the condition of the patient.

A man sixty-five years of age was brought into St. Bartholomew's Hospital in consequence of a severe injury he had received from a brewer's dray having passed over him. Upon examination after he was placed in bed, a fracture of the right thigh was discovered, the bones overlapping each other; and there was also an inversion of the left foot. On proceeding carefully to examine the cause of this inversion, it was observed that on attempting to rotate the left leg outwards, it suddenly regained its natural position, accompanied with a noise as if the bone had slipped into its socket. The hand being placed on the great trochanter, a crepitus was communicated indicating fracture at its basis. The left fibula was also broken, and there was a severe contusion of the right ankle. The patient on his admission was in a state of collapse, his pulse small and weak, the surface of his body cold; he discharged his fæces involuntarily, and his answers when questioned were vacillating and confused: he was ordered wine and opium. The patient regained in some measure the natural temperature of his body, but continued to pass his fæces involuntarily, and died on the second day after his admission.

Upon examination of the body, it was found that a portion of the bony ring of the left acetabulum was broken off, although in some measure retained in position by the cotyloid ligament, which was entire: this accounts for the inversion of the left foot, as well as for the noise which was heard when the limb was rotated. The head of the femur probably rested on the broken surface of the ilium; but the ligamentum teres was entire, so that the attempt at rotation brought the head of the femur completely into the socket, and permitted the fragment of the ilium to regain its natural position. A fracture was discovered, as had been prognosticated, through the base of the trochanter, but it did not include the shaft of the bone. The fracture extended from the acetabulum through the os innominatum, so as to divide it into nearly equal portions, the fractured edges overlapping each other to the extent of two lines. There was also a partial dislocation of the sacro-iliac symphysis of the same side. The viscera were uninjured.

This case is recorded in Vol I. new series, of the Lancet.

Case LXXXII.—In July 1830, Mr. Aston Key was requested to visit a patient (who had been the subject of a severe injury on the right side of the pelvis,) to determine the nature of the accident, and to ascertain the cause of a retention of the urine.

Upon examination, Mr. Key found an unnatural flatness in the front of the pelvis, but could not discover by external examination any fracture; but on passing his finger into the rectum, he felt the descending ramus of the pubes fractured just at its junction with the ramus of the ischium, and the fractured extremity had penetrated the walls of the bladder near its neck, and passed into the rectum.

Since the accident, which had happened ten days before Mr. Key had seen the patient, the urine had constantly passed from the anus; but in consequence of the little expression of suffering from the patient, no idea had been entertained of the existence of any fracture.

Case LXXXIII.—Mr. Bret, of Barnet, æt. fifty-two, in 1824, while hunting, was thrown over his horse's head, and fell upon his hands and knees, and while in this position the horse fell upon Mr. Bret's right hip, forcing him to the ground, with which his right pubes came in contact. Upon examination it was ascertained that the ramus of the pubes had been fractured, producing, however, no injury either to the urethra or rectum. A portion of the bone seemed to be detached, for it was drawn forwards and downwards by the action of the adductor muscle, and twelve weeks after the accident the fractured ends of the bone were movable, producing inconvenience and pain in walking or attempting to abduct the thigh, Mr. Bret, however, perfectly recovered, without any permanent inconvenience from the accident.

Case LXXXIV.—A man, æt. forty, was admitted into St. Bartholomew's Hospital, in Oct. 1829, with a fracture of the pelvis, caused by his falling from a height of thirty-one feet upon the left side. He had lost all control over the left leg, and could not raise it from the bed. The limb was not shortened, but the foot was everted. Any attempt to rotate the limb caused great pain, and was accompanied with a very sensible crepitus when the hand was applied over the hip-joint. The left trochanter was much less prominent than the right, and in fact could with

difficulty be felt. On pressing it the patient complained of deep-seated pain in the hip-joint.

The patient recovered in eight weeks, and was able to walk nearly as well as before; but he soon afterwards died of disease in the chest.

On examination, a fracture was found extending in two directions through the acetabulum; there was an extensive comminuted fracture of the ilium, with great displacement, and the os pubis was broken in three places. "The reparation was very complete: and it is interesting to observe," says Mr. Earle, "how nature has guarded against any considerable deposit of new bone within the articulation, which might have interfered with the functions of the joint, although there is an abundant deposit of callus around the other parts of the fractured bone." *

* Medico-Chirurgical Transactions, vol. xix.

CHAPTER IV.

ON FRACTURES OF THE UPPER PART OF THE THIGH-BONE.

SECTION I.—INTRODUCTORY.

Before I enter into a description of the dislocations of other joints, it will be proper to point out the fractures incident to the upper part of the thigh-bone, as it is essentially necessary that these accidents should not be confounded with dislocations, or with each other, a mistake which has but too frequently happened. Indeed it must be confessed, that their distinguishing marks from dislocation are sometimes detected with difficulty, and that the different species of fracture are also liable to be confounded with each other; for three distinct species, very different in their nature and in their results, have been described and classed under the indiscriminate appellation of fracture of the neck of the thigh-bone. Hence has arisen that difference of opinion, which has led to much discussion respecting the process which nature employs for their cure; and which less hypothetical reasoning, and more attention to the development of such accidents by dissection, would have been the means of preventing. Whilst one surgeon asserts that all attempts to cure them are unavailing, another maintains that they admit of union like fractures of other bones; which latter opinion is only true as far as regards two of the species of these fractures.

I shall now, therefore, proceed to state the results of my observations on living persons who have been the subjects of these accidents; of my examinations of the dead body; and of some experiments upon inferior animals, which illustrate this subject.

These accidents are more frequent than dislocations of the thigh-bone; for whilst we receive into our hospitals of Guy's and St. Thomas's (containing about nine hundred persons,) not more upon an average than two such dislocations in a year,

our wards are seldom without an example of fracture of the upper part of the thigh-bone.

The different species of fracture of the upper part of the thigh-bone are, as we have already observed, three in number.

First: That in which the fracture happens through the neck of the bone entirely within the capsular ligament.

Secondly: A fracture external to the ligament, through the neck of the thigh-bone, at its junction with the trochanter major; by which the trochanter is split, and the neck of the thigh-bone is received into its cancelli. This is often in part within, and in part external to the capsular ligament.

Thirdly: A fracture through the trochanter major, below its junction with the cervix femoris.

Besides these three species, which are liable to be confounded with each other, we shall speak of fracture of the trochanter major, and of fracture of the shaft of the femur just below the trochanters.

SECTION II.

FRACTURE OF THE NECK OF THE THIGH-BONE, WITHIN THE CAPSULAR LIGAMENT.

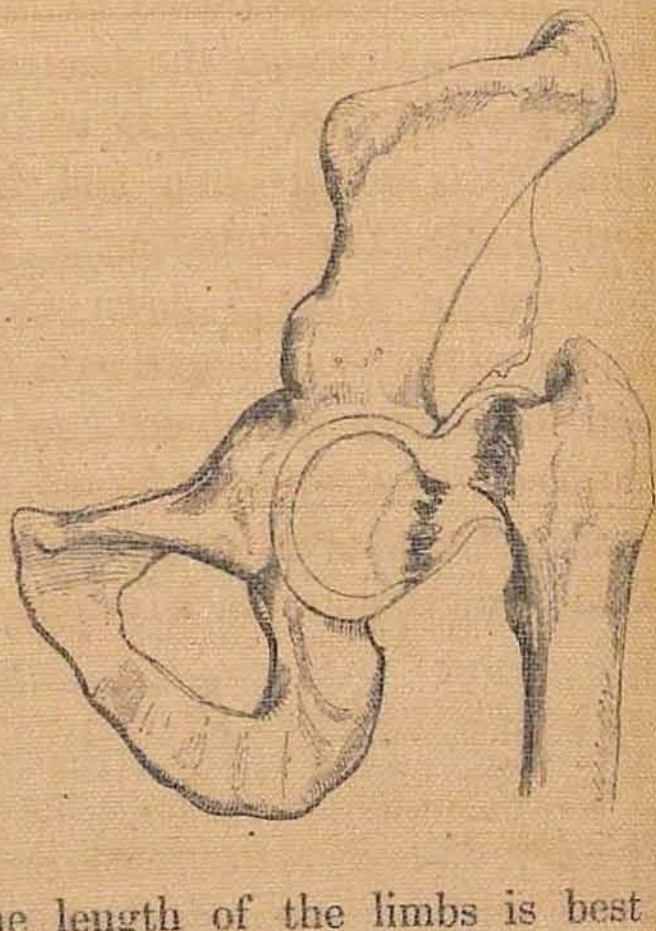

SYMPTOMS. — *Shortening.* — The appearances which are produced by this fracture are as follows:—The leg becomes from one to two inches shorter than the other; for the connection of the trochanter major with the head of the bone, by means of the cervix, being destroyed by the fracture, the trochanter is drawn up by the muscles as high as the capsular ligament will permit, and consequently rests upon the edge of the acetabulum, and upon the ilium above it. The difference in the length of the limbs is best

observed by desiring the patient to lie straight on his back, when, by comparing the ankles, it will be generally found that one leg is shorter than the other. The usual state of the limb is, that the heel on the injured side rests in the hollow between the malleolus internus and tendo Achillis of the other leg; but there is some variety in this respect; for a projection is sometimes formed in the trochanter minor, which catches the neck of the bone, and prevents a greater ascent than half an inch. Sir B. Brodie informed me that he dissected a case in which the cervix was obliquely broken, and in which the upper part of the bone prevented the ascent of the lower. On the other hand, when the fracture has happened for a length of time, and the patient has borne upon the injured limb, the ligament becomes extended, and the leg may be shortened to the extent of four inches; of this Mr. Langstaff mentioned to me an instance in a man, aged eighty-two, in whom the heel was obliged to be elevated four inches to make the bearing of the limbs equal. I saw the fractured parts in this man, and the shoe he wore, which entirely verified Mr. L.'s statement. The retraction is at first easily removed by drawing down the shortened limb, when it will appear of the same length with the other; but immediately when this extension is abandoned, and the patient exerts himself, the muscles draw it into its former position. This evidence of the nature of the accident continues until the muscles acquire a fixed contraction, which enables them to resist that extension

*

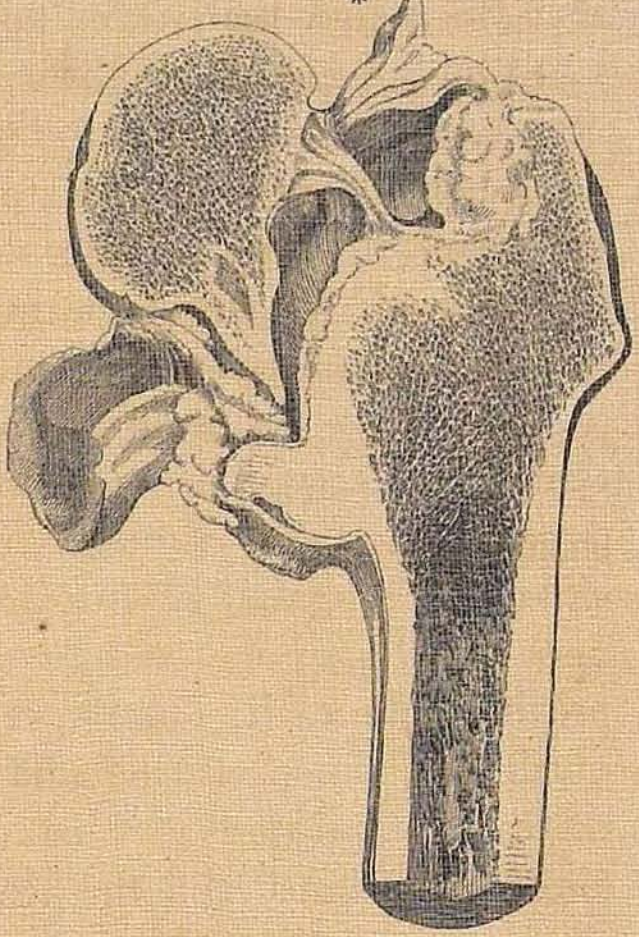

* This figure exhibits a fractured cervix femoris partially united by bands of ligament; the neck of the bone is entirely atrophied, so that the head and shaft are brought into contact, and their surfaces are rendered smooth by friction; the capsular ligament is excessively thickened; and there is a projection formed by the trochanter minor, on which the head of the bone rested.

which had been before sufficient to restore the natural appearance of the limb.

I had once a patient in Guy's Hospital with a fracture of the neck of the thigh-bone, in whom the following circumstances could be observed:—When placed in the recumbent posture, the injured limb was one inch and a half shorter than the other; but when he was standing it was two inches and a half shorter than the sound limb; the cause of this diversity is as follows: when he lay down, and the spinous processes of the ilia were in the same line, the shortening arose only from the retraction of the thigh-bone; but when he stood up, he threw the axis of his body over the thigh of the sound limb, to enable him to support himself; and elevating the pelvis, raised the injured limb one inch more than when he was recumbent.

Eversion.—Another circumstance which marks the nature of this injury is the eversion of the foot and knee; and this state depends upon the numerous and strong external rotatory muscles of the hip-joint, which proceed from the pelvis to be inserted into the thigh-bone, and to which very feeble antagonists are provided: thus, the obturatores, the pyriformis, the gemini and quadratus, the pectinalis and triceps, all assist in rolling the thigh-bone outwards; whilst only a part of the glutæus medius and minimus, and the tensor vaginæ femoris, are the principal agents of rotation inwards. It has been denied that this eversion is caused by the muscles, and it has been attributed to the mere weight of the limb; but any one may satisfy himself that it arises chiefly from the muscles, by feeling the resistance which is made to any attempt at rotation of the thigh inwards. This difficulty of rotation inwards is also in some measure attributable to the length of the cervix femoris, which remains attached to the trochanter major; because in proportion to its length, which rests against the ilium, the trochanter is prevented from turning forwards.

Directly that the bed-clothes are removed, two circumstances strongly arrest the attention of the surgeon; namely, the *diminished length* of the injured limb, and the *eversion of the foot* and knee. In the dislocation upwards, the head and neck of the bone prevent the trochanter from being drawn backwards, whilst the broken and shortened neck of the thigh-bone, in fracture of this part, readily admits it; and hence the reason that the foot

is inverted in luxation, and everted in fracture. It is, however, proper to state, that an exception to this rule does now and then take place, and that the limb is found inverted; but it is of extremely rare occurrence.* Some hours must elapse before this eversion assumes its most decisive character, as the muscles require some time to become permanently contracted; and this is the reason that the accident has been mistaken for dislocation on the dorsum ilii. The surgeon having been called soon after the accident has happened, before the muscles have acquired that state of contraction to which they are liable, is led to mistake the nature of the injury, because the foot is not so decidedly everted as it afterward becomes; and for this reason patients in hospital practice have been exposed to useless and painful extensions.†

Degree of pain. — In fractures of the neck of the bone within the ligament, the patient, when perfectly at rest in the horizontal posture, suffers but little; but any attempt at rotation is attended with some pain, because the broken extremity of the bone then rubs against the inner surface of the capsular ligament, upon which it is drawn by the action of the muscles. The

* I have seen a case of Mr. Langstaff's, in the City, in which the foot was inverted, and the bones, although they rubbed against each other, had not united. Mr. Guthrie (Med.-Chir. Trans. vol. xiii.) considers it probable that the inversion of the foot in fractures of the upper part of the thigh-bone, which now and then happens, arises from a diagonal fracture through the trochanter major; so that the glutæus medius and minimus, with the tensor vaginæ femoris, draw the thigh-bone forwards, and roll it inwards. He showed me a preparation which confirmed this opinion. — *Vide* Case XCIV.

† There are cases now and then occurring of fracture, altogether internal to the capsular ligament, and yet attended with *inversion of the limb*, which is by no means easy to account for. In the case which Sir Astley Cooper mentions of Mr. Langstaff's, in the preceding note, Mr. Guthrie tells us that the limb was in the first instance everted, and subsequently turned inwards when the patient began to use it. In a case attended by Mr. Guthrie, the limb which was the first day turned outwards as usual, suddenly turned inwards, and continued to do so for several weeks, giving Mr. G. considerable annoyance lest he had mistaken the case. And in a case of Mr. Stanley's, in which, after death, the fracture was found entirely within the capsule, the limb was inverted, so that the case was mistaken for a dislocation, and the repeated extensions made for the purpose of reducing it produced so much constitutional irritation, that the man died. In this case a portion of the fibrous and synovial membrane on the anterior side of the neck of the bone had escaped laceration. — See also Case LXXXVII. — *Ed.*

pain in this accident is felt in the upper and inner part of the thigh, opposite to the insertion of the iliacus and psoas muscles into the trochanter minor, or sometimes just below this point.

Degree of motion. — Perfect extension of the thigh may be easily effected, but flexion is more difficult, and somewhat painful; and its degree depends upon the direction in which the limb is bent; for if the flexion be outwards, it is accomplished with but little comparative suffering; but if the thigh be directed towards the pubes, the act of bending the limb is with difficulty accomplished, and is attended with greater pain; and this motion is easier or more difficult in proportion as the neck of the bone is shorter or longer.

Situation of the trochanter major.—In this accident the trochanter major is drawn upwards towards the ilium, but the broken neck of the bone attached to the trochanter is placed nearer the spinous process of the ilium than the trochanter itself, in which situation it afterwards remains; and this alteration of position makes the trochanter project less on the injured side, because it is no longer supported by the neck of the bone, as in its natural state, but rests in close apposition with the edge of the acetabulum, and is, consequently, much more concealed than usual. But when the muscles waste from the duration of the injury, it can be distinctly felt upon the dorsum ilii. The degree of the projection of the trochanter will be, of course, proportioned to the length of the fractured cervix attached to it.

Appearance in the erect position. — If doubt exist of the nature of the accident, let the patient be directed to stand by his bed-side, supported by an assistant, and to bear his weight upon the sound limb; the surgeon then observes the shortened state of the injured leg; the toes rest upon the ground, but the heel does not reach it; the knee and foot are everted; and the prominence of the hip is diminished. The least attempt

to bear upon the injured limb is productive of pain, which seems to be occasioned by the tension of the psoas, iliacus, and obturator externus muscles, as well as by the pressure of the broken neck of the bone against the interior surface of the capsular ligament.

Crepitus.—A crepitus like that which accompanies other fractures might be expected to occur in this accident, but it is not discoverable when the patient rests on his back with the limb shortened; if, however, the leg be drawn down, so as to bring the limbs to the same length, and rotation be then performed, the crepitus will be observed, as the broken ends of the bone are thus brought into contact; but the rotation inwards most easily detects the fracture. When the patient is standing on the sound leg, with the fractured limb unsupported, by rotating it inwards, the crepitus will sometimes be perceived, as the weight of the limb then brings the broken bones nearer in apposition.*

Women are much more liable to this species of fracture than men: we rarely in our hospitals observe it in the latter, but our wards are seldom without an example of it in the aged female. The more horizontal position of the neck of the bone, and the comparative feebleness of the female constitution, are the probable reasons of this peculiarity.

To the circumstances I have already mentioned, as strongly characterizing this accident, must be added the period of life at which it usually occurs; for the fracture of the neck of the thigh-bone within the capsular ligament seldom happens but at an advanced period of life, whilst the other fractures which I have to describe happen at all periods: and hence has arisen the great confusion with respect to the nature of this injury; for we find that surgeons of the highest character have confounded fractures external to the capsular ligament with those

* Another strong diagnostic mark of this accident may be ascertained by desiring an assistant to make extension of both limbs, and simultaneously rotate them, when the surgeon, by placing his hands upon the trochanters, will perceive that they move in the arcs of different circles, that on the injured side rolling on its own axis, while the healthy trochanter describes an arch of which the neck forms the radius: and, further, it will be found that the patient cannot raise the whole limb from the bed, in consequence of the thigh-bone having lost its *point d'appui* in the acetabulum; nor can he sit up in bed, but in attempting to do so is unable to bring the body to a right angle with the thigh, but only to one of about forty-five degrees.—*Ed.*

which are within the articulation, and mention the latter as occurring at a period of life in which they rarely happen. It has been also said, that in early life these bones will readily unite, an assertion which I notice only to show the confusion which has arisen on this subject,—a confusion of the fracture external to the capsule in young persons, with the fracture internal to the capsule in the old.

Old age, however, is a very indefinite term, for in some it is as strongly marked at sixty as in others at eighty years. That regular decay of nature which is called old age, is attended with changes which are easily detected in the dead body; and one of the principal of these is found in the bones, which become thin in their shell, and spongy in their texture; hence the light soft bones of old persons may be cut with a pen-knife, with which we are incapable of making any impression on those of adults. The neck of the thigh-bone in old persons also often undergoes an interstitial absorption, by which it becomes shortened,

*

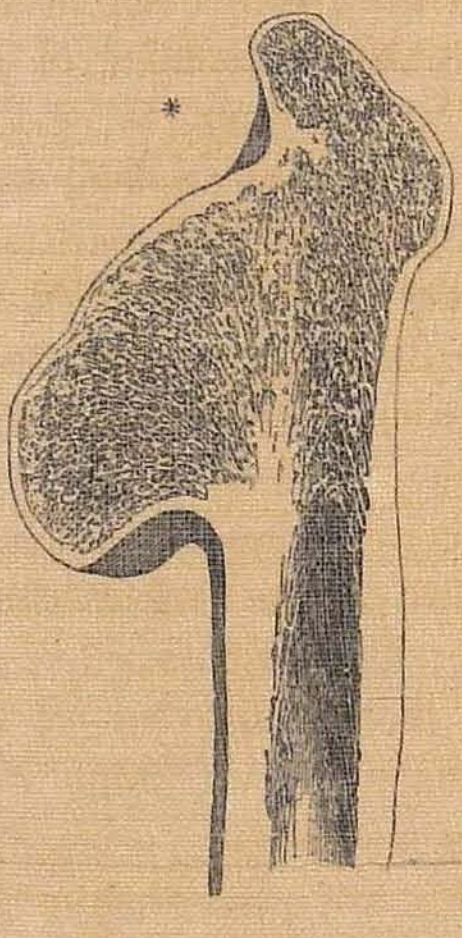

†

* This figure shows the greatest descent of the neck of the thigh-bone which I ever saw.

† This figure shows an altered state of the neck of the thigh-bone from disease, that might be mistaken for united fracture.

altered in its angle with the shaft of the bone, and so changed in its form as to give an idea, upon a superficial view, that it has been the subject of fracture, thus leading persons into the erroneous supposition that the bone has been partially broken and reunited; but it requires very little knowledge of anatomy to distinguish in the skeleton the bone of advanced age from that of the middle period of life.

The age at which fractures of the neck of the thigh-bone within the capsular ligament generally occur, is a most important consideration; and as it is one on which the practice to be pursued by the surgeon very much depends, I shall take the liberty of making the following statement.

I have now been thirty-nine years connected with St. Thomas's and Guy's Hospitals, and for thirty years have enjoyed no inconsiderable share of the surgical practice of London. In the two hospitals there are 1050 patients; and I believe eight cases of fracture of the upper part of the thigh-bone occur in each year; but in order to avoid exceeding the average number, I will consider them only as five per annum; thirty-nine multiplied by five produce one hundred and ninety-five; adding to these one case only in each year, in my private practice of thirty years, they will collectively amount to two hundred and twenty-five cases; now, in that time I have only known *two cases* of fracture of the neck of the thigh-bone within the capsular ligament *occur under fifty years of age;* one was in a patient aged thirty-eight, who had an aneurism of the iliac artery; and the other was kindly shown to me by that excellent anatomist and surgeon, Mr. Herbert Mayo.*

This fracture, then, rarely occurs under fifty years of age, and dislocation seldom at a more advanced period, although there are exceptions to this rule; for, as I just observed, I have myself once seen the fracture at thirty-eight years af age, (but it was very oblique,) and a dislocation of the thigh at sixty-two; but between fifty and eighty years is the period at which the fracture most usually occurs, for, from the different state of the bone, the same violence which would produce dislocation in the adult, occasions fracture in old age. But when dislocation does occur between sixty and seventy years, it is in persons whose

* To these must be added Mr. Stanley's case, in a boy aged eighteen, reported in Med.-Chir. Trans. vol. xviii.—*Ed.*

constitutions are particularly strong, and in whom age has not produced those changes in the bones which I have already spoken of.

Causes.—That this state of bone in old age tends much to the production of these fractures, is shown by the slight causes which often occasion them. In London the accident most frequently occurs when persons, walking on the edge of the elevated foot-path, slip upon the carriage pavement; though the descent be only a few inches, yet, being sudden and unexpected, and the force acting perpendicularly, with the advantage of a lever in the cervix, it produces a fracture of the neck of the thigh-bone; and as a fall is the consequence, the fracture is imputed, by ignorant persons, to the fall, and not to its true cause. Other trivial accidents may also produce this fracture. I was informed by a person, that being at her counter, and suddenly turning to a drawer behind her, some projection in the floor caught her foot, and prevented its turning with the body, by which the neck of the thigh-bone became fractured. A fall upon the trochanter major will also produce it; but I have dwelt particularly on the *slight* causes by which it is occasioned, that the young surgeon may be upon his guard respecting it, as he might otherwise believe that an injury of such importance could scarcely be the result of a slight accident, and that excessive violence is necessary to break the neck of the thigh-bone; but such an opinion is as liable to be injurious to his reputation as the error of confounding this accident with dislocation.

Union of this Fracture.—Much difference of opinion has existed upon the subject of the union of the fractured neck of the thigh-bone. It has been asserted that these fractures unite like those of other parts of the body; but the dissections which I made in early life, and the opportunities I have since had of confirming these observations, have convinced me that fractures of the neck of the thigh-bone, of the patella, olecranon, condyles of the os humeri, and of the coronoid process of the ulna, *generally* unite by ligament, and not by bone. This principle I taught in my lectures for thirty years; and it is a most essential point, as it affects the reputation of the surgeon, as well as a subject of some interest in forensic medicine; for if these fractures unite like those in other parts of the body, the patient who remains lame after the treatment would undoubtedly have a right to

seek redress from the surgeon at the hands of the law. I was called to a case of this fracture, in which, week after week, the medical attendant had been promising union, and the restoration of a sound and useful limb. After many weeks the patient became anxious for further advice: I did all in my power to lessen the erroneous impression which had been made, by telling the patient that she might ultimately walk, although with some lameness; and taking the surgeon into another room, asked him upon what grounds he was led to suppose there would be union; to which he replied he was not aware, but that the fracture of the neck of the thigh-bone would unite like those of other bones of the body: the case, however, proved unfortunate for his character, as this patient did not recover in the usual degree.

Young medical men find it so much easier a task to speculate than to observe, that they are too apt to be pleased with some sweeping theory, which saves them the trouble of observing the processes of nature; and they have afterwards, when they embark in their professional practice, not only every thing still to learn, but also to abandon those false impressions which hypothesis is sure to create. Nothing is known in our profession by guess; and I do not believe, that from the first dawn of medical science to the present moment, a single correct idea has ever emanated from conjecture; it is right, therefore, that those who are studying their profession, should be aware that there is no short road to knowledge; that observations on the diseased living, examinations of the dead, and experiments upon living animals, are the only sources of true surgical knowledge; and that inductions from these are the sole basis of legitimate theory.

In the examinations which I have made of transverse fractures of the cervix femoris entirely within the capsular ligament, I have only met with one in which a bony union had taken place, or which did not admit of a motion of one bone upon the other. To deny the possibility of this union, and to maintain that no exception to the general rule can take place, would be presumptuous, especially when we consider the varieties of direction in which a fracture may occur, and the degree of violence by which it may have been produced. For example, when the fracture is through the head of the bone, with *no separation of the fractured* ends; when the bone is broken *without its periosteum*

being torn;* or, when it is *broken obliquely, partly within and partly externally* to the capsular ligament, I believe that bony union may take place, although at the same time I am of opinion that such a favourable combination of circumstances is of very rare occurrence.† Much trouble has been taken to impress the minds of the public with the false idea, that I have denied the *possibility* of union of the fracture of the neck of the thigh-bone; and therefore I beg at once to be understood to contend for the principle only, that I believe the reason that fractures of the neck of the thigh-bone do not unite is, *that the ligamentous sheath and periosteum of the neck of the bone are torn through*, that the bones are consequently drawn asunder by the muscles, and that there is a want of nourishment of the head of the bone; but I can readily believe, that if a fracture should happen without the reflected ligament being torn, that as the nutrition would continue, the bone might unite; but the characters of the accident would differ; the nature of the injury could scarcely be discerned, and the patient's bone would unite with little attention on the part of the surgeon. (*Vide* Case LXXXVI.)

In proof of the correctness of my opinion, I enumerated in the early editions of this work forty-three specimens of this fracture in different collections in London, which had not united by bone. At the present day, these might be multiplied were it necessary.

Such has been the accumulated evidence of the want of power of the neck of the femur to unite by bone in my practice of forty years, during which period I have seen but two or three cases

* Thus, in a case examined by Mr. Stanley, there was a complete solution of continuity of the neck of the bone, but the periosteum and ligament were altogether uninjured. — Med.-Chir. Trans. vol. xiii. Moreover, in three cases narrated by Mr. Colles in the Dublin Hospital Reports, vol. ii. p. 339, the whole diameter of the bone was actually not broken through. The following is one example:—No. VII. "The fracture was transverse, and close to the head of the femur. The capsular ligament was very much thickened, and its internal surface coated with coagulated lymph. The fracture, however, was incomplete; for the external bony coating of the neck of the femur remained unbroken for nearly half the circumference of the bone at its posterior part, and was reduced to the softness and whiteness of cartilage. To the internal surface of this unbroken portion adhered many bony fragments of different sizes, which by the violence of the fracture appeared to have been torn away from the reticular substance of the bone, retaining their connexion with this coating."—*Ed.*

† In Mr. Cross's account of his visit to the French Hospitals, some interesting matter upon this subject will be found.

which militate against this opinion, for many of the preparations which have been brought for my inspection as specimens of united fractures of this part, have proved to be nothing more than the result of the changes concomitant with old age, and in many of them the two thigh-bones of the same subject had undergone the same alteration in texture and in form.

CAUSE OF THE WANT OF UNION.—Having thus explained what is the common result of these cases in relation to their want of union, I shall now proceed to state the reasons which may be assigned for the absence of bony union in the transverse fracture of the neck of the thigh-bone within the capsular ligament.

The first reason is the want of proper apposition of the bones :



* This figure shows a section of the head and neck of the thigh-bone, the neck in a great measure absorbed.

† The four next figures show the ordinary effects of removing a portion of the radius from dogs.

‡ In this figure the ulna had been fractured likewise, and a portion of the callus projected into the space between the extremities of the radius.



for if in any part of the body the extremities of a broken bone be kept much asunder, ossific union will under ordinary circumstances be prevented.

In a boy, who had a compound fracture of the tibia, without the fibula being broken, and who had the protruded end sawn off, the two extremities were prevented from coming in contact by the fibula, and union never occurred. My friend, Mr. Smith, an excellent surgeon, at Bristol, had a similar case under his care, in which a portion of the tibia having been sawn off, the fibula, remaining whole, prevented ossific union.†

* Fracture of the radius and ulna; ligamentous union of the latter.

† The particulars of the case were as follow: — The boy was admitted into the Bristol Infirmary for disease of the tibia; and the diseased portion not exceeding more than from two to three inches in length, that part of the bone was removed by the saw. In a month the limb had acquired so much firmness, that the boy was permitted to walk about the ward, which he was able to perform tolerably well, and in six weeks no doubt was entertained that ossification had taken place in the uniting substance; at this time he sickened with the small-

This fact is easily seen by experiments on animals: I sawed seven-eighths of an inch of the radius from a rabbit, and the ends of the bones were not united to each other, but only to the ulna. I also sawed off the extremity of the os calcis of a rabbit, and suffered it to be drawn up by the action of the gastrocnemius muscle, and it united only by ligament.

The following communication is from Mr. Benjamin Bell, of St. Andrew's Square, Edinburgh, and illustrates want of apposition as a cause of non-union of bone.

CASE LXXXV.—June, 1822. William Coulthard, aged thirty-five, of a plethoric habit, a miner, was stemming a bore, preparatory to blasting a rock, when the powder inflamed, in consequence of the friction, and exploded, giving rise to the following accident:—One portion of the rock struck him in the perinæum, and occasioned a compound fracture of the tuberosity of the left ischium, which was followed by profuse hæmorrhage. Another portion of the rock came in contact with the left leg, about four inches below the knee, and shattered the tibia and fibula. Four large loose pieces of bone were extracted, by Mr. Fox, surgeon, of Whitehaven, immediately after the accident. These portions, when united, formed about *six inches* of the entire cylinder of the tibia. The sides of the wound were then drawn together, and retained "in situ" by adhesive plasters. The limb was placed in a proper position, and secured by pads and wooden splints. In a short time the wound in

pox and died.—Upon examination, the edges of the extremities of the tibia were found absorbed and rounded, and on the inferior portion a bony callus had formed, about three quarters of an inch in extent; no ossific matter was discoverable in the greater part of the space originally occupied by the diseased bone, but a tough though thin ligamentous band extended from the superior to the inferior portion of the tibia.—*See Medical Records and Researches.*

the leg healed up; three months, however, after it had healed, an abscess formed, and another small portion of bone came away, probably a part of the fibula. The wound healed again without any untoward symptom.

The day on which I saw him (July 22nd, 1823), the leg in which the injury had occurred appeared to be about two inches shorter than the other. A large cicatrix occupied the fore and middle part of the shin; the patient could extend the leg and stamp on the floor with considerable force; the muscles were plump and firm; but the leg was to a certain extent flexible, and could be slightly bent by the hands in four different directions: backwards, forwards, to the right and to the left, on seizing it below the knee (above the fracture), and at the ankle. He suffered no pain, and permitted the limb to be freely handled, but could not, at that time, bear the whole weight of the body upon it. It seemed to me as if the space between the two ends of the fractured bones had been filled up with a sort of ligamento-cartilaginous matter, resembling that found in cases of fracture of the neck of the femur internal to the ligament, or in that occurring in ill-treated cases of transverse fracture of the patella. Whether that conjecture be right or not, it is difficult to determine.

The neck of the thigh-bone when broken, is placed under similar circumstances; for, by the contraction of the muscles, it is no longer in apposition with the head of the bone, and is, therefore, prevented from uniting; if this, however, were the only obstacle, it might be argued that the retraction of the thigh-bone could be prevented by bandaging and extension, the truth of which cannot be denied; but it is scarcely possible, even for a few hours, to preserve the limb in exact apposition, as the patient, on the slightest change of posture, produces instant retraction, by bringing into action those powerful muscles which pass from the pelvis to the thigh-bone.

So in fractures of the patella, although we often do all in our power to prevent retraction of the muscles, yet it very rarely happens that we are able to maintain a complete approximation of the bones.*

* Yet it cannot be said that separation of the fractured extremities of a bone, or that the removal of a portion will *always infallibly* prevent union; because cases have occurred, in which after the removal of considerable portions of

A second circumstance which prevents the bony union of these fractures, is want of pressure of one extremity of the broken neck upon the other, even though the limb preserves its length, and the fractured parts are consequently not much displaced. This want of pressure may arise in some degree from the excessive secretion of serous synovia which follows the accident; but principally from the action of the muscles which separate the broken surfaces. The influence of pressure in expediting bony union is well exemplified by the fact, that if two broken bones overlap each other, a superabundant formation of callus occurs on the side on which they are pressed together, whilst little or no change takes place on the other side. So also we find that, if the ends of bones be drawn from each other by the action of muscles, as sometimes happens in fractures of the os femoris, tibia, os humeri, radius and ulna, union is not effected until the surgeon, by a strong leathern bandage tightly buckled around the limb, compels the bones to press upon each other, and thus support the necessary inflammation for the production of ossific union. When a transverse fracture occurs amidst muscles, those which are inserted into the fractured part of the bone have generally a tendency to keep the extremities of the bones together, with some few exceptions; but when a fracture occurs, as has been already stated, in the neck of the thigh-bone, the muscles have only an influence upon one portion of the fractured bone; and this influence serves to draw one part from the other.

The third reason which may be assigned for the general want of union of this fracture is the almost entire absence of nutrition in the head of the thigh-bone when separated from its cervix, its life being supported by the ligamentum teres, which has only a few minute vessels ramifying from it to the head of the bone. It may be observed that the neck and head of the thigh-bone are naturally supplied with blood by the periosteum of the cervix, and that when the bone is fractured, if, as most frequently happens, the periosteum be torn through, the means of ossific action are, in consequence of such fracture and laceration, necessarily destroyed in the head of the bone. Scarcely any change, therefore, takes place in the head or neck of the bone

bone, both through disease and accident, the deficiency has been filled up by new bone.—*Ed.*

attached to it; no deposit of cartilage or bone similar to that in other fractures is produced; but the deposit which does take place, as may be seen in the plates of fracture of the neck of the thigh-bone, consists of ligamentous matter covering the surface of the cancellated structure, together with little patches like ivory on the head of the bone.

The fourth reason which may be assigned for want of union by bone is the natural change of the cervix femoris in old age, the atrophy of its structure which diminishes its power of resistance, as well as its capability of restoration;—together with the general want of constitutional vigour which always accompanies old age.*

The appearances which are found on the dissection of these injuries are as follow:—The head of the bone remains in the acetabulum attached by the ligamentum teres; there are, upon

* There is yet another reason to which due weight should be given. The cellular membrane which surrounds ordinary bones is an important agent in the reparation of fractures. It is the medium through which blood-vessels are supplied to the periosteum, and it is the seat of a copious effusion of adhesive lymph, which lymph becomes organized and ossified, and constitutes the provisional callus which unites the fracture. But in fractures of the neck of the thigh-bone, the fracture is separated from the surrounding cellular tissue by the capsular ligament, and therefore the union cannot be effected by a provisional callus. Old age may also be considered as a cause of non-consolidation of the neck of the thigh-bone; for not only is there that difficulty of reparation inseparable from the advanced period of life at which the fracture occurs, but also that peculiar change which had taken place in the neck of the bone before the accident happened, rendering it impossible to conceive how under such circumstances re-union is to be expected, when in continuity, the neck of the thigh-bone had not vitality enough to maintain its natural integrity. I believe, therefore, it is a law of nature, the result of organization, which leads to a ligamentous union, and not the neglect of mechanical means, which prevents ossific consolidation in these cases, for it appears that callus is not formed in those situations where its presence would interfere with the motions of a joint. What would be the effects of a mass of callus protruding on the inner surface of a fractured skull? And is it not easy to see that the formation of callus in or near joints would tend to destroy the function of those joints? What degree of useful motion would remain in the knee or elbow if both surfaces of a fractured patella or olecranon threw out a projecting callus? We may say, therefore, that the cervix femoris is from its structure incapable of uniting by callus, like ordinary bone; and that, even if it were, the want of pressure and adaptation of the broken surfaces, the want of nutrition in the upper fragment, the previous atrophy of the part broken, and the age and debility of the patient, would be highly unfavourable for the union.—*Ed.*

parts of the head of the bone, very small white spots like ivory; the cervix is sometimes broken transversely, at others with obliquity. The cancellated structure of the broken surface of the head of the bone and of the cervix is hollowed by the occasional pressure of the neck attached to the trochanter, and consequent absorption; and this surface is sometimes partially coated with a ligamento-cartilaginous deposit. The cancelli are rendered smooth by the process of absorption which nature sets up, and portions of bone are sometimes detached, so as to be found floating in the interior of the joint, covered by ligamentous matter, which, however, may unite them to the ends of the bone; but these pieces do not act as extraneous bodies, so as to excite inflammation, and thus produce their discharge, any more than those loose portions of cartilages which are found so frequently in the knee, and sometimes in the hip and elbow-joints. With respect to the neck of the bone which remains attached to the trochanter major, the most remarkable circumstance is, that it soon becomes in a great degree absorbed, leaving but a small portion of it remaining; its surface becomes of a yellow colour, and extremely smooth, if the bones have rubbed against each other. Some ossific deposition I have seen manifested around this small remaining part of the neck of the bone, and upon the trochanter major and thigh-bone below it, in several examples of this fracture. We do not, however, observe the same process of reparation as in other bones, but a ligamentous, instead of an ossific union.

The capsular ligament enclosing the head and neck of the bone becomes much thicker than natural, but the synovial membrane undergoes the greatest change from inflammation, being very much thickened, not only upon the capsular ligament, but also upon the reflected portion of that ligament upon the neck of the bone, as far as the edge of the fracture.

Within the articulation is found, in recent cases, a large quantity of serous synovia; by which term I mean to express that the synovia is less mucilaginous, and contains more serum than usual, mixed with a small quantity of blood; this fluid, by gradually extending the ligament, separates for a time one portion of bone from the other: it is produced by the inflammatory process, and becomes absorbed when the irritation in the part subsides. I do not know the exact period at which this change

takes place, but I have seen it in the recent state of the injury. Into this fluid is poured a quantity of ligamentous matter, by the adhesive inflammation excited in the synovial membrane, and flakes of it are found proceeding from the internal surface of that membrane, uniting it to the edges of the fractured surfaces. Thus the cavity of the joint becomes distended, in part by an increased secretion of synovia, and in part by the solid effusion which the adhesive inflammation produces. The membrane reflected on the cervix femoris is sometimes separated from the fractured portions, so as to form a band from the fractured edge of the cervix to that of the head of the bone; bands also of ligamentous matter pass from the cancellated structure of the cervix to the head of the bone, serving to unite, by this flexible material, the one broken portion of bone with the other.

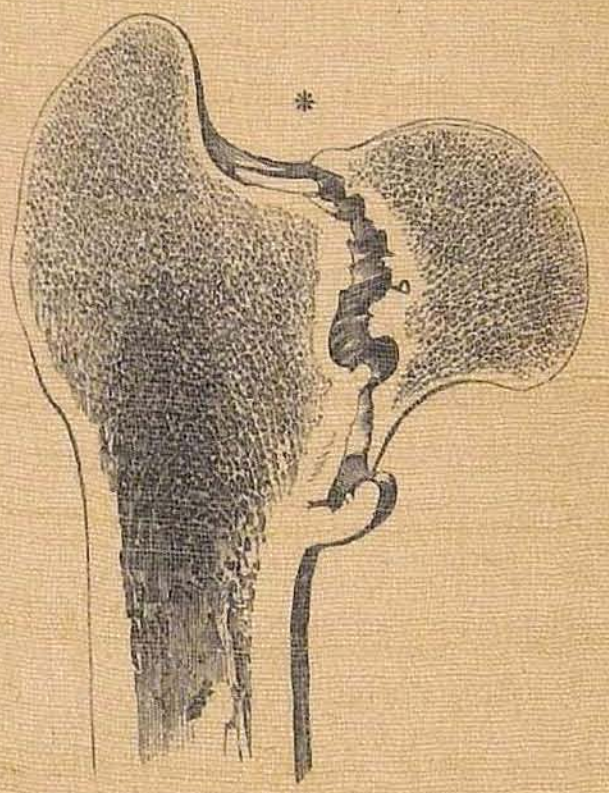

The trochanter is drawn up, more or less, in different accidents; and in those cases in which it is very much elevated, I have known a considerable ossific deposit take place upon the body of the thigh-bone, between the trochanter major and the trochanter minor. A similar deposit sometimes is found on the outer surface of the capsular ligament.† When the bone has been macerated, its head is much lighter and more spongy than in the healthy state, excepting on those parts most exposed to friction, where it is rendered smooth by the attrition, which gives it a polished surface.

* This figure represents a fractured cervix femoris, removed by Mr. Mayo from a patient between thirty and forty years of age, who lived nine months after the accident. The projection of the trochanter minor prevented much shortening of the limb.

† Mr. Langstaff gives the following account of a dissection, in Med.-Chir. Trans. vol. xiii. p. 511: "The cellular or external surface of the capsular ligament surrounding the inferior part of the joint is converted into osseous matter of considerable density, which had united to a large process of bone, formed between the two trochanters, and there was a kind of joint produced between the trochanter minor and the bone on the capsular ligament."—*Ed.*

These, then, are the usual appearances on dissection; but there are two preparations in the Royal College of Surgeons in London, which have been sent as specimens of union by bone of the cervix femoris; but as I may be thought prejudiced in favour of the opinion I have advanced, I shall give that of an excellent anatomist whose loss we have to deplore. Mr. Wilson says, "*I have examined very attentively these two preparations, and cannot perceive one decisive proof in either, of the bones having been actually fractured.*"

Mr. Stanley, for whom I have great respect, both as an anatomist and a surgeon, has met with the appearance of fracture in the neck of each thigh-bone, in the same subject. I do not mean to deny the possibility of the necks of both thigh-bones in this subject having been fractured, because that point can only be determined by the history of the accident, and by a very careful and accurate examination of several sections of the bones; but I can show that similar effects are produced by disease. And I proceed to speak of certain changes often occurring in the neck of the thigh-bone, which have been mistaken for united fractures.

The neck of the thigh-bone in adult persons of middle age, has a close cancellated structure, and is covered with a shell of considerable thickness; but in old subjects, the cancellated

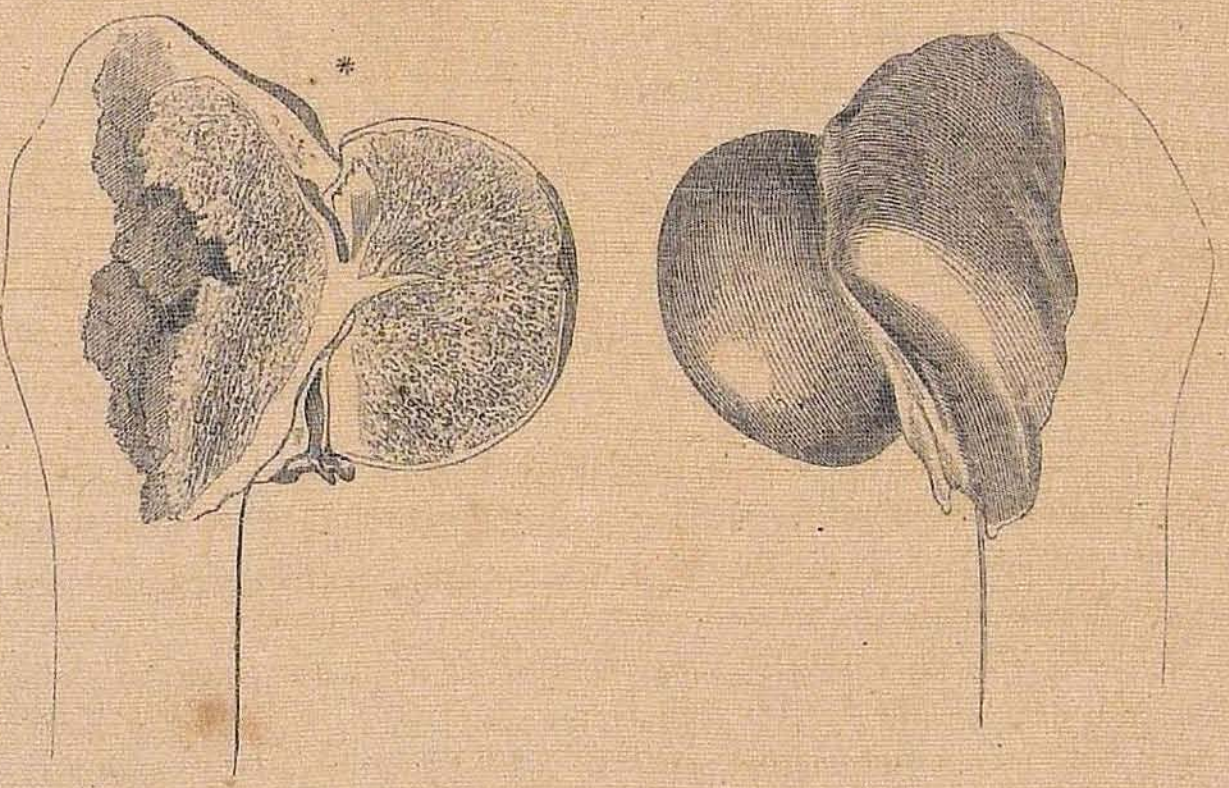

* The reader will not fail to notice the fidelity with which the artist, Mr. W. Bagg, has delineated the minute structure of these bones.

structure degenerates into a coarse net-work, loaded with adipose matter, and the shell which covers it becomes so thin, that when a section is made through the middle of the head and cervix, it is found diaphanous; of this I have several specimens. As the shell becomes thin, ossific matter is deposited on the upper side of the cervix, opposite the edge of the acetabulum, and often a similar portion at its lower part, and thus the strength of the bone is in some degree preserved: this state may be frequently seen in very old persons. Mr. Steel, of Berkhampstead, one of the most intelligent surgeons, and most respectable men I know, gave me the thigh-bone of a person thus altered, whose age was ninety-three.

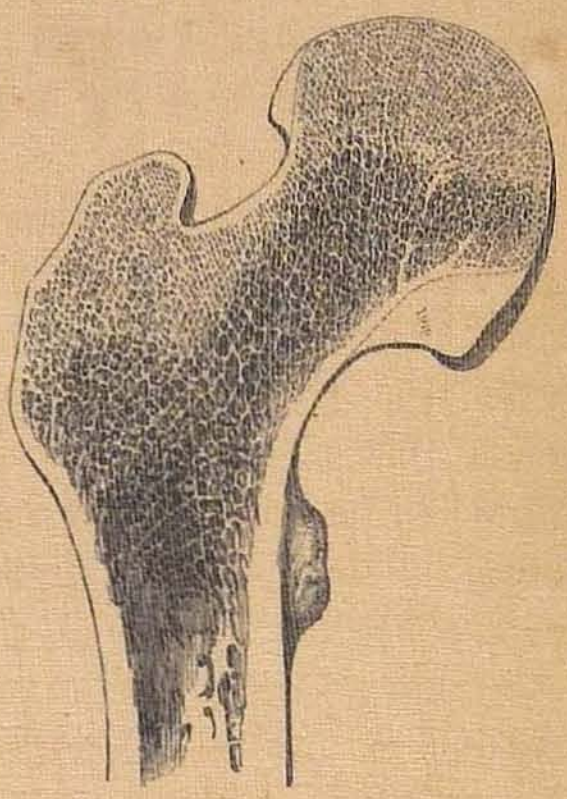

When the absorption of the neck proceeds faster than the deposit on its surface, the bone breaks from the slightest causes, and this deposit wears so much the appearance of an united fracture, that it might easily be mistaken for it. Before the bone thus alters, we sometimes meet with a remarkable buttress shooting up from the shaft of the bone into its head, giving it additional support to that which it receives from the deposit of bone upon its external surface. But another change is also produced from disease, of which the following is the history, and which directly applies to the subject before us.

Old bed-ridden and fat persons (generally females) often used to be brought into our dissecting-room with some of their bones broken (and more frequently the thigh-bone than any other) in being removed from the grave. If the cervix femoris of such persons be examined, it will be found that the head of the bone is sunk down upon its shaft, and that the neck of the thigh-bone is shortened, so that its head is in contact with the shaft of the bone opposite to the trochanter minor; and at the part at which the ligament is inserted into the neck of the bone,

the phosphate of lime is absorbed, and a ligamento-cartilaginous substance occupies its place; either extending entirely through the neck of the bone, or partially, so that one section exhibits signs of it, and in another it is wanting. The bone, in some cases, is so soft and fragile, both in its trochanter and head, that it will scarcely bear the slightest handling; and the motion of the thigh-bones in the acetabulum is almost entirely lost, so that the persons must have had little use in their lower extremities.

In examining the body of an old subject, very much loaded with fat, in the dissecting-room of St. Thomas's Hospital, I found that the gentleman who had dissected one limb, had cut through the capsular ligament of the hip-joint, and tried to remove the head of the thigh-bone from the acetabulum; but the neck of the bone broke on the employment of a very slight force, and upon a further trial to remove it, the bone crumbled under his fingers. As the other limb was not yet dissected, I requested Mr. South, one of our demonstrators, to remove, with care, the upper part of the other thigh-bone; but although he used great caution in doing it, he could not remove the bone without fracturing the upper part of its shaft; but he succeeded in removing the upper part of the bone, so that it might be preserved; and of this I have given plates.

We have here then a case in which the neck of the bone was absorbed, so that the head was brought in contact with the trochanter; in which, most decidedly, there had not been a fracture, although it had in some parts the appearance of one; and in which the disease occurred in each hip-joint.

Another case of the same kind was examined by Mr. South, which, so far as relates to the softened state of the upper part of the thigh-bone, was similar to the former; the heads were spongy, the necks were shortened, so that there was scarcely any remaining; each trochanter was light in weight, spongy, and very large; and there was little if any motion in either of the hip-joints, so that both limbs appeared, at first sight, as if dislocated upon the pubes.

But the best specimen of this state of the bone is the following, which I preserve with the most assiduous care, and value in the highest possible degree:—I have had for twenty years in the collection of St. Thomas's Hospital, the thigh-bone of an old

person, in which the head of the bone had sunk towards its shaft. I have been in the habit of showing this bone twice a year as a specimen how bones sometimes become soft from age and disease, and from the absorption of their phosphate of lime; and I have frequently cut with a penknife both its head and its condyles, to show this softened state. On sawing through its cervix, the cartilage, deprived of its phosphate of lime, had dried away in several parts, and the appearance was such that a

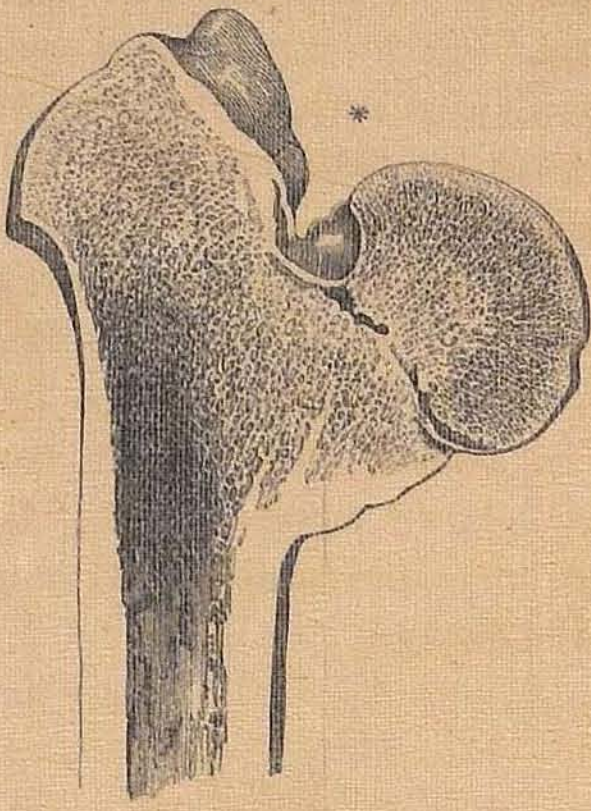

person, ignorant of the change, would have declared it to be a fracture; only, that in some sections the cartilage had taken different directions, and in some the bone was not yet entirely absorbed. We have also in the Museum of St. Thomas's Hospital, a skeleton in which both the thigh-bones, and each os humeri, are, in a subject extremely altered by rickets, divided by similar portions of cartilage, in which no ossific matter exists.

Mr. Sands Cox, of Birmingham, informed me, in the year 1833, that he had examined upwards of fifteen cases of this fracture, and that he had not met with ossific union in one case where the fracture was decidedly within the capsule. He further observes, that he had met with copious deposits of bony matter around the neck and on the base of the head, and thinks that such cases may occasionally be reported as united fractures.

Experiments on Animals.—I have been led to prosecute the inquiry into the pathology of these fractures by experiments upon animals. I found it difficult to succeed in breaking the bone in the direction I wished, and, after a great number of experi-

* This figure shows the changes incident to the neck of the thigh-bone in old age, which might be mistaken for united fracture. The head of the bone is sunk; the neck shortened; the cancelli atrophied, and there is a line in which the bony texture is partially absorbed; and in the recent state, its place was filled by a ligamento-cartilaginous substance.

ments, was successful only in the following instances; the preparations of these I have preserved, and they may be seen in the Museum at St. Thomas's Hospital.

Experiment I.—The neck of the thigh-bone was fractured in a rabbit, on October 28th, 1818; and on December 1st, as the wound had been some time healed, I dissected the animal.

Appearance on dissection.—The capsular ligament was much thickened; the head of the bone was entirely disunited from its neck, but adhered by a new ligamentous substance to the capsular ligament; the broken cervix, which was very much shortened, played on the head of the bone, and had smoothed it by attrition; the head of the thigh-bone had not undergone any ossific change.

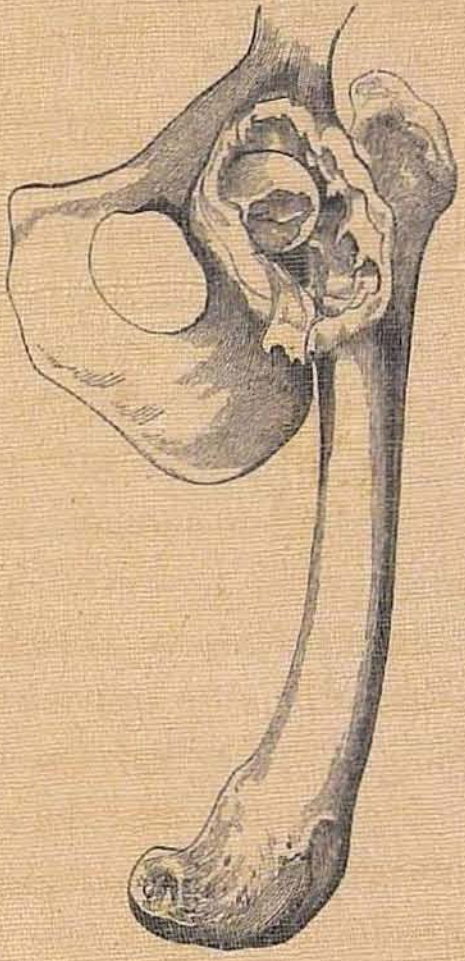

Experiment II.—The neck of the thigh-bone was broken in a dog, November 18th, 1818, and the animal was killed on the 14th of December following.

Dissection.—The trochanter was much drawn up by the action of the muscles, so that the head and cervix femoris were not in apposition. The capsular ligament was much thickened, and contained a large quantity of synovia.

The joint was lined with adhesive matter of a ligamentous appearance, adhering to the head of the bone, which did not seem

to be changed by any ossific process; but the thigh-bone around the capsular ligament, the trochanter major, and the bone a little below it, were enlarged.

We find, therefore, by these dissections, that what appears in the human subject after this accident, takes place also in other animals; and that motion, want of apposition and pressure, with the little ossific action in the head of the bone, under these circumstances, produce a deficiency of bony union, as in man.

The two preparations which I have preserved were the only examples in which the experiment was complete in relation to the transverse fracture; but I have two other interesting preparations derived from these experiments. I also made a great number of others, in which the fractures continued compound; in each of these the head of the bone either became absorbed, or was discharged by ulceration; and I never could succeed in uniting the head to the neck of the bone. I have since divided the neck of the thigh-bone in a dog, and the head of the bone was three-fourths absorbed. By way of contrast I have also divided the bone externally to the capsule, in five instances, and have preserved the bones; the wounds united by adhesion, and every bone has been healed by ossific union: the natural inference is, that fractures within the capsule, do not unite by bone, but that fractures external to it, readily do so. As to the notion that the bearing upon the limb, or its weight, may have influence to prevent union in these animals, I have only to observe, that the muscles become contracted, the limb drawn up, and the animal cannot bear upon it for several weeks.

My friend, Sir B. Brodie, furnished me with the following account of an experiment which he made upon the same subject, which fully confirms my observations.

The tibia of a guinea-pig was broken at the lower end. A month afterwards the animal was killed. On dissection, I found a fracture extending across the tibia, transversely, and so close to the ankle-joint, that it was situated at that part of the bone which is covered by the reflected layer of the synovial membrane. The synovial membrane itself, and the ligaments of the joint, appeared to have been very little injured, and the broken surfaces had remained in good apposition; nevertheless, there was not the smallest union of them, either by bone or ligament, and there had been no formation of callus round the fracture.

The bone in the neighbourhood of the fracture had become compact and hard, in consequence of the ossification of the medullary membrane lining the cancelli.

Professor Burns, of Glasgow, had the great kindness to send me the following observations, in the year 1823.

"Permit me to offer my warmest thanks for the pleasure and edification I have received from the study of your late work. I was early led to attend to the process adopted by nature in forming a new articulation in injuries to the hip-joint, by the dissection of a dog which I had when a boy, and which had the hip fractured. Many years afterwards I examined the parts, and found the fragment of the cervix belonging to the head absorbed, the head itself filling the acetabulum; the shaft of the bone expanded, and a new head formed for a new socket, and the whole enveloped in a dense capsule or covering.

"In a fracture of the os femoris external to the capsule, the glutæus medius and minimus seem to act as a cushion to stop the ascent of the end of the cervix, whilst the fragment attached to its head will, perhaps, afford some opposition; but in the fracture within the capsule, the end of the cervix is drawn more freely up under the glutæus medius, and lodged behind the inferior spinous process of the ilium.

"Is this the explanation of the greater shortening in the one fracture than in the other?

"Nothing can better explain the want of ossific union than the principles you have laid down."

The following case of fracture of the neck of the thigh-bone in a horse, was sent me by Mr. Burnard, in the year 1820.

A horse grazing on the side of a remarkably steep hill, fell, and after rolling some way, was precipitated into a hollow stony lane of considerable depth. After the fall the animal was very lame, hopping on three legs, the injured limb being shortened so that it did not reach the ground, and evidently after a time wasted. The farrier who had the care of the animal suspected it to be a dislocation of the hip, and therefore, by means of pulleys affixed to the legs, suspended it to the bough of a tree with the hope of effecting a reduction. This did not succeed, and after the horse had been kept some time longer, in all about four months from the time of the accident without getting better, it was sent to a dog-kennel and killed. Having noticed the

appearance of the animal, and been present when it was suspended, I told the farrier I thought it was a fracture of the neck of the thigh-bone, and some time after, when the horse was killed, he told me that what I had said was right, that the head of the bone was broken off close into the cup, and no more united than at the first moment of the accident. The lower portion of the bone I did not see; but the head of the bone I saw, and in that there was no appearance whatever of any attempt at reunion having taken place. Not having made any notes at the time, the above are, as nearly as I can recollect, all the particulars connected with the case.

Having by experiment ascertained the circumstances I have mentioned, I was next anxious to learn if the head and neck of the thigh-bone would unite under a longitudinal fracture, in part within and in part external to the capsular ligament, in which apposition, contact, and pressure are maintained; and for this purpose I made the following experiment.

Experiment III.—I divided the head, neck, and a portion of the trochanter major of the thigh-bone of a dog longitudinally, by placing a knife on the trochanter major, and striking it down towards the acetabulum through the head of the bone. The animal was killed twenty-nine days after, and the following appearances presented themselves:—

A portion of the trochanter major had been broken off, and was only united by cartilage. The head and neck of the bone, which had been longitudinally broken, were united; the neck by a larger quantity of ossific deposit than that which joined the separated portions of the head of the bone, and so irregularly as to make a beautiful preparation, and show the circumstance most clearly. This bone may be seen in the collection at St. Thomas's Hospital.

Whether the union began in the fracture externally to the ligament, and proceeded inwards, or whether on the whole surface at once, it is impossible to ascertain; but the coalescence was firm, though, as I have stated,

I thought more so at the neck than at the head of the bone. The union in this case is readily explained. Apposition was supported; the vessels of the head of the bone and cervix remained whole; and, therefore, this experiment shows at once why the longitudinal unites, and the transverse, in general, does not.

Thus, then, it appears, that in a longitudinal fracture of the head and neck of the bone *in part external to the ligament*, if the bones be applied to each other, pressed together, and in a state of rest, and the vessels remain, ossific union can be produced; although the ossific deposition is extremely slight when compared with that of other bones.*

Diagnosis. — The fracture of the neck of the thigh-bone may be confounded with the dislocation of the os femoris upon the dorsum ilii; with that into the ischiatic notch; and with that

* I am quite of Sir Astley Cooper's opinion that fractures of the neck of the thigh-bone within the capsular ligament, do not, excepting under peculiar circumstances, unite by bone, and that the exception occurs only when the periosteum and reflected membrane of the neck of the bone has not been torn through, and when, therefore, the fractured extremities are not separated from each other.

I maintain that there are several circumstances tending to prevent the ossific consolidation of a fracture of this part of the thigh-bone, or, in fact, of the articular extremity of any long bone within the synovial capsule.

With respect to the neck of the thigh-bone, a very principal cause of its non-consolidation by bone is the advanced age at which it becomes obnoxious to fracture, through that peculiar change which the part undergoes at this period of life, without any apparent cause; but which renders it incapable of sustaining the superincumbent weight, and even in continuity insufficient to maintain its function; therefore, it may be fairly supposed, when broken, incompetent to set up a restorative action.

The want of surrounding tissues to assist in the reparation of the fractured neck of the thigh-bone is another great cause of the want of union. In the fracture of the shafts of the long bones the surrounding structures all assist in forming the provisional callus, and the temporary consolidation is perfected by them; the permanent union of the fractured bone not being completed until the contraction or shrinking of the provisional callus has brought the fractured ends of the bone into perfect conjunction; a condition which cannot be effected when no provisional callus is formed, as in fractures within the capsular ligaments of joints.

Moreover, so soon as the fractured portions of the neck of the thigh-bone are separated, all supply of blood must be cut off from that portion attached to the head excepting to its articular cartilage, which does not seem capable of maintaining ossific deposition; and hence arises a preventive to ossific union of the

upon the pūbes; as in all these luxations the limb is shorter. From the two former it may be distinguished by the eversion of the foot, and by the mobility of the limb; and from the latter by the ball of the os femoris being felt in the groin in the dislocation on the pubes; otherwise the eversion of the foot in both cases might lead to their being confounded.

The following case was sent me by Mr. Robertson, of Sheerness.

Case LXXXV*. — On the 25th of June 1822, William Darwin, aged sixty-two, a tall athletic convict, of a sanguine temperament, fell with a very inconsiderable violence across a piece of timber in the Dock-yard, his left hip coming in contact with the wood. On rising, he felt an acute pain in the region of the acetabulum, but no other inconvenience, for he walked on board to exhibit himself to the surgery-man. From finding him *ranked up* with the sick of the hulk on my morning visit of the 26th, from his walking on board, and from his own account of the accident, I did not suspect any serious injury of the joint, and treated the case as one of concussion. On the 29th, however, he complained of a very sudden and very agonizing accession of pain, which induced me to subject him to a more critical examination. No evident alteration in the size of either hip could be discerned, but a shortening of

neck of the thigh-bone. And, lastly, let it be remembered that all articulating extremities of the long bones are attached to their shafts or bodies by *epiphyses*, structures which are subjected both during growth and reparation to quite different laws from those which regulate the development and functional power of the osseous system generally.

I do not believe in bony union of the neck of the thigh-bone, where solution of continuity has occurred; and no cases have been published which militate against this opinion. But if the fractured surfaces be not separated, then their consolidation is effected in the same manner as when shafts of long bones have been ultimately brought in contact by the shrinking of a provisional callus; or as flat bones repair from the fractured edges.—*Ed.*

the limb was conspicuous, which was rendered more evident by making him stand on the sound limb; extension removed this difference, but, on being freed from restraint, it again assumed its morbid shape; the knee and foot were everted, and rotation greatly increased his pain.

I removed him to the hospital as a case of fracture within the capsule, but a continued attention for a period of six months to position, (chiefly with the view of restraining the motion of the pelvis, and of securing the limb,) made no other alteration in the symptoms than a gradual diminution of pain. A pair of crutches were given him, he was placed on the invalid list, and remained so till the 26th of December, when he died from general dropsy.

On dissection, the injury proved a transverse fracture of the neck of the femur within the capsular ligament. No species of union had taken place. The upper portion of the fractured bone was retained in situ by the sound ligament; it was tolerably smooth on its surface, but without any ossific deposit; the lower portion very irregular, with several detached pieces of bone adhering to the insertion of the capsular ligament. Between the acetabulum and the portion of bone retained in situ by the ligament, were several small oval-shaped loose cartilaginous substances, apparently fragments of bone. The capsular ligament was partially lacerated, in a line above the trochanter major, and greatly thickened in its insertions.

Case LXXXVI.—Mrs. Powell, aged above eighty years, fell down in the afternoon of the 14th of November 1824. I saw her soon after, and found her complaining very much of pain in the left hip; the limb could be moved in every direction, but this motion produced excessive pain. She was laid on her back with the limb extended, and nothing *was ever done* beyond the application of fomentations for the first few days. I believed there was a fracture of the neck of the thigh-bone, although *the limb remained quite as long as the other, and I could neither perceive a crepitus, nor any altered appearance in its position*, except a slight inclination of the toes outwards. She had more constitutional irritation than I ever observed from a similar accident. She suffered much pain in her hip, and was, in consequence, obliged to take an opiate, but she got very little rest. She generally had much thirst; there was the utmost difficulty in keeping her bowels open, and she had great pain and difficulty

in making water. She had no appetite for common food, and for three weeks appeared so weak that she was under the necessity of taking wine and brandy. For some time all her urine and stools were passed in bed, but not involuntarily, and only because she could not be persuaded to use proper means; in consequence her back became rather sore. Latterly she complained of pain in the abdomen, which was very tender on pressure, and made even the weight of the bed-clothes inconvenient. Her tongue became very dry and brown, and in the last twenty-four hours she was insensible. She died on the morning of the 19th of December, about five.

Examination. — "This took place at seven in the evening. There was some ecchymosis amongst the muscles about the injured part, and in the cellular membrane about the sciatic and anterior crural nerves. The greatest part of the fracture of the neck of the thigh-bone, which was entirely within the capsular ligament, was firmly united. A section was made through the fractured part, and a faint white line was perceived in one portion of the union, but the rest appeared to be entirely bone." Mr. Swan goes on to say — "This beautifully shows the principle which Sir Astley Cooper has advocated, viz. that when the reflected ligament remains whole, and the bones are not drawn asunder, the nourishment to the head of the bone continues, and union will be produced even in the short space of five weeks by only placing the knee over a pillow, and in other respects leaving the case to nature."*

The following case was sent me by Mr. Swan.

CASE LXXXVII. — Mrs. Wheatley, about sixty years of age, fell down in her room. I saw her for the first time on the 24th of December 1822, but the accident happened some days before. The limb was shorter than the other, and *the toes were turned inwards.* The muscles were so rigid that it was with difficulty I bent the limb towards the abdomen, and not without causing great pain. The muscles of the opposite limb were very rigid. She suffered much pain, and lingered until the 3rd of February 1823, when she died.

Examination. — The head of the bone was broken off within the capsular ligament, and only adhered to the shaft by a portion of synovial membrane. There did not appear to be the least

* From Mr. Swan's work on Diseases of the Nerves, p. 304.

attempt at union. The sciatic nerve behind the trochanter was very vascular, and the anterior crural nerve was so in a less degree.

Case LXXXVIII.—A very old female was brought into the dissecting room at St. Thomas's Hospital, whose right limb was everted, and was an inch and a half shorter than the left. Upon dissection the sciatic nerve had the appearance of having been bruised; a small portion of bone was broken off at the insertion of the obturator externus muscle; a similar portion of bone was separated at the upper part of the insertion of the quadratus femoris. The capsular ligament was torn at the part at which it is covered by the iliacus internus muscle. The capsular ligament being further opened, was found to contain a small fragment of bone, and it was filled with adhesive ligamentous matter, poured out by inflammation, and adhering to the internal surface of the capsular ligament, to the remnants of the cervix femoris, and, slightly, to the head of the bone. The cervix femoris had been broken close to the head of the bone, and entirely within the capsular ligament. The head of the femur remained in the acetabulum unaltered, excepting that its cervix was partly covered with ligament. The neck of the bone was so absorbed, that the portion of it which remained was smaller than the trochanter minor. Its cancellated structure was covered by the effused ligamentous matter. There was not the slightest appearance of ossific union, or even of bony deposit, although this injury must from the changes produced by inflammation, have happened from two to three months before death. When I raised the thigh-bone one inch and a half, it was prevented from rising higher by the lower portion of the glutæus minimus, and by the capsular ligament.

Case LXXXIX.—A young man, in his eighteenth year, fell from the top of a loaded cart upon his right hip, the injury of which was attended with the following symptoms. He was wholly unable to move the limb, and suffered great pain when it was moved by another person. The thigh was bent to a right angle with the pelvis, and could not by any means be extended. Abduction of the thigh was difficult. The limb was everted, at first slightly, afterwards in a greater degree. There was *no shortening*, but rather an apparent lengthening of the limb in the erect posture, probably from the obliquity of the

pelvis. No crepitus could be felt during any movement of the limb. The soft parts about the hip were considerably swollen.

The case was considered doubtful, but more probably a dislocation than a fracture; forcible extension was therefore made with the pulleys, and the head of the bone was moved in various directions, so as to restore it to its socket.

Three months after the accident the patient died of small-pox. On examination of the body, the capsular ligament of the injured hip was found entire, but a little thickened. The ligamentum teres was uninjured. A line of fracture extended obliquely through the neck of the femur, and entirely within the capsule. The neck of the bone was shortened, and its head approximated to the trochanter major. The fractured surfaces were in the closest apposition, and firmly united nearly in their whole extent by bone. There was an irregular deposit of bone upon the neck of the femur, beneath its synovial and periosteal covering, along the line of the fracture.*

Treatment.—With respect to the treatment of fractures of the neck of the thigh-bone within the capsular ligament, various are the means to which I have had recourse, and which I have known resorted to by others, for the purpose of producing union in this accident, but all without avail.

One mode has consisted in placing the fractured limb over a double inclined plane, by which a regular and constant extension is preserved; and, by raising the planes at the knee, this extension may be increased to any degree that the surgeon may require, or the patient can bear; at the same time, a bandage is applied around the pelvis and upper part of the thigh, to bring the neck of the bone, as much as possible, in approximation with the head from which it has been separated; and this extension, with pressure, has been steadily preserved for three months. With respect to the patient's body, it has been placed at an angle of forty-five degrees.

A second method has consisted in placing a board at the foot of the bed, upon which the foot of the sound limb is supported, so as to prevent the descent of the body in the bed; the other limb is then extended as much as possible, and a weight, appended

* Abridged from Mr. Stanley's paper in the Med.-Chir. Trans. vol. xviii. p. 256. This case corroborates Sir Astley Cooper's opinion respecting the mode of reparation of fractured neck of the thigh-bone when neither the capsular ligament or periosteum are torn.—*Ed.*

to the foot, is suffered to hang through a hole in the board over the end of the bed, in order to support the extension with regularity and steadiness for several weeks.

In a third method, the patient has been placed in bed with both limbs extended to the utmost possible degree, and then the two feet have been bound together by a roller, passed from the foot on the injured side under the sound foot, so as to make one limb steadily preserve the extension of the other. Or this may be effected by an iron plate affixed to the shoe on the sound foot, with a screw passed through a hole in the plate, and having a band fixed to the other foot, which may be tightened by turning the screw, and the foot, by this means, be kept constantly extended.

A fourth mode employed for this purpose has been the application of Boyer's splint, with the intention of extending the limb from the pelvis; but this splint, though it answers well for fractures of the thigh under ordinary circumstances, has a tendency to prevent union in those fractures which occur at the upper part of the bone, by the pressure of its band upon the inner and upper portion of the thigh.

Mr. Hagedorn has recommended a machine for fractures of the neck of the thigh-bone, which is very ingenious in its construction. It consists of a long splint to extend from the hip to the foot, which is to be firmly applied, by means of proper straps, to the sound limb; at the bottom of this is fixed a broad foot-board, perforated with a sufficient number of openings to receive the bands, by means of which both feet are to be securely fixed to it; these bandages are attached to a kind of leathern gaiter, made to lace tight round the ankle, and the upper part of the splint is kept close to the hip by means of a broad bandage carried round the pelvis. By this machine the extension of the limb is tolerably well effected, so long as the patient can be kept still; but a displacement of the bones will invariably be the consequence of every motion which the evacuation of the fæces will necessarily require. I am never so wedded to any opinion as to be prevented from trying, or from wishing others to employ, every means which appear plausible or ingenious; and, therefore, I think that this instrument ought to have a fair trial.

Mr. Earle is of opinion, that these cases may be cured by long continued attention in keeping the parts at perfect rest. I think

a trial should be made of the bed recommended by Mr. Earle, in his laudable attempt to prevent the lameness and shortening of the limb in cases of fracture within the capsule; which has invariably been the result in those cases I have had an opportunity of witnessing.

But all the means which I have seen used have been found unavailing. I have been baffled at every attempt to cure, and have as yet witnessed only one single example of union in this fracture. I know that some persons still believe in the possibility of this union, by surgical treatment, and that instances of success have been published; but I cannot give credence to such cases until I see that the authors were aware of the distinction between fractures within and external to the articulation.

The following anecdote was related to me by that intelligent surgeon, Mr. Cross of Norwich, who had been attending a hospital on the Continent for some time. One of the surgeons belonging to it observed, "Some of the English surgeons do not believe that we unite fractures of the neck of the thigh-bone; now there is one you shall examine, as the patient is dying." A few days after, the patient died, and the joint was examined, when the bone was found still disunited. The surgeon of the hospital only made a significant shrug of disappointment.

The cases in which union might be produced are two: one, in which the periosteum, covering the neck of the thigh-bone, is not torn through, a circumstance which now and then happens; the other, in which the head of the bone is broken, so that the cervix still remains in the acetabulum: but in neither of these cases will the limb exhibit the shortened state which fracture of the neck of the bone usually produces, and, therefore, the common characters of the accident will be wanting. Even in such cases, I would prefer a ligamentous union, to the confinement and danger of bony union, in regard to the health and life of the person, and, as I believe, to the subsequent use of the joint.

Baffled in our various attempts at curing these cases, and finding the life of the patient occasionally sacrificed under the trials made to unite them, I should, if I sustained this accident in my own person, direct that a pillow should be placed under the limb throughout its length; that another should be rolled up

under the knee, and that the limb should be thus extended until the inflammation and pain had subsided. I should then daily rise and sit in a high chair, in order to prevent a degree of flexion, which would be painful; and, walking with crutches, bear gently on the foot at first; then, gradually more and more, until the ligament became thickened, and the muscles increased in their power.* A high-heeled shoe should be next employed, by which the halt would be much diminished. Our hospital patients, treated after this manner, are allowed in a few weeks to walk with crutches; after a time a stick is substituted for the crutches, and in a few months they are able to use the limb without any adventitious support.

The degree of recovery in these cases is as follows:—if the patient be very corpulent, the aid of crutches will be for a long time required; if less bulky, a stick only will be sufficient; and where the weight of the body is inconsiderable, the person is able to walk without either of these aids, but drops a little at each step on that side, unless a shoe be worn having a sole of equal thickness to the diminished length of the limb. In every case, however, in which there is the smallest doubt whether it be a fracture within, or external to, the ligament, it will be proper to treat the case as if it were external, a fracture which I shall hereafter describe, and which admits of ossific union.

The Editor cannot deny himself the gratification of adding in conclusion the three following testimonies to the truth of Sir Astley Cooper's doctrines, which were sent him in the year 1823, by Mr. Stanley of St. Bartholomew's Hospital, London, by Dr. Alexander Munro of Edinburgh, and Dr. Colles of Dublin. The Editor inserts them unaltered, because he is convinced that the experience of succeeding years has but confirmed the conclusions which Sir Astley Cooper had then drawn from his investigations of nature.

Mr. Stanley says, "We have in the Museum of St. Bartholomew's twelve specimens of fractures in the neck of the thigh-bone; six external to the capsule, and united, and six within the

* The obturator externus muscle and its tendon under these circumstances become excessively increased, so as to support the weight of the body, and the capsular ligament also becomes much thickened. Sometimes the broken neck sinks into the trochanter minor, and thus acquires additional support.

capsule. In three of the latter there is no union, and in the other three there is union by ligamentous matter."

Dr. A. Munro writes thus:—"In answer to your query respecting fracture of the neck of the thigh-bone, I beg leave to inform you, that I have had an opportunity of examining two cases only after death, and in both of these the broken ends of the neck of the bone were united by a substance somewhat like to ligament.

"I have seen several persons who had, during their lives, a fracture of the neck of the bone, but in all of them a bony re-union had not taken place.

"In the catalogue of the Museum which was bequeathed to the University by my father, mention is made of the fracture of the neck of the thigh-bone which had re-united by a bony union. Upon examining the preparation with attention, it appears to me, that there has been no fracture, but a disease in the trochanter major, and that a number of osseous spiculæ have shot upwards within the capsular ligament, giving the appearance of an ill-set fracture.

"There is also a specimen in the Museum of a fracture of the thigh, about four lines beyond the insertion of the capsular ligament, at the root of the trochanter."

And, lastly, Dr. Colles says, "Since the receipt of your letter, I have carefully examined all the specimens of fracture of the neck of the thigh-bone contained in both Museums of our College of Surgeons. In that which is appropriated to the use of the School, I find seven instances of fracture within the ligament; each of these have been described in my paper on this subject, in the Dublin Hospital Reports. Since the publication of that Essay, the conservator of the College Museum has collected five specimens of fracture within the ligament. In this Museum are also four instances of fracture external to the capsular ligament. In the School-Museum are two instances of fracture external to the ligament. Of this latter description of fracture, fewer than one half the number are united by bony union. Of the fractures within the ligament, not one has made a nearer approach to bony union than that described in the paper alluded to. I must say, that I have never yet seen an instance of bony union where the fracture had been within the ligament. We have very many specimens of a disease of the

head and neck of the thigh-bone, which is of frequent occurrence amongst our labouring poor. On this subject I have some idea of writing a paper for the next volume of the Dublin Hospital Reports, and of endeavouring to show that, in all probability, the supposed cases of fracture within the ligament united by bone were merely instances of this disease.

"If you have any wish for them, I shall have great pleasure in sending you sections of some of these cases, which I am certain might be passed upon many surgeons for fracture of the neck of the bone."

SECTION III.

FRACTURES OF THE CERVIX FEMORIS EXTERNAL TO THE CAPSULAR LIGAMENT, AND INTO THE CANCELLI OF THE TROCHANTER MAJOR.

The symptoms of this accident in some respects resemble those of the fracture within the ligament, and they require much attention to distinguish them accurately; but the result is entirely different; for a favourable opinion may be given as to the restoration of the bone by an ossific union.

Symptoms.—In this accident the injured leg is shorter than the other by half to three quarters of an inch; the foot and toe on that side are everted, from the loss of support which the body of the thigh-bone sustains in consequence of the fracture; much pain is felt at the hip, and on the inner and upper part of the thigh; and the joint loses its usual roundness.

Diagnosis.—The distinguishing signs of this accident are,—*First:*—It sometimes occurs at the earlier periods of life; for it happens in the young, and in the adult *under fifty years of age;* I certainly have known it at a later period, when it often proves fatal; but if the above symptoms are seen at any age under fifty years, there will be generally found a fracture external to the capsular ligament, and capable of ossific union. A surgeon, therefore, called to the bed-side of a patient who has injury to the upper part of the thigh-bone, if he finds the age of the patient to be under fifty, will, with very few exceptions, be warranted in pronouncing it either a fracture just external to the ligament, or one through the trochanter major. But I also mention that *both fractures occur in age,* and, there-

fore, no conclusion can be drawn between the two, in advanced age, but by the most careful examination.

Secondly :—These cases may be in some measure distinguished by the severity of the accident which produces them; for whilst the internal fracture may happen from very slight causes, this, on the contrary, is always produced either by severe blows, or by falls upon the edge of some projecting body, as against the edge of the curb-stone, or from the pressure of laden carriages passing over the pelvis. My experience has taught me, that a very slight accident generally occasions the fracture within the capsule, and a violent blow, or fall, the other: the first is an accident upon which the fall often succeeds, the other is generally the consequence of that fall; many of those within the capsule which I have witnessed, were produced by the person's merely slipping from the curb-stone to the road-way,—not that I mean to deny, that a fall will, and does occasionally, produce a fracture within the capsule, or that in a very old person, a fracture may occasionally happen in any part of a bone, from a slight cause compared with that which produces it in the young.

Thirdly :—It may be generally known by the crepitus which attends it upon *slight* motion, and this arises from the less retraction of the limb.

Fourthly :—Great ecchymosis often attends it, which does not generally happen in the fracture within the capsule.

Fifthly :—Swelling and tenderness to the touch quickly succeed upon the upper part of the thigh, from the inflammation which this injury produces.

Sixthly :—This accident is generally marked by much greater severity of suffering than the fracture within the ligament, slight motion producing excruciating pain, which does not happen in an equal degree in the fracture within the ligament.

Seventhly :—There is a high degree of irritative fever, and many months elapse before the patient recovers any use of the limb.

Dissection.—Upon dissection of these cases, the seat of the fracture is found to vary very much in different examples, being more or less complicated, but it is external to the capsular ligament, and the fracture is placed at the neck of the root of the thigh-bone; the trochanter is split, and the neck of the bone is received into its cleft. The trochanter major is often broken into several portions.

We have few opportunities of dissecting these cases in the young, because they recover from the accident; and, therefore, the examination of them has been most frequently made in aged persons, whom they often destroy. The following cases will explain the appearances on dissection.

The late Mr. Powell, surgeon, of Great Coram Street, presented me with a valuable preparation, taken from a patient of his who died fifteen months after the accident, and the following is the history of the case.

Case XC. — Mary Clements, aged eighty-three and a half years, when walking across her room, October 1st, 1820, supported by her stick, which from the debility consequent upon old age she was obliged to employ, accidentally placed her stick in a hole of the floor, by which, losing her balance, and tottering to recover herself from falling, which she would have done but for those near her, she found she had, as she supposed, dislocated her thigh-bone. When called to her, she was lying upon her bed, in much pain, with the thigh shortened, and the foot everted. Suspecting the nature of the accident, I directed extension to be made by the foot, which I found was readily brought to correspond with the opposite side; and upon rotating the limb I discovered a crepitus, which fully confirmed me in the opinion that some part of the neck of the femur was broken. With a view to the union of the bone, I first placed the limb in a straight position, making a permanent extension by fixing the pelvis, and extending from the ankle; but as the mental faculties were nearly as much shaken as the corporeal, and she could not be induced to keep up the extension required, I was obliged after a few days to change my plan for that of two boards united together at right angles, over which the thigh was placed, and was supported by pillows kept in their position by lateral pegs. In a very few days this position, in which she at first expressed herself comfortable, became so irksome, that she would no longer submit to it, and I was obliged again to abandon my wish to be decidedly useful to her. From this period she adopted any position that was most comfortable to herself, but generally, as the easiest state, lay upon the same side as the accident, with the limb drawn up at nearly right angles with the body. The neighbourhood of the joint, in the early stage of the accident, was kept wet with an evaporating lotion; the regular action of the bowels was elicited by occasional aperients, and she gene-

rally took at bed time, for an old chronic cough, an anodyne pill. For some weeks I found that I could extend the limb when I wished, but afterwards I could not accomplish this, I supposed from the permanent contraction of the muscles of the pelvis; this I presumed was more especially the case, as the opposite thigh was bent at the same angle, and was equally immovable. As she was become perfectly bed-ridden, to which state of imbecility she might be said to be rapidly approaching even before the accident, she had sloughing of the integuments of the parts upon which she lay, but did not suffer other inconvenience. Her general health appeared nearly as good as before the accident; and she ultimately sunk without any symptom of active disease, about fifteen months from the period at which the fracture took place.

Inspection. — The limb was drawn up at right angles with the body, or nearly so. I removed the os innominatum with the thigh-bone, and presented them to Sir Astley Cooper, and the following is an account of the morbid appearances:—

The neck of the thigh-bone had been broken at its junction with the body of the bone, and had been forced into the cancellated structure between the trochanter major and trochanter minor, where it had been united with the cancelli. But the most curious circumstance in this dissection was, that in order to give the support which the body required for a limb in such a state, an addition had been made both to the trochanter major and the trochanter minor, by which means they rested against the edge of the acetabulum, and in every slight change of position would give an opportunity for the weight of the body to be supported by these processes resting on the os innominatum.*

* This figure represents Mr. Powell's preparation.

My friend M. Roux sent me from Paris a fractured thigh-bone, in which the neck of the bone had been broken at the same part as in Mr. Powell's case, and had been united in a similar manner. But it frequently happens in this injury that the fracture of the neck of the thigh-bone is complicated with an injury of the trochanter major and trochanter minor.

Mr. Wray, surgeon, in Fleet Street, was so kind as to present me with the following case.

Case XCI.—A man, aged sixty-four, was standing by his bed-side, when he suddenly fell to the ground, as it was supposed, in a fit, and on the attempt to raise him, he was found unable to stand. Mr. Wray was called to him, and he found his right leg somewhat shorter than the other, and the limb everted. Motion of the limb gave him excessive pain; but no crepitus could be perceived in the examination which he would permit Mr. Wray to make. The limb was placed in a straight position, and a constitutional treatment was pursued; but a high degree of irritative fever succeeded, and on the fourth day from the accident the man died. Upon examination of the body, great extravasation of blood was found both externally to the muscles and between them; suppuration had commenced near the trochanter major, and a fracture was found at the neck of the thigh-bone and into the trochanter, by which the neck had been received into the cancellated structure of the shaft of the bone.

Mr. Travers has a most valuable specimen of this fracture, which occurred in a patient of his at St. Thomas's Hospital, and of which he had the kindness to give me the following account.

Case XCII.—Richard Norton, aged sixty, fell upon the curbstone of the foot-pavement, and struck the upper and outer part of his left thigh with great violence. He was admitted into St. Thomas's Hospital on the 24th of January 1818. The tension was then considerable; the line of the tensor vaginæ femoris formed an arch; the limb was shortened; the foot inclined outwards; the motion of the limb was free in all directions; but it was painful, more especially when the knee was carried over the opposite thigh. The crepitus of the trochanter major was distinctly felt in these motions, and the swelling of the parts, with the extensive crepitus, gave an idea that the accident was a comminuted fracture of the trochanter, and that the base of the cervix femoris was broken; hence the shortening of

the leg, and the eversion of the foot. After the use of evaporating lotions for some days, the tension subsided, so as to allow the application of the long outer splint and two thigh-splints well padded. On March the 4th, the splints were removed, and union appeared to have taken place, for the limb had resumed its natural figure, but was a little shorter than the other. In the course of a month more he began to use his crutches. On April the 15th, he was placed under the physician for defect in his general health; and when he was upon the point of quitting the hospital, he was seized with spasms in his chest, of which he suddenly expired.

Upon examination, some old adhesions of the pleura, and water in the chest and pericardium were found. The fracture was through the trochanter, as had been supposed, extending some way down the bone, and it apparently had united, with very slight deformity; but on maceration, the head and neck of the bone became loose in the thigh-bone, and a fracture was found there, which locked the head and cervix in a shell of bone formed around them.

Mr. Travers having sent me the bone, the following are the appearances of it. The head and cervix had been separated from the trochanter major and body of the bone. The upper part of the thigh bone was obliquely split, so as to receive the cervix femoris into the cancelli. This fracture of the thigh-bone separated the posterior portion of the trochanter major from the body of the thigh-bone, and the trochanter minor was removed with it. A union had taken place between the fractured portions of the trochanter, at a slight distance from each other, and thus a hollow was left, into which the cervix femoris was received, and it had not yet become united by ossific deposit, as the man had not lived sufficiently long for firm consolidation under his reduced state; for upon maceration, the neck of the bone had free play in the cavity in which it had been received, and from which it could not be removed.

Mr. Oldknow, of Nottingham, sent me two very excellent specimens of this fracture, in which the necks of the bones were broken at their junction with the trochanter major. The trochanter major itself had been also broken off, and the trochanter minor formed a distinct fracture. The bones had become reunited; the cervix femoris to the shaft of the bone, and the

trochanter minor a little higher than its natural attachment. The trochanter major was in one specimen reunited to the body of the bone, but not in the other. Thus the thigh-bone was at its upper part divided into four portions; the head and neck of the bone formed one portion; the trochanter major a second; the trochanter minor a third; and the body of the bone the fourth. The union was accompanied by very little shortening of the thigh.

Case XCIII.—I attended with Mr. Key, a fracture of the neck of the thigh-bone. The moment I had examined the patient, I pronounced the case to be a fracture external to the capsule, and was led to believe so from some little diminution in the length of the limb; from the ecchymosis which attended it; from its distinct crepitus without any rotation; from the diminished motion of the upper part of the thigh; from the sunken state of the trochanter; and from excitement of great pain by the smallest motion. This man died in a fortnight after the accident.

When the body was placed upon the table for examination, *post mortem*, all the limbs were rigid from the fixed contraction of the muscles, and, consequently, the thigh was drawn up to its greatest possible extent; yet the limb was found to be not quite three quarters of an inch shorter than the other. The posterior part of the sheath of the vessels, and some branches of blood-vessels, were torn by the bone, which accounted for the ecchymosis. The neck of the bone was forced into the cancelli of the trochanter major.

Before writing this statement, I again inquired of Mr. Key, the degree of diminution in the length of the limb, and his answer was, "If you mention three quarters of an inch, you will state rather more than its degree of retraction, even when all the muscles were contracted to their utmost rigidity."

The following case has been referred to before.

Case XCIV.—Mrs. Sarah Gibson, aged ninety, fell from a high stool, on which she was sitting on the 9th of January 1824, on the left hip, and, being a heavy woman, suffered considerable injury. I saw her two days afterwards, with Mr. Dillon of Judd Street, and found the marks of a considerable contusion having been sustained by the part, which was very painful, and swelled. The limb was rather more than half an inch shorter than the other, and the toe turned inwards in a manner sufficiently marked, although not so decidedly as in any case of dislocation. The limb was movable in every direction, although any motion was attended with considerable pain. It could be easily stretched to the same length as the other. A crepitus was not distinguished.

The patient died on the 22nd of February; and on dissection, no steps appeared to have been commenced by nature to repair the mischief. The trochanter minor was broken off with the attachment of the psoas and iliacus muscles. The head and neck of the femur were broken from the shaft by a diagonal fracture, beginning at the upper and outer part of the trochanter major, and passing inwards to where the trochanter minor was broken off, separating the bone into three parts, but leaving the insertions of the pyriformis, gemellus, obturator externus and internus and quadratus with the head and neck of the bone. The glutæus medius formed a band of union at the upper part of the trochanter major between the two parts into which it was broken. The capsular ligament was uninjured.*

Although, then, this accident has some of the marks of fracture of the neck of the bone within the ligament, yet it unites by bone, and the union is similar to that of other bones external to the joints; because in this case the parts can be brought into apposition, and the ends of the bones are confined together by the surrounding muscles; one portion is pressed against the other, and the neck of the bone sinks deeply into the cancellated structure of the trochanter; and the nutrition of each extremity of the bone is well supported by the vessels which proceed to it from the surrounding parts.

We now see the reason of the difference of opinion respecting

* This case is quoted from Mr. Guthrie's paper in the Med.-Chir. Trans. vol. xiii. and was referred to in the note at p. 131.

the union of fracture of the neck of the thigh-bone. In the internal fracture the bones are not applied to each other, and the nutrition of the head of the bone being imperfect, in general no ossific change is produced, and the accident occurs under a change in the bone from age; but in the external fracture the bones are held together by the surrounding parts; they are easily kept in apposition by external pressure, and there is not only ossific union, but very exuberant callus. Much time is required in these accidents to produce a complete ossific union; and the neck of the bone, received into the cancelli, moves for a long period in its new situation; although it is so far locked in as to prevent its separation.

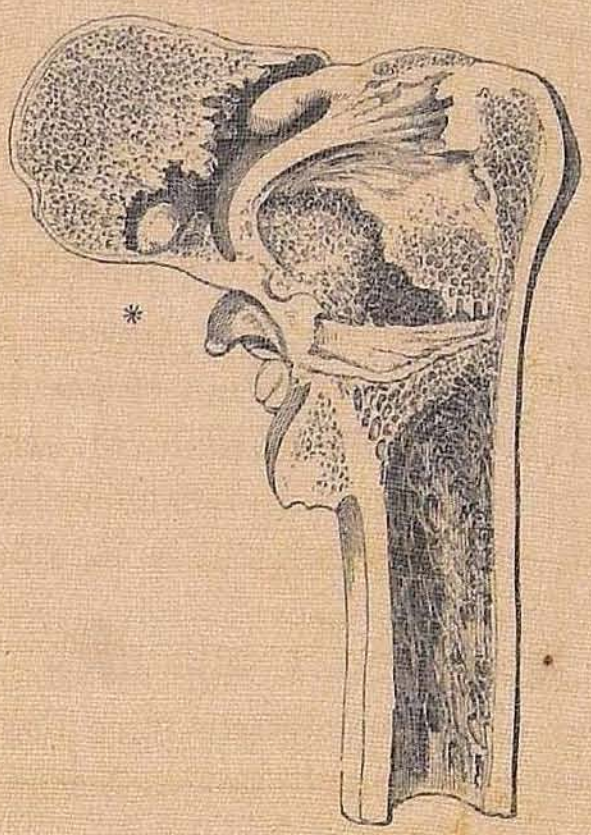

TREATMENT.—In the treatment of this injury, the principles are to keep the bones in approximation by pressing the trochanter towards the acetabulum, and to preserve the length of the limb. The foot and ankle of the injured side should be firmly bound with a roller to the foot and ankle of the other leg, and thus the uninjured side will serve as the splint to that which is fractured, giving it a continued support, and keeping it extended to the proper length. A broad leathern strap should also be buckled around the pelvis, including the trochanter major, to press the fractured portions of the bone firmly together, and the best position for the limb is, to keep it in a straight line with the body.

The following plan I have also known successful:—The patient being placed on a mattress on his back, the thigh is to be brought over a double inclined plane composed of three boards, one below, which is to reach from the tuberosity of the ischium

* This figure is taken from a preparation of Mr. Langstaff's, and exhibits one fracture internal to the capsular ligament, and another external to it; the latter firmly united by bone, the former not united.

to the patient's heel, and the two others having a joint in the middle by which the knee may be raised or depressed; a few holes should be made in the board, admitting a peg, which pre-

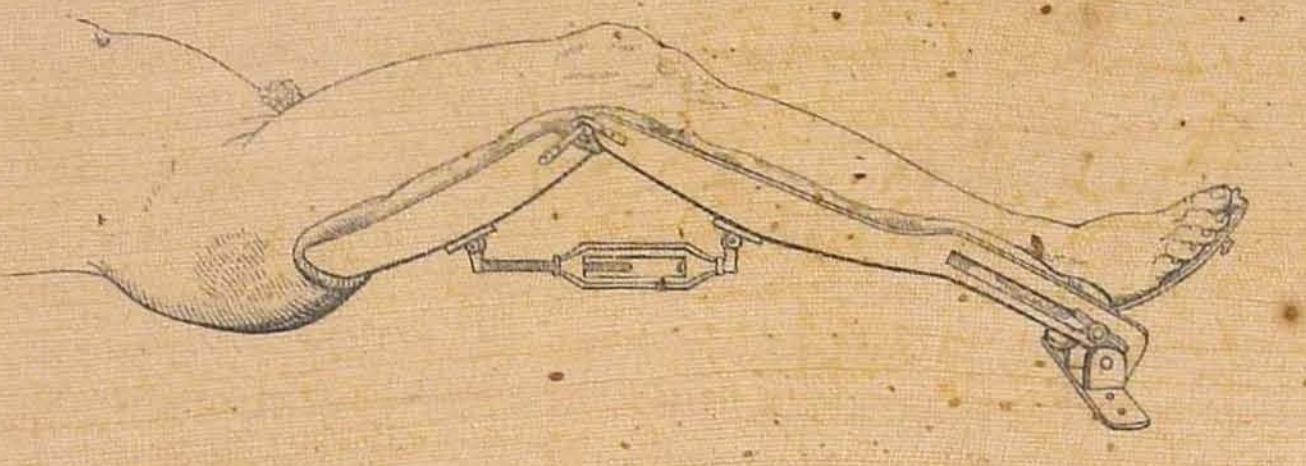

vents any change in the elevation of the limb but that which the surgeon directs; over these a pillow must be thrown, to place the patient in as easy a position as possible.*

When the limb has been thus extended, a splint is placed upon the outer side of the thigh to reach above the trochanter major, and to the upper part of this is fixed a strong leathern strap, which buckles around the pelvis, so as to press one portion of bone upon the other; and the lower part of the splint is

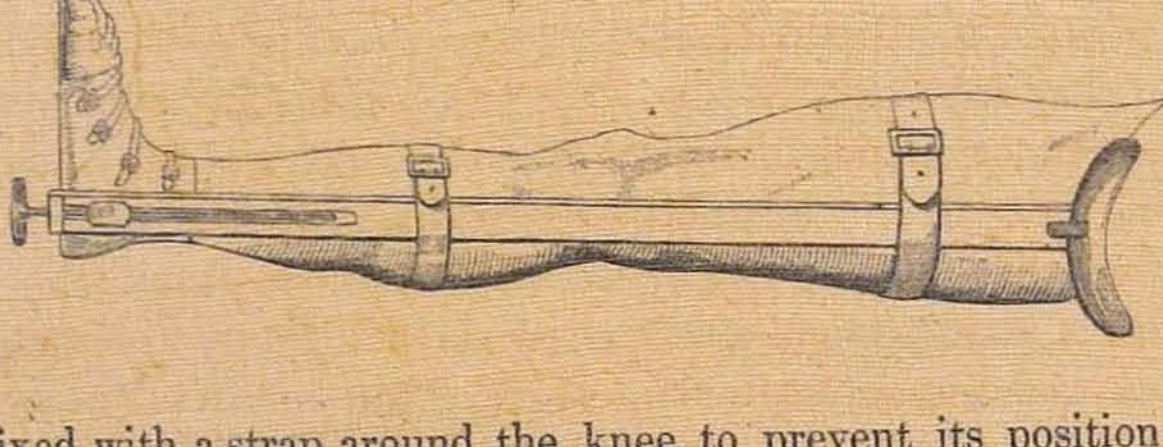

†

fixed with a strap around the knee to prevent its position from being altered. The limb must be kept as steady as possible for

* The construction of this inclined plane is so little complicated, that it may be made at the instant, of two common boards, one of which is to be sawn through nearly at the middle, and if hinges cannot be immediately procured, the boards may be nailed together thus ______ . I advise its being sufficiently broad to receive both the thighs, for if both are not brought over it the extension is never complete.

† This figure represents a long thigh-splint, with a crutch to bear against the perinæum, and a screw to preserve the length of the limb. It is very little, if at all, employed.

many weeks, and the patient may be permitted to rise from his bed, when the attempt does not give him much pain; he is still to retain the strap which I have mentioned round the pelvis; and by this treatment he will ultimately recover with a useful, though shortened limb.

SECTION IV.

FRACTURE OF THE FEMUR THROUGH THE TROCHANTER MAJOR.

Oblique fractures sometimes happen through the trochanter major, without implicating the neck of the bone. This accident may occur at every period of life, and its symptoms are as follow: — The leg is but little, and sometimes, not at all shorter than the other; the foot is benumbed; and in some cases the patient is unable to turn in bed without assistance, and the attempt gives him great pain. The limb is greatly everted; the patient cannot sit, and any attempt to do so produces excessive pain. The broken portion of the trochanter major is, in some cases, drawn forward towards the ilium; in others, it falls towards the tuberosity of the ischium; but is, in general, widely separated from that portion which remains connected with the neck of the bone. Crepitus is with difficulty discovered if the trochanter is either much fallen, or much drawn forwards.

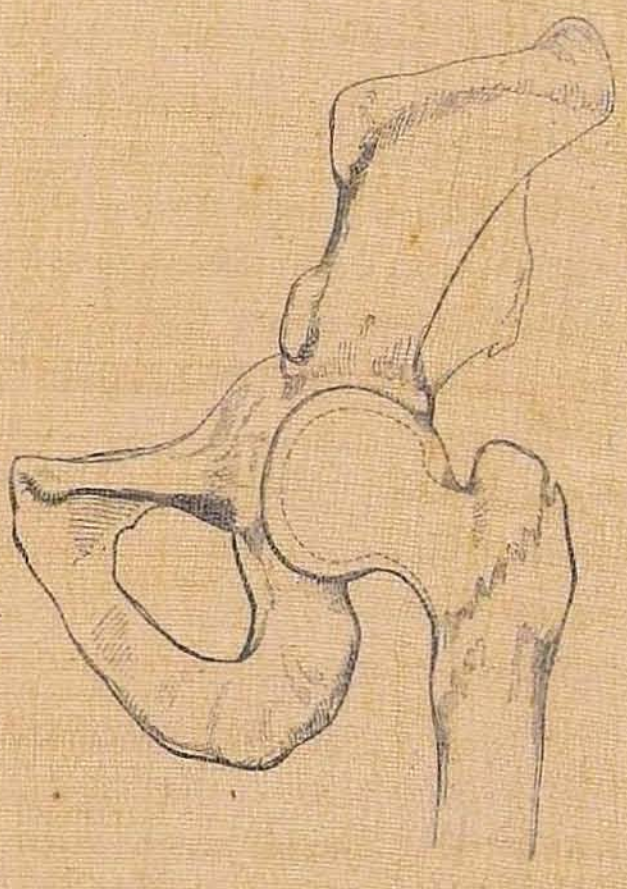

Diagnosis. — The distinguishing marks of this accident are, a fixed state of the upper part of the trochanter, whilst its lower part obeys the motion of the thigh-bone; eversion of the foot, and the very perceptible altered position of the trochanter major; crepitus felt if a rather

free movement be made of the upper part of the limb; and very little diminution of its length.

But when the fracture happens below the insertion of the principal rotatory muscles, the lower portion of bone is much raised by the action of the glutæus maximus, and the limb becomes very much shortened and deformed at the place of union by exuberant callus.

This fracture unites very firmly, and more quickly than when the cervix is broken at the root of the trochanter, and the patient recovers with a very good use of the limb.

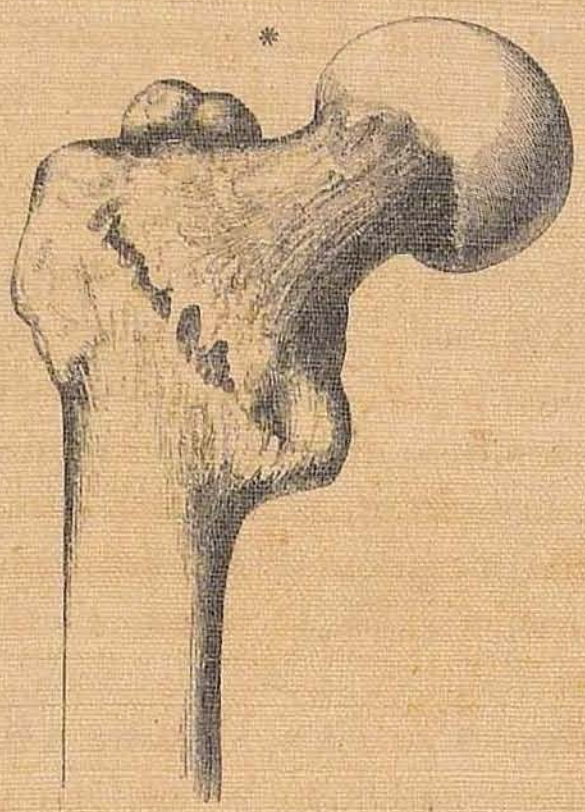

Case XCV.—The first case of this kind I ever saw was in St. Thomas's Hospital, about the year 1786. It was supposed to be a fracture of the neck of the thigh-bone within the capsule, and the limb was extended over a pillow rolled under the knee, with splints on each side of the limb, by Mr. Cline's direction. An ossific union succeeded, with scarcely any deformity, excepting that the foot was somewhat everted, and the man walked extremely well. When he was to be discharged from the hospital, a fever attacked him, of which he died; and upon dissection, the fracture was found through the trochanter major, and the bone was united with very little deformity, so that his limb would have been equally useful as before.

The following case I attended with Mr. Harris, surgeon, at Reading, who has been so kind as to communicate the circumstances in detail.

Case XCVI.—On Friday, July 20th, 1821, I was sent for to Mr. B. a gentleman living about six miles from Reading, who, I understood from the servant, had met with an accident, and put out his hip. I found him placed on a board in his bedroom, and on inquiry learnt that his horse had fallen with him

* This figure, representing this fracture united, shows the necessity of guarding against eversion of the limb in the treatment.

when putting him into a trot, and that he was thrown, and fell on his left hip on the road. He immediately got on his legs, and walked a few steps, but soon found an inability to bring his left leg forward, and complained of pain in his left hip. He was placed in a cart, and supporting his left leg by taking the stirrup and placing his foot in it, holding it steady by the leather, he was conveyed home, a distance of about four miles. I reached him within two hours of the accident, and on examining the limb I immediately perceived that there was not a dislocation.

I could not discover any crepitus on rotating the limb; it was of the same length as the other, and neither turned inwards or outwards; and he had the power of retaining it in any position in which you chose to place it. The integuments in the neighbourhood of the trochanter major were a good deal swollen; and he complained of pain, but could bear the limb to be moved in any direction, without much, or, indeed, any inconvenience, except when drawn across the other, and then great pain was felt in the situation of the trochanter minor. I then gave it as my opinion, that there was neither dislocation nor fracture, and I thought he would be well in a few days. I directed some leeches to be applied over the trochanter major, and an evaporating lotion, and took about twelve ounces of blood from the arm; and as he was in the habit of taking blue pill, I directed him to take a pill at bed-time, and some Cheltenham salts in the morning.

I should observe, that in making my examination, I discovered that Mr. B. had formerly experienced a fracture of the patella of the right knee, which had united by a ligament of near two inches in length; and on inquiry, I learnt that it had been fractured three times, in 1795, 1796, and 1800. He is of tall stature, and rather thin; and at the time of the present accident was in the fifty-first year of his age.

On seeing Mr. B. the next day, the 21st, I found that he had had no sleep, and was totally unable to move the limb without assistance. On the 22nd there was no improvement in the powers of the limb; and the part was still much swollen, although the leeches had drawn a considerable quantity of blood. Mr B. informed me, that Mr. Ring, of Reading, had called on him, and had examined the limb very minutely, and measured it and found it to correspond in length with the

other; and then told him that he was happy to confirm Mr. Harris's opinion of the case.

On the 26th, Mr. B. was attacked with an acute hepatitis, which very nearly proved fatal. From that time to the 28th, he was bled four times from the arm, to the extent of ninety-six ounces of blood, and took a saline purgative draught and calomel; during this period the limb remained in much the same state. Dr. Taylor saw him about this time. The limb was moved daily, and I began to think it did not improve so much as it ought; as it appeared at first to be only a simple contusion, and the antiphlogistic treatment pursued for the cure of the hepatitis should also, we thought, have benefited the limb.

On August the 14th, whilst Mr. Ring was moving the leg, he thought he felt a crepitus, which he communicated to me, and I remarked that it was impossible. I did not move the limb on that day, but on the following I rotated it, and distinctly felt and heard the crepitus. Mr. B. also heard it, and said, "Why you do not mean to find a fracture now!" I expressed my fears that there was a fracture, but could not say where, but thought it was through the cervix of the femur; although every symptom, saving the crepitus, was wanting to such an accident. I communicated my opinion to Mrs. B., and it was immediately arranged that Sir Benjamin (then Mr.) Brodie should be sent for, who came the following day at noon (the 18th), and met Dr. Taylor, Mr. Ring, and myself. The particulars of the case were communicated to him, and he proceeded to examine the limb, moving it in every direction; but could not then discover a crepitus, or any symptom denoting a fracture, as the limb was still of the same length with the other, and neither turned inwards or outwards. Mr. Brodie was in the first instance doubtful as to there being a fracture. We told him that we both (that is, Mr. Ring and myself,) had distinctly felt the crepitus, and that it was not discoverable but on certain motions of the limb. Mr. Brodie then examined the limb with the greatest attention, and in rotating it very extensively he felt the crepitus. Yet when the patient was standing upright out of bed, supported, and with the right leg elevated from the ground, he bore very considerably on the injured limb, so much so as to produce from Mr. Brodie an exclamation of surprise;

and he gave it as his opinion, that such was the obscurity of the case, that had he seen it a week before, he should decidedly have said that there was not a fracture, as in fact every symptom at that time was completely wanting, except the inability to move the limb; but now he believed a fracture existed in the cervix femoris, or in the superior part of the thigh-bone, where the cervix joins it.

The treatment recommended by Mr. Brodie was, a long splint placed on the outside of the limb, and a bandage from the toes to the hip, which he applied himself, and he ordered it to be worn for one month, and that the limb should be kept entirely free from motion.

At the expiration of a month Sir A. Cooper was sent for, who arrived on September the 11th. After the accident had been stated to him, he proceeded to examine the limb: he first observed the relative position of the two limbs (Mr. B. still lying on his back, with the limb resting on the heel), and then passing his hand under the trochanter major, he raised it easily, it having now dropped from its natural position; and he agreed with Mr. Brodie and ourselves in declaring the fracture to be placed in the trochanter major, where it unites with the cervix femoris.

The treatment Sir A. Cooper recommended was, to keep the trochanter in its proper position; the patient to remain in the horizontal posture; and the most perfect quiet to be observed.

The plan adopted to accomplish these objects was the following.

A mattress was made of horse-hair about five inches thick, and very smooth, and this was covered with a sheet. A part of the mattress was made to draw out on the opposite side to the fracture, so that when the necessary evacuations took place there still should be no motion of the body. Before drawing out the piece of mattress, a board of two feet long, and six inches wide, shaped like a wedge, was insinuated under the buttock of the right side, the two ends of the board resting on the mattress; thereby preventing the nates from sinking at all into the opening when the piece of mattress was removed, and the injured side still rested on the body of the mattress; the board was of course removed after the mattress was replaced. Upon the bedstead was first

N 2

placed a thick smooth board, sufficiently large to cover the bottom of the bed, and on that was placed the mattress, thereby preventing any sinking by the weight of the body.

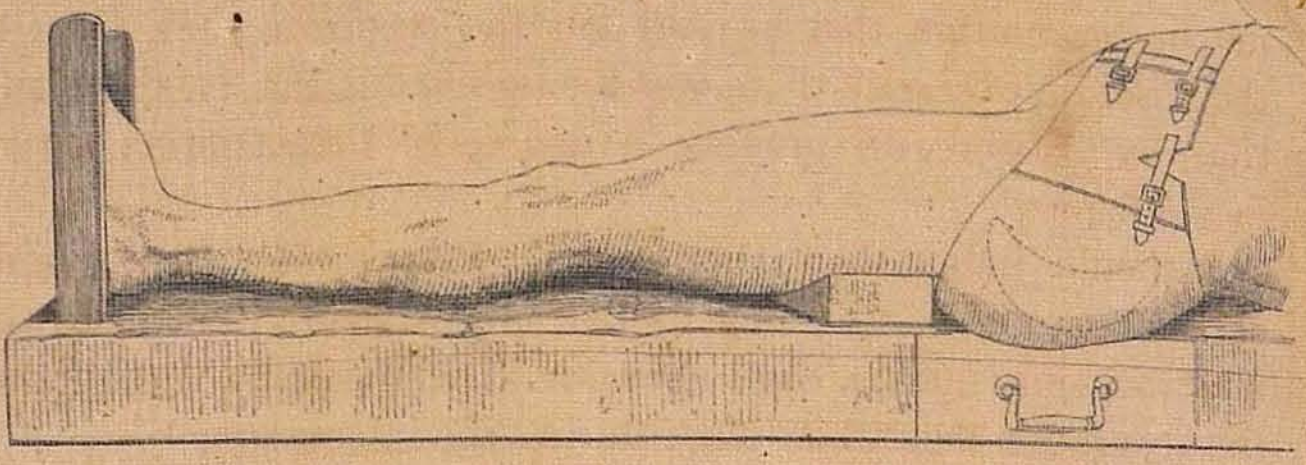

The bandage recommended by Sir A. Cooper was the following: a broad web, sufficient to go round the body over the hips, was fixed with two buckles and straps, and a piece was added to make it wider where it passed under the injured trochanter; this was lined with chamois leather, and stuffed; a pad of the same leather, which was about six inches long, three broad, and three inches thick, and ending gradually in a point, was placed immediately under the trochanter major of the injured side, so that when the bandage was buckled, the pad passed into the hollow beneath the trochanter, and when the bandage was tightened, it forced the trochanter upwards and forwards into its natural position: then another pad was made very thick, about eight inches square, in the shape of a wedge, and this was placed under the upper part of the thigh, after the bandage was fixed on. The patient was placed on his back, the limb resting on the heel; and to prevent the possibility of any motion of the foot and of the body, a wide board was fixed to the bed-posts at the foot of the bed, with two pieces of wood padded and fastened to it, into which the foot was received, and the least lateral motion prevented. A cushion was placed opposite the other foot, so that pressure could be made against the board, thereby preventing the body from slipping down in the bed.

Sir A. C. gave directions that Mr. B. should not quit the horizontal posture; and ordered him occasional purges, and a generous diet. This treatment was adopted on September the 13th, and he passed a tolerable night, and did not complain of the bandage. Nothing particular occurred during the month,

except that the patient suffered occasionally from bilious headach and vomiting, which were removed by purging. The bandage was tightened every now and then, but not to any great degree till the expiration of three weeks, when Mr. B. told me he was certain that he still felt the crepitus, when I urged the absolute necessity there was for tightening the bandage, and thus, by pressure, to produce a degree of inflammatory action in the bone.

I should judge that when Sir A. C. saw Mr. B. the ends of the bone were as much as two inches apart, but that was most certainly not the case when Mr. Brodie examined the limb; the separation had taken place during the last month.

From this time the bandage was kept as tight as it could possibly be borne (and it never shifted in the least from the position in which it was first placed), and no feeling of crepitus was afterwards complained of. The swelling of the thigh and leg was much increased, as if distended with coagulable lymph; it pitted on pressure, but it required some degree of force to produce that effect. Pain was still complained of in the direction of the trochanter minor; the bowels were torpid, and required opening medicines every other day.

Sir A. C. visited Mr. B. a second time, October 16th; the bandage was not removed, nor was the position changed. He gave it as his opinion that union had begun, and directed the patient to continue in the same position, which he did without anything material occurring except bilious attacks, till December the 30th, when Sir A. C. visited him a fourth time: he had seen him in the interval between October the 16th and December the 30th, but nothing particular had occurred.

December the 30th, Sir A. C. removed the bandages for two hours; the bone remained in its natural position; and on examination we could feel a great thickening of the parts about the trochanter. He ordered him to stand at the side of the bed after the bandage had been removed, and he stood with support a few minutes, when he became faint, and was removed to his bed. Sir A. C. wished the bandage to be replaced; and to be re-applied once a day for an hour, and the limb to be rubbed from the foot upwards. The thigh became much softer during the two hours in which the bandage was removed; the boards which supported the foot were now also removed, as well as the bandages, and

Mr. B. was placed on crutches. From this time he rose every day; and the limb continuing very much swollen, it was rubbed daily from two to four hours; still he could not bend the knee; but when standing on his crutches he had a most perfect use of the hip-joint. We endeavoured to regain the motion of the knee by friction with oily embrocations. On Friday, March 1st, Mr. B. left E—— in his carriage for London.

After his arrival in London, Mr. B., with great steadiness, employed friction and passive motion for the recovery of the use of the knee, with the happiest effect, and the hip-joint became entirely restored to its natural powers.

CASE XCVII. — I was consulted on the 18th of June 1830, respecting the case of a young lady who was attended by Mr. Godwin, of Midhurst, and Mr. Blagden, of Petworth. The patient was thrown from her pony in consequence of the saddle turning round, and she fell on her left hip. The symptoms were as follow: — the limb everted, and shorter than the other, but capable of being extended to the same length; considerable difficulty of rotation inwards; this motion attended with very great pain; no crepitus felt, unless in pushing the limb upwards; the trochanter not higher than the other.

On making the patient stand, supported by assistants, the limb was seen to be everted; all the foot except the heel touched the ground, but the heel, likewise, could easily be made to do so; the limb was capable of being moved freely, without crepitus, but rotation inwards was very difficult.

I gave it as my opinion that the case was one of fractured trochanter, and recommended the following treatment: the limb to be placed on a double inclined plane, with a side splint buckled firmly round the pelvis, and a wedge-shaped cushion under the trochanter, in order to support and compress it. In this position she was kept for eight weeks, when she was permitted to rise from her couch and use crutches. Friction and passive motion restored the use of the limb, but the foot remained a very little everted.

CASE XCVIII. — Mr. Peggler, of Wanstead, aged forty-six, on the 13th of November 1817, fell, while walking, on a glass bottle which he had in his pocket; and when he attempted to raise himself from the ground he found he was not able to stand. In a quarter of an hour he felt great pain, and could not bear the slightest weight of his body on the injured limb. Mr. Con-

stable, of Woodford, was sent for, and he gave me the following account of the case. The foot, at first, did not appear to turn out; but when the patient was put into bed, and laid on his back, it became everted: the leg appeared somewhat shorter, but was with little difficulty pulled down to its natural length; the foot was benumbed, and continued so for twelve months. He was placed in bed, with a bolster under the hip to prevent displacement of the bone; and his knees and ankles were tied together.

In December following, about Christmas, I met Mr. Constable, whilst visiting a patient with a severe injury of the head, and he then requested me to see Mr. Peggler, whom I found incapable of turning in his bed without assistance, and the attempt gave him great pain; his injured leg was a little shorter than the other, and the trochanter was drawn forward towards the spine of the ilium, and could be felt considerably separated from that portion of the trochanter connected with the neck of the bone; the foot was turned outwards; he could not sit, and the least attempt to raise himself produced excruciating suffering. I brought him to the foot of the bed in an horizontal position, to make as accurate an examination as I could of the nature of the accident, and had no hesitation in pronouncing it a fracture through the trochanter. In less than a month he began to use his crutches, and continued their use for three months; he then laid aside one crutch, and employed a stick and crutch, and in a short time needed the support of a stick only; but it was twelve months before he recovered the entire use of his limb. The leg is still nearly an inch shorter than the other: the portion of the trochanter connected with the thigh-bone has united with the fore-part of the trochanter joined to the neck of the bone, and is, consequently, much nearer the spine of the ilium than usual; the foot is also slightly everted, but he walks extremely well; a week ago he walked ten miles from home, and returned the same day; and this day, July 28th, 1819, he has walked from Wanstead to my house, and intends to walk back, a distance of nearly twenty miles.

This history of Mr. Peggler's accident is so similar to the cases of fracture through the trochanter major which I have had an opportunity of seeing, that a detail of the latter would only become a useless repetition; the only variations that I have

witnessed having been in the distinctness of the crepitus accompanying them, which is less in proportion as the fracture approaches the capsular ligament. I have lately fractured through the trochanter major five different thigh-bones in the living animal; they united, but with great distortion, shortening, and exuberant callus.

The following case of Mr. Stanley's is interesting.

CASE XCIX. — "A woman in her sixtieth year fell in the street, and injured her right hip. On examination, the limb was found slightly everted, and shortened to the extent of three-quarters of an inch, but movable in every direction. The extremity of the shaft of the femur was in its natural situation; but behind the femur, and at a little distance from it, a *bony prominence was discovered resting upon the ilium, towards the great sciatic notch, strongly resembling the head of the femur.* Various opinions were entertained as to the nature of the injury, some believing it to be dislocation, and others, fracture. After a confinement of several months to her bed, the woman was sufficiently recovered to walk with the assistance of a crutch, and in this state she continued till her death, which took place about three years after the accident, during the whole of which period I had watched the progress of the case. Having obtained permission to examine the seat of the injury, I ascertained that there had been a fracture extending obliquely through the trochanter major, and through the basis of the neck into the shaft of the femur, and that the prominence which had been mistaken for the head of the bone was occasioned by the posterior and larger portion of the trochanter drawn backwards towards the ischiatic notch." *

GENERAL DIAGNOSIS. — To conclude: As diminution of the length of the limb, and eversion of the knee and foot, are signs which are common to fractures of the thigh-bone generally, it may be proper, before quitting the subject, to bring into one view the means of distinguishing the three species of fracture which I have described.

The fracture of the cervix within the capsule is known, with very rare exceptions, by the very advanced age of the patient, — by its greater frequency in female than in male subjects, — by the absence of swelling and ecchymosis, — by the elevation and advance of the trochanter, — by the greater mobility of the joint, allowing flexion and extension, although with some pain and

* From the Med.-Chir. Trans. vol. xiii.

resistance from muscles, — by a crepitus perceptible only on drawing down the limb to the same length with the other, and then rotating it, — by the pain felt at the trochanter minor, — by little constitutional irritation attending the accident, — by the slight causes which produce it, — and by the little local swelling or change of appearance which ensues.

Fractures of the cervix into the cancelli of the trochanter are known by the effusion of blood amidst the muscles,—by great swelling produced, and by ecchymosis, which appears soon after the accident, — by an unnaturally fixed state of the joint, so that flexion and extension cannot be performed, — by excessive pain being produced on the least motion of the hip-joint, and upper part of the thigh-bone,—by a crepitus being perceived under the least motion of the thigh-bone, without drawing it down to the length of the other,—and by the inflammation, swelling, and constitutional irritation produced, which are frequently destructive.

The fracture of the trochanter major may be easily known by the separation of the bone at the part, so that the finger may be placed between the fractured portions, — by the distinct crepitus felt in putting the fingers on the trochanter when the knee is advanced, — by the upper portion of the trochanter not obeying the motions of the lower, and of the shaft of the bone, — and when at the lower part of the trochanter, by great overlapping, distortion, and exuberant callus.

I have thus stated what dissection and observation have taught me of the three fractures of the upper part of the thigh-bone, and shown it to be a general principle, that fractures within the capsule do not unite by bone.

SECTION V.

FRACTURE OF THE EPIPHYSIS OF THE TROCHANTER MAJOR.

Mr. C. Aston Key, Surgeon to Guy's Hospital, had the kindness to send me the following account of a peculiar fracture of the trochanter major, in which this process was broken from the thigh-bone at the part at which it is naturally united by cartilage as an epiphysis in youth.

Case C.—The subject of the accident was a young girl about the age of sixteen, who, in crossing the street with a can in her hand, tripped, and in falling, struck her trochanter violently against the curb-stone. She immediately rose, and without much pain or difficulty walked home. The accident occurred on Saturday, March 15th, 1822; and, in consequence of the increase of pain she experienced on the inner side of the thigh, she presented herself at Guy's Hospital for admission on the Thursday following. Her constitutional symptoms being evidently more violent than those which usually arise from fractured femur, she was placed under the care of the physician, Dr. Bright, at whose request I examined the limb. Her right leg, which was the one injured, was considerably everted, and appeared to be about half an inch longer than the sound limb. It admitted of passive motion in all directions, but in abduction gave her considerable pain. She had perfect command over all the muscles except the rotators inwards. The fact that she had walked both before and since her admission into the hospital, gave rise to some doubts as to the existence of a fracture, and the closest examination of the trochanter and body of the femur could not detect the slightest crepitus or displacement of bone. I repeated the examination of the limb on the following day, but the result was equally unsatisfactory.

As the fever under which she was labouring, together with general abdominal uneasiness, threatened her life, the limb underwent no further examination. She died on Monday, nine days after the accident.

Dissection. — Wishing to ascertain (for I suspected some obscure fracture of the os femoris) the exact nature of the injury, previously to removing the soft parts I moved the limb in every direction, fixing the trochanter and head of the bone; but I could perceive no deviation from the usual state of parts, nor could I distinguish the slightest crepitus under all the variety of movements. I should observe, that there was no tumefaction of the thigh, and therefore the trochanter and head of the os femoris were as readily distinguished and exposed to examination as in the most healthy limb.

The capsule of the joint being laid bare, a cavity was discovered by the side of the pectineus, leading backwards and downwards, towards the trochanter minor, and containing some

pus: it allowed the fingers to pass behind the bone to the greater trochanter. The head of the bone was then dislocated by cutting through the ligaments, and not till then was a fracture discovered at the root of the trochanter major. The upper half of the femur being removed from the body, I discovered the reason why the fracture had eluded our search.

The fracture had detached the trochanter from the body and neck of the bone, but without tearing through the tendons attached to the outer side of the process. The tendons are those of the two smaller glutæi, and the commencement of that of the vastus externus; had they been torn, the broken portion of bone would have been drawn upwards by the action of the two former muscles, and, in that case, the injury would readily have been recognized; but they so effectually prevented all motion of the fractured portion that, when dissected from the body, not the least motion could be produced except in one direction. It was found that this motion resembled that which would be produced by a hinge; the tendons acting the part of a broad hinge, and allowing the portion to be moved only upwards and downwards. It is evident that such motion could not have been produced by any direction given to the limb; hence it is also manifest that the fracture could not have been detected during the life of the patient.

Case CI. — Mr. Gaitskill, sen., consulted Mr. Bransby Cooper about a patient of his who had been thrown out of his gig, close to his own door, falling on the trochanter major. The patient was unable to rise, or when raised, to walk, although he could bear his own weight on the limb of the injured side; he was therefore carried to his own house, and Mr. Gaitskill was sent for, who upon examination found great tumefaction and ecchymosis, attended with considerable pain of the injured hip, but could not discover any fracture. He desired, therefore, the patient to go to bed, believing that a very few days would restore the limb to its natural state. The patient, however, notwithstanding the strict observance of the plans laid down for him by Mr. Gaitskill, at the end of four days still found himself incapable of moving his limb, and said he felt conscious that his limb was fractured: and Mr. Cooper was then consulted.

Mr. Cooper was led by the history given him to make a most minute examination. He began by placing the pelvis exactly

square, so that he might compare the lengths of the lower extremities, which he found to correspond exactly. There was neither inversion nor eversion of the foot; all the motions of the hip-joint could be produced, the *point d'appui* of the thigh-bone being evidently maintained within the acetabulum, but yet these motions gave great pain; in fact, the only deformity which Mr. Cooper could perceive arose from the tumefaction about the hip, and he agreed therefore with Mr. Gaitskill that no fracture had occurred.

Four days afterwards they again met in consultation, when the patient was found in exactly the same situation as before; that is to say, incapable of any voluntary motion with the injured limb, and still possessed with the conviction that there was a fracture.

Mr. Cooper, therefore, again made a most minute examination. He desired the patient to get out of bed, and to stand straight, and with equal pressure on both limbs: this he could do with but little pain or inconvenience. In this position the posterior region of the hip on the injured side formed a greater projection than on the opposite; not like the general swelling of a bruise, but like the knotted contraction of muscle. The trochanter major was not perceptible in its natural position, and pressure in this situation was extremely painful to the patient. Mr. Cooper now began to suspect the nature of the injury, and searched diligently to discover the position of the detached portion of the trochanter; which, however, partly from the swelling, and partly from the small size of the separated portion, he was not able to do. He then placed the patient in bed on his back, and desired him to bend the pelvis over the injured side; at the same time he abducted the limb to its fullest extent, and pressing down the glutæi muscles, depressed the detached portion of bone so as to feel crepitus of the trochanter. In this position, having produced co-aptation of the fractured portions, he endeavoured to employ mechanical means to keep them in apposition, by applying bandages and compresses upon the upper portion of the trochanter, so as to draw it downwards and fix it in its place. The patient remained for more than six weeks in this position, and was then permitted to leave his bed; after which Mr. Cooper saw him no more for two years, when he was still the subject of some degree of lameness, but was capable of performing most

of the functions of the injured hip, even to slight feats of agility, although with a halt.

The difficulties of the diagnosis of this case are sufficiently clear from the circumstances which have been mentioned; namely, the smallness of the detached portion; the slight degree of deformity, which, moreover, depended more upon the soft parts than upon the displacement of the bone; together with the mobility of the limb in all its natural directions, and in no other. In the treatment of such cases, there must always be much difficulty in producing and maintaining co-aptation of the parts; and, lastly, the prognosis of perfect recovery must be unfavourable; for the fractured portion of the trochanter being covered by the tendons of the glutæi muscles, and by the synovial lining of a bursa, and invested with tendon and not with periosteum, and being separated from its right position by the muscles, is placed under circumstances similar to the patella, olecranon, and os calcis, and, like those bones when entirely severed by fracture, cannot be capable of reparation by ossific union.*

The following case, in which this accident presented some of the symptoms of dislocation, is related by Mr. Stanley, in the same paper in which he gives the history of another case (XCIX). That also had some resemblance to a dislocation.

Case CII.—A man, æt. sixty-five, was knocked down in the street. His skull was severely injured, and he likewise sustained an injury in the right hip. His death took place on the tenth day from the time of the accident. The particulars of the injury sustained by the hip were as follow:—The limb was shortened and everted. Behind, and at a considerable distance from the extremity of the shaft of the femur, *a distinct prominence was discovered, so nearly resembling the head of the bone*, that it was presumed a dislocation had occurred. On this presumption, a forcible extension of the limb was made, which shifted the prominence that had been mistaken for the head of the bone. On examination of the hip after death, a fracture was found extending through the trochanter major, and through the basis of the neck of the femur. One portion of the trochanter had been drawn backwards into the situation which the head of the bone would occupy in dislocation; but it still re-

* Surgical Essays, p. 73.

tained sufficient connexion by periosteum with the shaft of the femur, to explain the change in its situation during the extension of the limb.

SECTION VI.

FRACTURES BELOW THE TROCHANTER MINOR.

The thigh-bone is sometimes broken just below the trochanter major and minor; it is a difficult accident to manage, and miserable distortion is the consequence if it be ill-treated. The end of the broken bone is drawn forwards and upwards, so as to form nearly a right angle with the body, and the cause of this position is evidently the contraction of the iliacus internus and psoas muscles, assisted by the pectinalis, and perhaps by the first head of the triceps. A better idea of the effect of this accident may be obtained by a view of the plate, in which the bone will be observed to be united, not only with extreme shortening, but with a hideous projection forwards. If pressure be made upon the projecting bone in the treatment of this case, it only adds to the patient's suffering, and to the degree of irritation of the limb, without preserving the bone in its proper situation. It will be seen that this union exceedingly overlaps, and that it is very feeble; showing what I have already mentioned, that a fracture thus circumstanced has the ossific deposition only on that side where the inflammation was preserved by the pressure of one bone on the other. This preparation may be seen in the Anatomical Museum, St. Thomas's Hospital.

To prevent this horrid distortion and imperfect union, two circumstances are to be strictly observed: the one is, to elevate the knee very much over the double inclined plane; and the other, to place the patient in a sitting position, supporting him by pillows during the process of union. The degree of elevation of the body which is required will be about forty-five degrees, but it may be readily ascertained by observing the approximation of the fractured extremities of the bones; and this position is demanded to relax the psoas and iliacus muscles, and thus prevent the elevation of the upper part of the bone. In this manner, and thus only, can the great deformity I have described be prevented. When, by this posture, the extremities of the bones are brought into proper apposition, and all projection of its upper portion is removed, either the splints may be applied which are commonly used in fracture of the thigh-bone, or, what is better, a strong leathern belt, lined with some soft material, should, by means of several straps, be buckled around the limb, and be confined by means of a strap around the pelvis.

The following communication, which I received in 1833 from Mr. G. Bond of Glastonbury, explains the manner of employing plaster of Paris, which appears to form a very simple and efficient contrivance for keeping oblique fractures in their proper position.

Case CIII.—"A young man suffered an oblique fracture of the thigh, and all my attempts to keep it in a proper position were of no avail, till I resorted to the following contrivance. A round towel was passed between the legs, confining the pelvis to the head of the bed: the pulleys were placed in a right line; the leg was laid in a long box with a hole at the bottom for the rope; and extension made, until the divided portions were brought in contact, and the limb of its original length. Then strips of soap plaster spread upon calico were placed from the toes up the leg and round the trochanter. The inside of the box and the leg were then covered with linseed oil, and liquid plaster of Paris a little warm was poured into the box, and by degrees the whole limb enveloped in it except the foot. Before it got quite set I removed it by means of a spatula for the space of two inches, exposing the strapping, from the spinous process of the ilium to the instep, and when it became hard I released

the pulleys. From that time there was no retraction, and the young man declared that if it were not that the leg was immovable, it felt in every respect as the other. The resistance from the trochanter to the external condyle of the femur and outer ankle, and again from the ischium to the internal condyle and ankle, was perfect; and yet the man was not at all sensible of it, nor of any kind of pressure."

This manner of using the plaster of Paris has been found useful by other surgeons in similar cases.

CHAPTER V.

ON DISLOCATIONS OF THE KNEE.

SECTION I.—ANATOMY OF THE JOINT.

The broad surfaces of bone by which the os femoris rests upon the tibia are calculated to prevent the ready dislocation of this joint, which would be otherwise very liable to happen from the superficial nature of the articulating cavities on the head of the tibia, and also from the great violence to which the joint is frequently exposed.

The depressions upon the head of the tibia are increased by the addition of the semi-lunar cartilages which rest upon that bone; these receive the condyles of the os femoris, and are attached by ligaments (called *coronary*) to the edge of the tibia, and by a transverse ligament to each other. The fore part of the joint is defended by the patella, which has two unequal articular surfaces to play upon the condyles of the os femoris. The head of the fibula forms no part of the knee-joint, but is attached to the tibia from one half to three-fourths of an inch below its head.

Ligaments.—In pursuance of my usual plan, I will briefly recapitulate the leading points connected with the anatomy of the ligaments of the knee-joint, because without a distinct recollection of the anatomy, it is neither easy nor satisfactory to study the injuries of a joint. The first ligament that I shall mention is the

Ligamentum Patellæ, a broad compact ligament which extends from the apex of the patella to the tubercle of the tibia. But this, properly speaking, is not a ligament of the knee, but rather the tendon by which the united extensors of the thigh are inserted into the tibia.

In the second place, the knee, like all other hinge joints, has strong *lateral ligaments;* of which the *internal* or *femoro-tibial*

connects the inner condyle of the femur to the tuberosity of the tibia; while the *external lateral ligament* connects the external condyle to the head of the fibula. The latter is divided into two bands, one of which is attached in front of the head of the fibula, and the other behind it.

Thirdly, there is the *posterior*, or ligament of Winslow, which passes obliquely across the back of the joint from the head of the tibia to the external condyle, and which seems to be given off from the tendon of the semi-membranosus muscle.

Fourthly, concealed within the joint, are two strong ligaments which pass cross-wise from the notch between the condyles of the femur to the head of the tibia, and which are therefore called crucial. The *anterior crucial ligament* passes downwards and forwards from the inner surface of the external condyle to a depression on the fore-part of the head of the tibia, in front of its spinous process; the *posterior crucial ligament* passes downwards and outwards from the outer surface of the internal condyle, to the head of the tibia, behind the spinous process.

Besides these ligaments, there is a tendinous expansion given off from the vasti muscles and attached to each side of the patella. This protects the synovial membrane, at the parts where it is most superficial, and used to be called the *capsular ligament.*

It would answer no practical purpose to speak of the reflections of the synovial membrane, or of the processes which it forms within the joint; but I must observe that it passes up for some little distance above the patella, between the femur and the extensor muscles; and that consequently, when the joint is distended with fluid, there will be considerable fulness at the lower part of the thigh, as well as on each side of the patella.

We thus see that the ligamentous junction of the three bones is very firm; allowing of free flexion and extension, with some little rotatory motion when the joint is bent, but resisting all lateral motion, or extension beyond the straight line. Nevertheless, although great strength is evident in the construction of this joint, still excessive violence and extreme relaxation will occasionally produce its dislocation.

SECTION II.

DISLOCATIONS OF THE PATELLA.

Dislocation Outwards.—The patella is liable to be dislocated in three directions, namely, outwards, inwards, and upwards. Of these the dislocation outwards is the most common, the bone being thrown on the external condyle of the os femoris, where it produces a great projection; and this circumstance, with an incapacity of bending the knee, is the strong evidence of the nature of the injury.

The most frequent cause of the accident is, that a person in walking or running falls with his knee turned inwards, and the foot outwards; and thus, by the action of the muscles to prevent the fall, the patella is drawn over the external condyle of the os femoris; and when the person attempts to rise he finds himself unable to bend his leg, and the muscles and ligaments of the patella are all forcibly on the stretch. It may also be caused by direct violence. This accident generally occurs to those who have some inclination of the knee inwards, which, under the action of the extensor muscles, gives a direction to the patella outwards.

Dislocation Inwards.—This dislocation is much less frequent, and it happens from falls upon a projecting body, by which the patella is struck upon its outer side, or by the foot being, at the time of the fall, turned inwards. In either of these cases the ligamentous fibres attached to the side of the patella will be torn, unless relaxed by some previous disease.

A partial dislocation of the patella outwards is far from uncommon. It is attended with the most acute sickening pain and faintness.

Case CIV.—Mr. Harris, getting into a chaise, caught his foot in the carpet at the bottom of it, by which accident the knee was turned in and the leg outwards; the patella slipped upon the external condyle of the os femoris, but it returned very soon by the effort of the muscles, into its natural situation. On examination, I found the internal portion of the capsular ligament, torn, and a great accumulation of synovia in the joint.

Case CV. — Miss Mortimer has frequently dislocated her right patella inwards, by touching her toe against a carpet, by turning in bed, and in dancing. Her mode of putting it into its place is by straightening the limb, and by pressing it towards the joint with her thumb. The pain is excessive, and she cannot move when it is out.

Case CVI.—Mr. Beale dislocated both his patellæ outwards, in letting himself down a steep bank. They went in of themselves when the legs were straightened.

Treatment.—The mode of reduction in either case consists in pursuing the following plan:—The patient is placed in the recumbent posture, and an assistant raises the leg by lifting it at the heel; the advantage of which is, that it relaxes the extensor muscles on the thigh in the greatest possible degree; the surgeon then presses down that edge of the patella which is most remote from the joint, be it one luxation or the other; and this pressure raises the inner edge of the bone over the condyle of the os femoris, and it is immediately drawn, by the action of the muscles, into its natural situation.

When the reduction has been effected, an evaporating lotion of spirits of wine and water is to be applied; in two or three days the limb may be bandaged, and it is soon restored to its natural uses, although it is somewhat weaker than before.

Difficult Cases.—It sometimes happens that considerable difficulty is experienced in replacing the bone.

Case CVII. — Mr. George Young informed me that he was called to a case of dislocation of the patella outwards, in which the reduction was very difficult. The patient was a female, who, by a fall in walking, had the patella drawn over the external condyle of the os femoris, where it remained. He employed pressure upon the edge of the patella most perseveringly without being able to succeed, but at last reduced it in the following manner:—He placed the patient's ankle upon his shoulder, and thus most completely extended the limb, and obtained a fixed point of resistance at the knee; then grasping the patella with the fingers of his right hand, he pressed the outer edge of the patella with the ball of his left thumb, and pushed it into its place.

But the most difficult cases are those in which the bone is dislocated so as to be turned half round, and rest on its edge; and the following cases will show that it sometimes is turned

half round in its place, so as to rest with one edge in the middle of the articular surface, between the condyles of the femur; and that sometimes this state of semi-rotation is combined with dislocation upon the outer condyle.

Case CVIII.—Mr. Welling, formerly surgeon at Hastings, was called to a case in which the patella was dislocated upon its edge. The nature of the accident was very obvious, as the edge of the bone forced up the integuments to a considerable height between the condyles on the fore part of the joint. Mr. Welling reduced the dislocation, but with considerable difficulty, by pressing the edges of the bone in opposite directions when the leg was extended.

Case CIX.—"I was called," says Mr. Mayo, "into consultation by my friend Mr. Broughton, upon a case of dislocation of the patella, which had occurred under the following circumstances. A private of the 2nd Life-Guards, a stout muscular young man, was struck sharply on the right knee by the knee of another soldier, as in the exercises two opposite lines rode through each other. They were riding at a walk, but the soldier on the right of our patient had spurred his horse, so that it moved forwards briskly. By this accident the patella was dislocated outwards, and rested with its inner edge upon the outer surface of the external condyle, the fore-part of the patella facing forwards and inwards. As the patient lay with the knee extended he experienced no pain; there was no tension of the quadriceps extensor cruris; the patella admitted of a slight degree of motion forward or backward, turning upon its inner edge, which seemed caught behind the prominent margin of the articular surface of the condyle.

"We tried the following methods to reduce the dislocation:—1. The knee remaining extended, we pressed the outer edge of the patella downwards, forcing the bone at the same time strongly inwards. 2. Force was applied in the same manner, the joint being rather more than half-bent. 3. We used the same sort of pressure, beginning it while the knee was bent, and continuing it as forcibly as possible at the moment that the joint was brought to the extended position. Bending the knee to the extent described we found gave the patient great pain, and caused the patella to face, not obliquely, but directly forwards.

These attempts proved unavailing, and we left the patient for

a time. In the afternoon we met at the Anatomical Theatre in Great Windmill Street, and examined the nature of the dislocation in a dissected limb, when we found that upon bending the knee to the utmost, the condyle was almost wholly drawn away from the patella; and we thought it reasonable to expect that if the joint in our patient should be found to admit of perfect flexion, the patella would in that case, as we had seen it in the dissected limb, become disengaged from the condyle, and the dislocation be spontaneously reduced by the action of the quadriceps extensor cruris.

"We returned to the Barrack Hospital, and our patient expressed his willingness to submit to the experiment which we purposed to try. He was laid upon the left side, and his right ankle was grasped by a comrade, who, when we bade him, suddenly carried the heel back to the hip, thus bending the knee to the utmost. The motion was hardly completed when the patella audibly returned into its socket."*

The following case, which is quoted in the third volume of the London Medical Gazette, p. 320, from Rust's Magazine, had a much less favourable termination than the foregoing case of Mr. Mayo and Mr. Broughton.

Case CX.—Daniel Steinbach, a powerful young man, private in the Hussars of the Guard, whilst riding without stirrups, at a walk, on the 23rd December 1823, was jolted by a sudden start of his horse against his left-hand mounted comrade. Very severe pain was immediately felt in the left knee, rendering him unable to remain on horseback, from which he was carefully lifted, and carried to the hospital. An examination was immediately made, and the left patella found to be dislocated in the following manner. The bone had undergone a *semi-revolution on its longitudinal axis;* its inner edge rested fixed in the trochlea, between the condyles of the femur; the outer projected directly forwards; the anterior surface was directed inwards, and the posterior outwards. No swelling having yet taken place, the nature of the injury was readily made out; and, independent of the posterior surface of the patella being sufficiently indicated by the raised vertical line upon it, the nature of the dislocation was pointed out by the direction inwards of the very tense tendo communis extensorum cruris, and the ligament of the patella. The skin

* Lond. Med. Gaz. vol. ii. p. 754.

over the distorted projecting bone was greatly stretched, but not so much so as to prevent its being movable over it, and capable of being raised into a fold. The leg was completely extended on the thigh, and flexion of the knee-joint almost impossible, and extremely painful to the patient; the attempts of others to effect this were equally so. In the extended state of the limb, the patient felt almost no pain.

The distorted patella appearing to be retained in its unnatural position by the tension of the tendo extensorum cruris, the indication was, to diminish this to the utmost, to raise the bone from its situation, and then rotate it from within outwards. With this view the extended leg was raised upon pillows; a bandage was passed round the middle of the thigh, and by means of two fillets, attached one on each side of this, the soft parts were drawn downwards. The patella was then laid hold of, so that the thumbs of the surgeon were placed on its posterior surface, now directed outwards; the fingers on the anterior surface, now directed inwards; and being firmly grasped, an endeavour was made to draw the bone forwards, and turn it; but, however frequently and carefully this was attempted and repeated, it was unavailing; the bone did not yield in the slightest degree, but remained fixed in its place. Attempts made whilst the limb was in a state of moderate flexion (more than this was impossible) were equally unsuccessful; and as the patient experienced violent pain during them, could not be often repeated. In order not to aggravate by too long-continued manipulations the consecutive inflammation, these attempts were now abandoned, and other means of relief were inquired into.

It became a question whether the parts should, for the present, be left as they were, and after the adoption of certain preparatory treatment, the attempts at reposition should be repeated; or whether we should free the bone, by dividing the tendo communis extensorum cruris and the ligamentum patellæ, so as to draw it forwards, and replace it in its natural situation. As objections to the first plan of treatment, it appeared that after the accession of inflammation every attempt at reposition would be attended with greater pain and danger; that the unnatural position of the patella would be a continued cause of inflammation; and that its pressure upon the articular cartilage of the femur would cause its ulceration; and under the most favourable circumstances, (as

dissection subsequently showed,) produce anchylosis of this with the patella, and consequent immobility of the joint. The operation, on the other hand, was simple, attended with little pain, and, carefully performed, with not more dangerous consequences than those which attend that which is executed with so much success for the removal of loose cartilages from the joint.

The operation being determined on, an incision was made in the skin over the bone, extending from an inch above the patella to the spine of the tibia. The subjacent cellular substance, and some aponeurotic fibres being divided, the common tendon was exposed and carefully divided by repeated strokes of the knife at the place of its insertion into the bone. The capsular ligaments of the joint seemed uninjured; the reposition of the patella was now attempted, but without success. The ligament of the patella was now divided at its attachment to the tibia; but it was with much concern found that the patella still remained as immovable as before. The patient, who had not complained of the cutting parts of the operation, cried out loudly, upon these attempts at reposition; and after satisfying myself of their inutility, they were abandoned. There had been little bleeding; the wound was united by sutures; the leg was kept extended and elevated; and the extensor muscles of the thigh were kept in contact with the divided tendon by an expansive bandage; eighteen ounces of blood were immediately taken from the arm, and forty leeches applied to the joint; and after the bleeding from these had ceased, pounded ice was kept applied to the parts. A mixture, containing Glauber salts and nitre, was given internally. We need not give the daily reports of the case; it will be sufficient to state, that although the wound made in the operation healed by the first intention, with the exception of a point at the upper part of it, inflammation and suppuration of the joint took place; and an abscess formed in the under part of the thigh, which was opened. From these two apertures matter continued to be discharged. In the month of March, symptoms of chronic inflammation of the mucous membrane of the bowels appeared; and in that of September, those of general œdema and ascites; and of this last the patient died on the 18th of November, 1824, nearly eleven months after the accident.

On dissection, but a small quantity of thin pus was found in the cavity of the joint, the capsular ligament of which was thick-

ened, and firmly united to the surrounding cellular substance. The cartilaginous covering of the articular extremity of the femur was entirely absorbed from the trochlea, between the condyles; and from the anterior parts of these also; a portion still remaining on them posteriorly. The cartilage on the head of the tibia was partially absorbed. The patella, whose cartilaginous covering was almost entirely gone, appeared considerably less than that of the sound limb. Its edge was anchylosed, in the direction and situation already described, to the extremity of the femur; and a less extensive union was observed between the inner condyle of the femur, and the corresponding part of the tibia. The fistulous aperture on the inner side of the knee communicated with the cavity of an abscess beneath the vastus internus on the posterior surface of the os femoris, which in several places was deprived of its periosteum, and superficially carious.

It may now be asked what share the treatment adopted had in the unfavourable issue of the injury? I cannot attribute much to the operation which was performed, from the little irritability of the parts involved. It must, however, be observed, that in dividing the common tendon of the extensor of the leg, the capsular ligament of the joint, which is immediately subjacent to the insertion of this into the patella, would be wounded; a wound, however, of not more importance than that performed for the removal of loose cartilages from the joint. Of far greater consequence in my estimation, was the position of the unreduced patella, which contributed to the inflammation succeeding the accident, and, by the pressure exercised on the cartilaginous covering of the femur, occasioned its destruction. If death had not resulted, from the cause already specified, perhaps complete anchylosis would have been the termination of the diseased condition of the joint.*

* If in any future case the reduction should appear impossible, without dividing the tendon of the patella, it should be performed by what is called *subcutaneous section;* that is, by merely puncturing the skin on one side of the tendon, and introducing a curved pointed bistoury, so as to divide the tendon without enlarging the wound in the skin. This would be much less likely to do mischief than the long incision that was practised in this case; and certainly the separation of the muscle from the upper margin of the patella could hardly be necessary under any circumstances. But a case rendering any operation necessary must be most rare.—*Ed.*

The following unfortunate case is exceedingly rare. It is narrated by Mr. Key in the Guy's Hospital Reports.

Case CXI.—A young woman about twenty years of age, florid and apparently in good health, slipped and fell whilst carrying a pail. In attempting to rise from the ground, she found that her left knee gave her exquisite pain, and was unable to bear her weight. When she was brought to the hospital, the patella was found resting on the inner condyle; the outer part of its articular surface being supported obliquely by the projecting edge of the trochlea of the femur. Gentle pressure on the inner edge of the patella as the limb lay on the bed, reduced it to its natural position. The joint showed signs of inflammatory action on the following day, in a very distended state of the synovial membrane and considerable increase of heat. The usual means for its reduction were employed, and with benefit for a few days. The joint, however, again became swollen and tender, and a sharp attack of fever supervened. At the end of the second week, the local appearances and the extent of the constitutional disturbance clearly told the nature of the action under which the joint was suffering. The measures that were employed failed to arrest the destructive inflammation; typhoid symptoms came on; and the cellular tissue surrounding the joint became the seat of acute suppuration. Large bags of matter quickly formed under the extensor muscles of the thigh, and under the gastrocnemii. On examination of the interior of the joint after death, scarcely a vestige of ligament could be discerned; the crucial and the mucous ligaments were wholly destroyed by ulceration; the cartilage on the end of the femur and patella was peeling off in flakes; and that of the tibia was in a similar, though less advanced state; the semi-lunar cartilages had undergone no change, beyond showing unusual signs of vascularity on their surface; the tendon of the external vastus was partly torn through.

The mischief that ensued, observes Mr. Key, is more to be attributed to the girl's habit of body, than to any peculiarity in the dislocation. Though her appearance was healthy, her constitution was described by her friends as not strong, and she bore the signs of a strumous diathesis; she was also expecting the period of menstruation when the accident took place.*

* Key, Guy's Hosp. Rep. Vol. i. p. 260.

Dislocation from relaxation.—When the patella is liable to be dislocated from relaxation, it may be drawn upon the external condyle of the os femoris by very slight accidents, or sudden action of the muscles. My neighbour, Mr. Hutchinson, a very intelligent surgeon, informs me he has very frequently seen this accident, and that the tendency to it has arisen, in a large proportion of cases, from the relaxation produced by excessive indulgence in onanism.

The reduction, in these cases, is effected in the manner which has been before described; and after the reduction, to prevent any recurrence of the accident, and to support the weakened ligament, a laced knee-cap, with a strap and buckle above and below the patella, is to be worn.

I once saw the patella drawn over the external condyle of the os femoris from loss of action of the vastus internus, owing to a disease in the thigh-bone.

Dislocation of the patella upwards.—In this dislocation, the ligament of the patella is torn through by the action of the rectus femoris muscle, and the immediate effect of the injury is to draw the patella upwards upon the fore part of the thigh-bone. The appearances which this accident presents are very decisive of the nature of the injury; for, beside the elevation of the patella, and its easy motion from side to side, a deep depression is felt above the tubercle of the tibia from the absence of the ligament; the patient immediately loses the power of bearing upon that limb, as the knee bends under each attempt, and he would fall if he persisted in throwing the weight of his body upon it. A considerable degree of inflammation follows this accident.

Treatment.—In the treatment of this injury, local depletion and evaporating lotions are to be used during six or seven days from the accident, or at least till the inflammation has subsided; then a roller is to be applied around the foot and upon the leg, to prevent its swelling; the leg is to be kept extended by a splint behind the knee, and a bandage, composed of a leathern strap, is to be buckled around the lower part of the thigh; to this is to be attached another, which is to be carried on each side of the leg, and under the foot, and is to be buckled to the circular strap; thus the bone is gradually drawn down, so as to allow of a union of the ligament. In a month the knee may be

slightly bent, and as much passive motion daily given as the patient is able to bear; by these means the ruptured ligament becomes united, and the patella retains its motion. During the cure, the patient is to preserve the sitting posture, in order to relax the rectus muscle and to prevent its action upon the patella. With very great attention the union becomes perfect; for so it happened in a case which I saw with Mr. Burrowes, in Bishopsgate Street. Mr. B. paid great attention to the case, and the patient recovered without any diminution of the natural powers of the part; the patella being gradually forced down until the ends of the ligament had approximated and coalesced.

Dislocation downwards.—With respect to dislocations of the patella *downwards*, at which some surgeons have hinted, I have seen no injury which deserved such a title, if I except a rupture of the tendon of the rectus, which I have twice witnessed, and which destroyed the attachment of that muscle to the patella. The appearance of this injury was a soft swelling above the patella, upon which, when the hand was placed, it sunk into the joint; the patella felt loose between the condyles of the os femoris and the head of the tibia, but it still retained very much its usual situation, and could not be said to be luxated, as it was not displaced from the joint. The treatment which this accident requires is, that the patient be obliged to preserve a sitting posture during the cure; and that a cushion be applied upon the ligamentum patellæ, which is to be confined by a roller passed around the head of the tibia.

SECTION III.

DISLOCATIONS OF THE TIBIA AT THE KNEE-JOINT.

These dislocations occur in four different directions; but two of them are incomplete and lateral, while the others are perfect luxations, the tibia being thrown either backwards or forwards.

Dislocation inwards.—The lateral dislocations are but rare. In the dislocation inwards the tibia is thrown from its situation, so that the internal condyle of the os femoris rests upon the external semilunar cartilage, and the tibia projects on the inner side of the joint, so as at once to disclose the nature of the injury.

CASE CXII.—The first case of this kind which I ever witnessed was brought to St. Thomas's Hospital whilst I was an apprentice there, and I remember being struck with three circumstances in it: the first was, the great deformity of the knee from the projection of the tibia; the second, the ease with which the bone was reduced by direct extension; and the third, the little inflammation which followed upon what appeared to be so serious an injury; for the man was discharged from the hospital after a few weeks, having suffered little local or constitutional irritation.

CASE CXIII.—James Plunkett, æt. forty five, was admitted into Guy's Hospital, under the care of Mr. B. Cooper, on June 18th, 1833, for an injury to the knee. He had fallen off from a ladder for the distance of two or three feet, with his left knee bent under him, as he describes it, nearly at a right angle. On his admission his knee was found to possess its natural shape. His fellow workmen said that great deformity had been produced by the injury, but that he removed this by getting one workman to extend the leg, while he pushed a *lump* (which must have been the head of the tibia,) outwards, into its natural place. This account left no doubt of his having dislocated the head of the tibia inwards. It was ascertained that the internal lateral ligament, and some fibres of the vastus internus muscle had been ruptured; this was indicated by an unnatural hollow on the inner side of the knee-joint, opposite to the space between the two bones. From the extent of the displacement which had been described, it was most probable that the crucial ligaments had been torn through. The patient complained of great pain both on motion and pressure; and although at the time of his admission there was but little tumefaction, the limb soon swelled rapidly.

The limb was placed on a double inclined plane, and secured by a roller loosely applied to the foot and to the lower part of the thigh; twenty leeches and an evaporating lotion were ordered, and the bowels were moved with calomel, colocynth, and antimony.

The next day the swelling had increased, and there was considerable ecchymosis of the upper part of the calf. More leeches were applied.

On the 26th the swelling had nearly disappeared, excepting at the upper part of the calf, where there was still considerable

ecchymosis. There was some hardness and swelling perceptible in the situation of the saphena major vein, leading to the supposition that it had been torn through in the accident, which was further indicated by the enlargement of the collateral venous branches. The patient gradually improved from this time, and on the 3rd of June the inflammation of the joint had entirely subsided; the whipcord hardness of the saphena had diminished; and at the end of June he left the hospital, able to walk with a stick.*

Dislocation outwards. — The tibia is sometimes thrown upon the outer side of the knee-joint; the external condyle of the os femoris being placed in the situation of the inner semilunar cartilage, or rather behind it, when a similar deformity is produced as in the internal dislocation. The reduction of the limb is equally easy with the former, and the patient recovers with little diminution of the powers of the part. It seems to me that in both these dislocations the tibia is rather twisted upon the os femoris, so that the condyle of the os femoris, with respect to the tibia, is thrown somewhat backwards, as well as outwards or inwards.

Case CXIV.—One of the aldermen of the City of London, riding down Highgate Hill during the night, and not being aware of a rail that was placed across a part of the road which was undergoing repair, the horse ran against the rail, and, turning quickly, threw his rider over it, whilst his leg was confined between the rail and the horse, so that his body was on one side of the rail, and his leg on the other: the result of this accident was, that he partially dislocated his tibia outwards, throwing the condyle of the os femoris inwards. Being immediately taken to a public-house, the tibia was easily replaced; and on his removal home, some hours afterwards, means were used to reduce the swelling and inflammation, which became considerable. When he attempted to bear upon the limb he found the capsular ligament very feeble, and he was obliged to have a knee-cap made of very strong leather, to support and connect the bones; by the aid of this bandage he gradually recovered, and was enabled to walk well, and to do duty on horseback as a light-horse volunteer, before twelve months had expired.

Case CXV. — I was consulted by Mr. Richards respecting Mr. Bovill, a gentleman from Barbadoes, who had dislocated his

* Surgical Essays, p. 246.

knee. I made a few notes on the case at the moment, which were as follow:—The gentleman was thrown from a gig; the tibia was dislocated, and the fibula broken a little below its head. The head of the tibia projected much on the inner side of the condyle of the os femoris. My friends, Mr. Caddell and Mr. Richards, surgeons at Barbadoes, saw him a quarter of an hour after the accident; the leg was extended from the thigh-bone in a bent position of the limb; the extension was a long time continued, and force was employed by several persons for half an hour before the luxation was reduced. The limb became excessively swollen, and remained so for many weeks, the climate probably being unfavourable to his recovery; but at length the inflammation and its consequences were subdued by local depletion. When I saw him, eighteen months had elapsed from the accident, and he could not then bend the joint at right angles with the thigh; there was also an unnatural lateral motion of the joint, from the injury which the ligaments had sustained. The fracture of the fibula had injured the peroneal nerve, as was evident from the numbness of which he complained in the outer part of the leg and foot.

Dislocation forwards.—The tibia is now and then dislocated in a direction forwards. In this accident, when the patient is recumbent, the external marks of the injury are these:—The tibia is elevated; the thigh-bone is depressed, and is thrown somewhat to the side as well as backwards; the os femoris makes such pressure on the popliteal artery, as to prevent the pulsation of the anterior tibial artery on the foot; the patella and tibia are drawn by the rectus muscle forward.

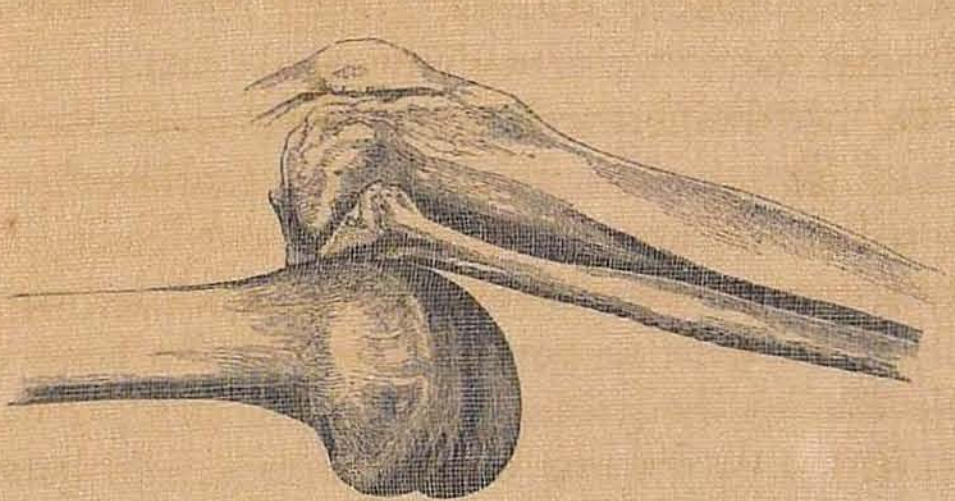

Case CXVI.—Such were the appearances in a man of the name of Briggs, brought into Guy's Hospital in the year 1802,

not only with this accident, but with a compound fracture of the tibia of the other leg, with dislocation of the head of the fibula. Mr. Lucas was obliged to amputate the compound fracture, and the man is now living at Walworth. The limb in this case was easily reduced by extending the thigh from above the knee, and by drawing the leg from the thigh, and inclining the tibia a little downwards. As soon as it was reduced, the popliteal artery ceased to be compressed, and the pulsation in the anterior tibial artery was restored.

CASE CXVII.—E., æt. sixty-five, of a spare habit, but hale and ruddy complexioned, by employment a stonemason's labourer, was stooping to clear away some rubbish beneath a portico that was just completed, when the stone forming the architrave, weighing nearly seven hundred weight, broke in two, and falling upon him bore him to the ground. His right hand was jammed under one fragment, which it was necessary to lift to extricate it. He could not stand for the shock, and for some injury to the left knee. The accident happened about half past five on the 23rd of February 1841; he was shortly afterwards brought to the Middlesex Hospital, where Mr. Mayo, the senior surgeon, saw him between six and seven.

The first impression on looking at the injured knee was, that the femur was broken immediately above the condyles, where there was a considerable depression, and there seemed to be motion. But upon a closer examination the femur proved to be entire, the depression being caused by the head of the tibia overlying that bone. The condyles of the femur, the outer stretching the skin very tensely, were to be felt behind the upper ends of the tibia and fibula, the extremity of the condyles being fully four inches below the level of the articular surface of the tibia. The position which the displaced bones assumed was that of slight flexion; the pulsation of the anterior tibial artery on the instep could not be felt.

Two brief and ineffectual attempts were made by hand to reduce the dislocation, keeping the bones slightly flexed. Then a round towel was passed within the limb to get a purchase upon the ischium and pubes; this was fastened to the irons of the head of the bed. Another round towel was secured by a clove hitch upon the malleoli and instep. Using these means, slight extension was made upon the leg, and in about a minute the

reduction of the dislocation was accomplished. The limb was then laid straight upon a pillow, and supported laterally by junks.

Mr. Mayo proceeds to say that the case did perfectly well, and that the hand was amputated.*

The two following cases were sent me by Dr. O'Beirne of Dublin; the first occurred in his own practice; the second in that of Dr. Franklin of Limerick.

Case CXVIII.—John Goff, more than fifty years of age, of small stature, and rather delicate make, and employed as a porter, was admitted into the Charitable Infirmary, Jervis Street, Dublin, on the 28th of August 1819, for an accident which he met with a few hours previously. While carrying a large heavy basket on his back, he advanced his right leg, and, in the act of bringing forward the left, felt the point of that foot caught in a small hollow or opening between two flags. He made a sudden and violent effort to disengage it, but, not succeeding, was thrown forward by the weight of his load, and fell on his face. As he lay, the left leg remained extended, but when he was lifted it hung backwards, and with such violent pain, that a person was obliged to support it in the extended position while he was in the act of being conveyed to the infirmary.

His general state on admission was as follows: — He was pale, weak, complaining of great pain, and his pulse was small and rather quick. The left leg was shorter by three inches and a half than the right, and was directed backwards and flexed so as to form a very obtuse angle with the corresponding thigh. The condyles of the left femur projected in a very remarkable degree, into the ham; the tibia, fibula, and patella were situated in front of the thigh, and so high up that their upper extremities corresponded to the top of the lower third of the femur. The outlines of the displaced bones were well marked and distinctly seen. The leg readily admitted of being moved from side to side, and, while this was doing, the tibia and fibula were felt gliding freely and without pain on the anterior surface of the femur; but the patella did not follow the motions of these bones to any great extent, although it was so movable that it might be drawn with great ease either upwards, downwards, forwards, or to either side. The whole of the limb was free from swelling or mark of contusion; yet it presented a singular kind of de-

* Lond. Med. Gaz. vol. xxvii. p. 869.

formity, in consequence of there being no vestige of a knee-joint, and of the large tumours formed by the displaced bones in front of the thigh, and in the ham.

I regret to say that I omitted to ascertain whether the anterior tibial artery pulsated or not, or to note the temperature of the leg and foot.

The reduction of this very rare and formidable-looking dislocation, in which I was assisted by Dr. Mitchell, was effected in less than a minute, and with greater ease than can well be imagined. The following was the plan employed:—While one assistant grasped the highest part of the thigh with both hands, and kept up counter-extension, and another made extension from the ankle and foot, in the direction of the axis of the displaced tibia, I placed my left hand behind the ham, my right upon the front of the thigh, and, by acting with both, succeeded in raising the tibia and fibula, carrying them downwards, over the condyles of the femur, into their natural situation. For about a second, however, the bones forming the joint were observed to undergo various rapid and very short oscillatory motions, accompanied by a scraping noise, until the articular surfaces came into exact apposition. The moment that this occurred the patient found that he could stand on the limb, and flex or extend it nearly as well as ever, and that the pain which he had previously suffered was very considerably relieved. He was immediately placed in bed, with the injured limb in the extended position, a long splint on its outer, and a shorter on its inner side; lint dipped in cold water was laid over its whole length, and kept constantly sprinkled with the same fluid, and twenty leeches were directed to be immediately applied to the knee.

On the following morning, 29th of August, I was agreeably surprised to find no constitutional disturbance nor pain. Moreover, the leeches had been forgotten to be applied. The limb was kept at rest for six weeks; and at the end of five weeks more, by dint of repeated friction, bandages, and exercise, the joint was restored to its natural powers, and the poor man was able to pursue his laborious occupation as before.

Case CXIX.—Patrick M'Donnell, æt. thirty, a very muscular labourer, was admitted, on the 20th of December 1833, into Barrington's Hospital, in Limerick. About twenty minutes previously, on ascending a plank whilst he had a weighty

sack of corn on his back, he felt his right knee start. The sack of corn fell on his ham, and he was thrown forward on his face and hands. On examination (which was attended with great pain,) his knee was found dislocated. The patella and the heads of the tibia and fibula were thrown upwards and forwards on the front of the thigh-bone; a considerable tumour was formed in the popliteal space by the lower end of the femur. Every attempt at motion was attended with severe pain.

Upon pressing down the patella and the bones of the leg, by placing the thumbs of both hands over the former, while at the same time the fingers were placed under the lower end of the femur, in the ham, and pressing the femur upwards, the bones immediately started into their natural situations with a snap. The man now felt easy, and could lift the limb and move it a little. He was directed to lie on his right side, to keep the limb in a semi-flexed position, and to have a cold lotion constantly applied.

A slight degree of inflammation ensued, but on the 2nd of January 1834, the patient was discharged well.

Dislocation backwards.—The head of the tibia is sometimes dislocated backwards, behind the condyles of the os femoris, producing the following appearances:—a shortened state of the limb, a projection of the condyles of the os femoris, and depression of the ligament of the patella, and the leg is bent forwards.

For the following case I am indebted to my friend Dr. Walshman, who has ever been a man of close observation in his profession, and has always practised it with attention, judgment, and honour.

Case CXX.—Mr. Luland, a very robust and muscular man, on the 4th of January 1794, dislocated his shoulder and knee at the same instant. The accident happened in the following manner:—It was a severe frost, and the ground very slippery, and he being in his cart, the horse fell. Mr. Luland was thrown under the front rail of the cart, and luxated the tibia backwards, whilst his shoulder fell on the saddle, and dislocated the os humeri into the axilla. The head of the tibia was completely dislocated backwards, reaching behind the condyles of the femur into the ham; the tendinous connexion of the patella to the rectus muscle was ruptured; the external condyle of the os femoris was very protuberant; the leg was bent forward and

was shortened, and there was a depression just above the patella. The patient felt most excruciating pain when the limb was moved, but there was not any considerable degree of suffering when it was at rest. The reduction was effected in the following manner:—Two men extended upwards, one from the groin, and the other from the axilla, whilst two others extended the leg from a little above the ankle in the opposite direction; and they gradually increased the force of their extension till the bone was reduced. The patient was placed on his back, and Dr. Walshman directed the head of the bone to its natural situation. Dr. W. then applied a flannel roller on the knee, placed the patient in bed with his limb upon a pillow, and directed the part to be kept wet with an evaporating lotion. He remained in this state a fortnight, free from pain; the Doctor slightly moved the part every other day, as far as he could without giving pain. In about a month Mr. Luland began to walk on crutches. Ten weeks after the accident he was able to sit at his dinner-table, and in five months he had given up the use of his crutches, and appeared perfectly recovered, being able to use that limb as well as the other. He died of dropsy in February 1819.

Dr. Walshman's treatment of this case was highly judicious. He suffered the parts, as he observes in his letter, to remain at rest till the lacerated ligament had united by adhesion, and then, and not till then, began with passive motion.

SECTION IV.

PARTIAL DISLOCATION OF THE THIGH-BONE FROM THE SEMI-LUNAR CARTILAGES.

Under extreme degrees of relaxation, or in cases in which there has been increased secretion into the joint, the ligaments become so much lengthened, as to allow the cartilages to glide upon the surface of the tibia, and particularly when pressure is made by the thigh-bone on the edge of the cartilage. That excellent practical surgeon, the late Mr. Hey, of Leeds, was the first who clearly described the symptoms and cause of these

accidents, and suggested a mode of treatment which is ingenious, scientific, and generally successful. The injury most frequently occurs when a person in walking strikes his toe, with the foot everted, against any projection (as the fold of a carpet), after which he immediately feels severe sickening pain in the knee, and is unable to straighten the limb. I have seen this accident also happen from a person having suddenly turned in his bed, when the clothes not suffering the foot to turn readily with the body, the thigh-bone has slipped from its semilunar cartilage. I have also known it occur from a sudden twist of the knee inwards when the foot was turned out.

The explanation of this accident is as follows:—The semilunar cartilages, which receive the condyles of the os femoris, are united to the tibia by ligaments, and when these ligaments become extremely relaxed and elongated, the cartilages are easily pushed from their situations by the condyles of the os femoris, which are then brought into contact with the head of the tibia; and when the limb is attempted to be extended, the edges of the semilunar cartilages prevent it.

Treatment.—How, then, is the bone to be again brought upon the cartilages? Why, as Mr. Hey has advised, by bending the limb back as far as possible, which enables the cartilage to slip into its natural situation; the pressure of the thigh-bone is removed in the bent position, and the leg being brought forwards, it can then be completely extended, because the condyles of the os femoris are again received on the semilunar cartilages. This plan is not, however, invariably successful, as the following case will show.

Case CXXI. — A lieutenant in the army suffered this accident repeatedly, and the limb was as often reduced by the above means; but at length in turning in bed, from the pressure of the bed-clothes on his foot, the accident recurred. He came to town; but bending the limb had now no effect in enabling him to extend the joint: I therefore advised him to visit Mr. Hey, at Leeds; but I learnt that in this case the dislocation was never reduced.

Case CXXII. — I made the following notes of the case of a gentleman who came to my house. Mr. Henry Dobley, aged thirty-seven, has often dislocated his knee, turning the foot inwards and the thigh-bone outwards, by accidentally slipping in

walking on uneven ground, or by sudden exertions of the limb; considerable pain was immediately produced, accompanied with a great deal of swelling. His mode of reducing it is as follows: he sits upon the ground, and then bending the thigh inwards and pulling the foot outwards, the subluxation of the os femoris being external, the natural position of the limb becomes restored. A knee-cap, laced tightly around the knee, is the usual preventive of the return of this accident; but it is not sufficient in Mr. Dobley without the addition of straps, and more especially of a very strong one of leather, just below the patella.

A young lady was brought to my house who was frequently the subject of this accident, but in her the cartilages had been several times easily replaced, and the return of the accident prevented by a bandage composed of a piece of linen with four rollers attached to it, which were tightly bound above and below the patella; this, she said, answered its intended purpose better than any other contrivance.

Great alteration takes place in the form and size of the knees, in some of these cases, from a chronic rheumatism occasionally attending them. I made the following notes of a case of this kind on which I was consulted, and I have seen others similar to it.

Case CXXIII.—Lady D., a year and a half ago, fell, and twisted her thigh-bone inwards at the knee, producing great pain on the inner side of the joint. Her ladyship immediately restored the parts to their situation by pressing the thigh outwards and the leg inwards, previously to which she could not move the joint. For a fortnight she was scarcely able to bend or straighten the knee, and the muscles felt to her to be in a state of cramp. She then began to stand upon the limb by the aid of crutches; but when she bore upon it considerably, it suddenly bent back, with pain and subsequent swelling, and she felt the condyles at the same time slip from the semilunar cartilages upon the head of the tibia. Any sudden motion produced the same effect for fifteen months, and each of these accidents retarded her recovery for several weeks; the pain extended from the knee to the toe. For three months previous to her last accident, she walked on crutches, and even sometimes with only the aid of a stick; when, about two months since, in endeavouring to raise herself from a sofa, the left knee gave way as if the bone had slipped from its

place, the thigh-bone being at the time twisted outwards; pain and swelling succeeded, and she has never been able to stand upright since. *Her joints are all of them remarkably flexible*, as the elbow may be easily bent backwards to form an angle with the os humeri. When a girl, she had frequently the sensation of putting the knees out of joint, but they soon got well. The knees are now swollen, and effusion of a considerable quantity of synovia has taken place into the joints. When she attempts to stand she cannot straighten her knees, but would fall forwards if unsupported.

The principal object in the treatment was, to produce absorption of the fluid which was effused, and then to give due support to the ligaments. For the first of these she was desired to apply blisters, which were directed to be kept discharging for a considerable time, and after they were healed, she was ordered to make pressure upon the joints by a strong bandage, which was to be occasionally removed to give an opportunity of employing friction. She received material benefit from a constitutional treatment, consisting of Plummer's pill, with sarsaparilla, and locally from the continued use of friction. By these means, she perfectly recovered.*

In the dissection of these cases, the ligament is found extremely thickened; little pendulous ligamentous and cartilaginous bodies are seen suspended from it; a thick edge of cartilage projects from the articular cartilage, and a part of the latter is absorbed. When the bone is macerated, a great addition of ossific matter is found to have been made to the edges of the condyles of the os femoris.

CASE CXXIV. — *Dislocation of the external semilunar cartilage of the right knee, unreduced.*†—A young woman, æt. twenty-two, met with an accident in slipping down a step. When

* A very useful way of treating similar cases of relaxation and effusion into joints is that recommended by Mr. Scott. (*Vide* Scott on the Joints.) The part, at first, is to be washed with spirits of camphor, and then to be completely enveloped in an ointment composed of equal parts of mercurial ointment and soap cerate, with a little camphor, (*ceratum hydrargyri compositum* of the Pharmacopœia,) spread thickly on lint; this is to be covered with several layers of strips of adhesive plaster, spread on linen or leather, and applied tightly enough to yield a comfortable feeling of support; and the whole to be covered with a bandage. This plan combines the advantage of support, slight counter-irritation, and the application to the skin of a substance capable of exciting absorption.—*Ed.*

† Lond. Med. Gaz. vol. vii. p. 704.

brought to the London Hospital, she was able to stand on her left foot only, while she balanced herself on the toe of the right, which last she was unable to bring flat to the ground. The knee was partially bent, and could not, by any force applied to it, be fully extended, nor could it be bent to so acute an angle as naturally. The toe was turned a little outwards, and the tibia inclined in the same direction; the inner part of its head bore its natural relation to the inner condyle of the femur; the outer part, however, was carried a little backwards, leaving a hollow under the corresponding condyle, and forming a slight projection behind, not discoverable except by pressing on the part with the finger. The outer condyle, with its articular surface, was more prominent under the skin than usual, in consequence of the partial removal of the tibia from its front part. There was considerable pain when the joint was moved, and not any perceptible alteration in the tension of the ligaments. These symptoms were considered indicative of a dislocation of the external semilunar cartilage from the condyle, and the treatment pursued was in accordance with this opinion.

The following methods of reduction were successively tried by Mr. Luke:—1st. Extension of the leg while pressure was made against the back part of the tibia, and counter-pressure on the front of the condyles. 2ndly. The foot was drawn inwards towards the opposite leg, while the condyles were pulled outwards in the opposite direction, pressure being made at the same time against the outer and back part of the head of the tibia. 3rdly. A rolling-pin guarded with linen was placed in the ham, and the knee forcibly bent over it. Neither of these plans, however, succeeded. Some inflammation followed; after which she left the hospital in a month, still unable to bring her heel to the ground, or to extend the knee beyond a certain point.

SECTION V.

COMPOUND DISLOCATION OF THE KNEE-JOINT.

Of this I have only seen one instance, and I conclude it therefore to be a rare occurrence; and there are scarcely any acci-

dents to which the body is liable which, generally speaking, more imperiously demand immediate amputation than these.

Case CXXV. — On Monday, August 26th, 1819, at eleven P. M., I was sent for by Mr. Oliver, surgeon, at Brentford, to visit Mr. Pritt, who had fallen from the box of a mail-coach, and most severely injured his knee. I met, at the house to which he was carried, Mr. Oliver, and Mr. Hunter, of Richmond, surgeons, and immediately proceeded to examine the knee. A large opening was found in the integuments, through which the external condyle of the os femoris projected, so as to be on a level with the edges of the skin. The os femoris was thrown behind the tibia on the outer side of the head of the latter, and the external condyle of the thigh-bone was dislocated backwards and outwards; the thigh-bone was twisted outwards, and the internal condyle advanced upon the head of the tibia. I made attempts to reduce the condyle, but it could only be effected with extreme difficulty; and the bone, directly when the extension was removed, slipped into its former situation. The joint being freely opened by the accident, the bone being dislocated, and when reduced easily slipping from its place, and the patient having an extremely irritable constitution, decided me at once to propose the amputation of the limb, which, being acceded to, was immediately performed. The symptoms of constitutional irritation which followed the operation became extremely severe; and he being delirious on the 31st, Mr. Oliver applied leeches to his temples, a blister under the occiput, and gave saline medicine, with camphor, and Dover's powder. On the following day I was sent for to visit him, but being absent from London, my most able and excellent friend Mr. Cline visited him, and ordered him tinc. opii. gtt. v.—Pulv. castor. gr. x.—Mist. camphor. ℥iss. every four hours. Soon after the second draught was administered he fell asleep, and after several hours' repose awoke perfectly sensible. He gradually recovered, and left Brentford on the 25th of October, with a small wound still remaining on the stump.

I brought home the limb, and carefully dissected it. Under the skin there was great extravasation of blood in the cellular membrane surrounding the knee; the vastus internus muscle had a large aperture torn in it just above its insertion into the patella; the tibia projected forwards, and the patella was drawn

to the outer side of the knee, being no longer in a line with the tubercle of the tibia. Looking at the joint posteriorly, both heads of the gastrocnemius externus muscle were lacerated; the capsular ligament was so completely torn, posteriorly, that both the condyles of the os femoris were seen projecting through the laceration in the gastrocnemius; neither the sciatic nerve, the popliteal artery and vein, the lateral, nor the crucial ligaments, were ruptured.

It is probable that all compound dislocations of the knee-joint will require a similar practice, unless the wound be so extremely small as to admit readily of its immediate closure and adhesion, as in the following highly interesting case.

Case CXXVI.—Paul Hodgkinson, a healthy labouring man, about thirty years of age, in driving a heavily-laden one-horse cart down a steep hill, on the 1st of October 1827, had the misfortune to be thrown down, and the wheel passed over the right thigh, just above the knee. A very profuse hæmorrhage immediately took place.

Mr. Shaw, surgeon, of Wirksworth, saw the patient in less than an hour after the accident, and on examination found there was a compound dislocation of the knee-joint. There was an opening in the integuments about the natural situation of the internal condyle, which communicated with the cavity of the joint: the os femoris was thrown behind the head of the tibia, and lay imbedded among the gastrocnemii muscles. The limb had a most deformed and frightful appearance; but Mr. Shaw accomplished the reduction of the dislocation with greater ease than he had expected. The opening in the integuments was closed by adhesive plaster, the limb was laid on pillows, and scarcely any inflammation supervened. Two or three days after

the accident the patient complained of some degree of numbness and coldness of the leg and foot, particularly the latter: this sensation continued to increase, but in other respects he was so well, that on the ninth day from the accident he got out of bed and sat up a short time, being able to bend and extend the knee without occasioning pain. On the eleventh day it was first discovered that there were some vesications on the foot, and on the the 19th October, eighteen days from the time of the accident, Mr. Shaw requested me to visit the patient with him. At this time the whole of the foot was in a gangrenous state. On the outside of the limb the mortification extended about three inches above the malleolus, but it did not rise above the ankle on the inner side. The whole leg above the sphacelated parts was very tender to the touch, was slightly swelled and hot, and had a blush of redness all over it. There was some degree of hardness and thickening of the parts between the hamstrings, and no pulsation was discoverable in the popliteal artery. In other respects the knee seemed well, being free from pain, inflammation, or swelling; and the patient had the power of bending and extending the joint without assistance or inconvenience. His general health was good.

A lotion of the chloride of soda diluted with water was applied to the gangrenous parts, and over it an antiseptic poultice. The leg was wrapped in a poultice of white bread and Goulard's lotion. The bark and sulphate of quinine, with sulphuric acid, were given in such doses as the patient could bear, and opium at night to allay irritation. For three or four days there seemed reason to hope that a line of separation was forming between the mortified and the healthy parts; but this hope was fallacious, and on the 24th October the limb had assumed a much more unhealthy aspect. On the outside of the ankle the mortification had extended two or three inches higher, and the whole leg was much more swollen and tender, and had a more inflamed and sanguine appearance. The health of the patient also declined. On tapping along the tibia with the fingers a hollow sound was emitted, which was very striking and peculiar, and seemed to indicate a carious state of the bone. At this examination a small cutaneous artery was found pulsating very strongly on the inside of the knee.

Taking all the circumstances of the case into consideration,

there did not appear to be any probability of preserving the leg, and as the patient's health was daily declining, we determined to amputate the limb above the knee.

October 28th. The operation was performed: five arteries were tied; the femoral pulsated much more strongly than it is usually found to do.

November 9th. The healing of the stump is proceeding, though all the ligatures are not yet come away.

On examining the limb it was found to be a complete mass of putridity; and on cutting into it to dissect it there issued an immense quantity of a fœtid sanious fluid. The popliteal artery was ruptured, and a coagulum was found in the extremity of the vessel, enclosed, as it were, in a cul de sac. We did not discover that either the vein or the sciatic nerve was lacerated. The capsular ligament was completely torn from its attachments, and had not united again. The bones of the leg were sound.*

Dislocation of the Knee from Ulceration.—In the progress of chronic diseases of the joints, inflammation beginning in the synovial membrane, and proceeding to ulcerate the articular cartilages and bone, at length the capsular ligament, and sometimes even the peculiar ligaments of the joints are destroyed; and the bones thus becoming unconnected, the muscles irritated by participating in the inflammation, draw the limb into distorted positions, and thus one bone becomes gradually displaced from the other. This state is most frequently seen in the hip-joint, from the oblique bearing of the thigh-bone on the pelvis. In the knee it is also not unusual that the thigh-bone shall be placed out of its natural line with the tibia, projecting either on the one side or the other.

Now and then most remarkable distortions are produced by the irritative and spasmodic action of the muscles succeeding ulceration of the ligaments, of one of which I have given a plate; Mr. Cline removed it by amputation in St. Thomas's Hospital. It had been the consequence of what is vulgarly

* A patient was admitted into Guy's Hospital under Mr. B. Cooper, with a compound fracture of the lower third of the right femur; and four days afterwards, a diffused pulsation in the ham led to the discovery that the popliteal artery was ruptured. The femoral was secured in the upper third of its course, without removing the patient from bed; and within a month the wounds were healed, the fracture united, and the patient declared convalescent.—*Ed.*

called the white swelling of the knee-joint: the leg was placed forwards at right angles with the thigh, so that when walking on his crutches he had the most grotesque appearance, as the bottom of his foot first met the eye when he was advancing. Upon inspection of the patella it was found anchylosed to the os femoris, and the tibia was also joined by ossific union to the fore part of the condyles of the thigh-bone. See the figure at p. 12.

This state of parts may be prevented by opposing the action of the muscles when their irritability first begins to produce distortion, by the application of splints, and by the exhibition of henbane, Dover's powder, sarsaparilla, and other proper medicines to restore the secretions and diminish the irritability of the system. Thus I have seen, in cases of ulceration of the hip-joint, the irritative action of the flexor muscles diminished, and future distortion prevented, by drawing down the limb and keeping it in the extended position;* but as this extension is most painful to the patient, however desirable it may be, it should be accomplished very gradually.

SECTION VI.

DISLOCATIONS OF THE HEAD OF THE FIBULA.

The fibula joins the tibia three quarters of an inch below the articulation of the knee. Its head is enclosed in a capsular ligament which unites it to the tibia, to which it is also joined through the greater part of its length by the interrosseous ligament.

This bone is liable to dislocation, both from violence and from relaxation. I have only seen one case of it from violence; and in that instance it was connected with compound fracture of the tibia. —— Briggs, of whose dislocation of the tibia I have given an account, (Case CXVI.) had, at the upper part of the other leg, a compound fracture of the tibia, and dislocation of the head of the fibula. An attempt was made to save the limb,

* This is a most important principle in the treatment of chronic disease of joints; but it is too frequently neglected.—*Ed.*

but the constitutional irritation ran so high, that amputation was obliged to be performed; which was done by my colleague, Mr. Lucas, and the man was restored to health.

While these sheets were passing through the press, the Editor received the following case of this rare accident from Dr. Bossey, of Woolwich.

Case CXXVII. — Samuel Stroud, æt. twenty-five, a stout muscular man, was admitted into Guy's Hospital, under Mr. B. Cooper, for a fracture of the right femur and dislocation of the left fibula, both accidents being occasioned by the passing of a waggon-wheel over his limbs, while, as he supposes, one was crossed over the other.

The thigh was fractured rather below its middle, and when admitted there was evident deformity of the limb, produced by the upper portion of the bone projecting inwards, while the lower one protruded outwards. There was also slight shortening of the limb, and eversion of the foot. Extension restored the limb to its natural length and shape, which were preserved by placing it on the double inclined plane, and by the application of splints. In the left leg the fibula, when traced upwards, seemed to pass more backwards than natural. It was also more movable than usual, and the upper part of the bone was felt in the popliteal space. There was little deformity visible, but the projection of the outer head of the soleus muscle was not quite so distinct as in the other leg, and there was a want of firmness in this part when pressure was made upon it. There was scarcely any pain given by motion of the limb, and the man possessed the power of extending it perfectly and of flexing it to a considerable extent, but whether he could completely flex it was not ascertained. The dislocation was reduced by bending the leg to relax the biceps muscle, and then grasping the head of the fibula and pressing it into its natural situation. After the reduction, moistened pasteboard and a bandage were applied around the joint, to keep the bone in its place till reunion of the ligaments should occur. This not being sufficient to confine the fibula, and prevent the biceps drawing it back, a tourniquet pad was applied over it, and by means of this the head of the fibula was forcibly pressed forwards; this was continued nearly two months, at the end of which time, the fibula remained rather behind its usual situation, but was perfectly fixed. The thigh also was

well united, and when he could walk, the left leg was as strong as before, and he felt no inconvenience from the dislocation.

Dislocations of the head of the fibula from relaxation, are more frequent than those which occur from violence; the head of the bone, in these cases, is thrown backwards, and is easily brought into its natural connexion with the tibia, but it directly again slips from its position. This state produces a considerable degree of weakness, and fatigue in walking; and the person suffers much from exercise. As in these cases there is a superabundant secretion of synovia, and a distention of ligament, repeated blistering is required to promote absorption; and afterwards a strap is to be buckled around the upper part of the leg, to bind the bone firmly in its natural situation: a cushion may be added behind the head of the bone to give it support, and at least to prevent the increase of the malady.

CHAPTER VI.

ON FRACTURES OF THE KNEE.

SECTION I.—FRACTURES OF THE PATELLA.

I SHALL now, pursuing my former plan, describe the fractures to which the bones entering into the composition of the knee-joint are liable; and, first, the fractures of the patella; merely premising that the patella is not covered like other bones by common periosteum, but by the ligamentous fibres of the extensors of the knee.

This bone is generally broken transversely; sometimes, though rarely, longitudinally: it is liable also to simple and compound fracture; but, fortunately, the latter is but of rare occurrence.

TRANSVERSE FRACTURE.—When the patella is transversely broken, the upper fragment is drawn up the thigh by the rectus, vasti, and cruralis muscles; whilst the lower portion is still retained in its natural situation by the ligament which passes from it to the tubercle of the tibia.

The degree of separation, thus produced, depends on the extent of laceration of the ligamentous investment of the bone; for, when the ligament is but little torn, the separation may be only half an inch; but under greater extent of injury the bone may be drawn five inches upwards; the capsular ligament and tendinous aponeurosis covering it being then greatly lacerated; and this, with one exception, is the greatest extent of separation which I have seen.

SYMPTOMS.—The accident may be at once known by the depression between the two portions of bone; by the fingers passing readily down to the condyles of the os femoris, into the joint as far as the integuments will permit; and by the elevated portion of bone moving readily on the lower and fore part of the thigh. The power of extending the limb is lost immediately after the accident, and likewise that of supporting the weight of the body on that leg, if the person be standing; for the knee bends forwards from the loss of action in the extensor muscles. The pain

of this accident is not very severe, and a simple fracture is not dangerous.

In a few hours after the accident, a copious extravasation of blood takes place upon the fore part of the joint, so that the appearance is livid from ecchymosis; but this is removed by absorption in a few days. Considerable inflammation and fever succeed, and there is a great degree of swelling on the fore part of the joint, both from the free secretion of synovia, and from inflammatory effusion around the joint. No crepitus is felt in this fracture, for the bones cannot be sufficiently approximated to produce this general discriminating mark of other fractures.

The separation of the bones is much increased by bending the knee, as this act removes the lower from the upper portion of bone.

Causes.—This accident arises from two causes: first, from blows upon the bone produced by falls upon the knee, or received upon the patella in the erect position of the body; and, secondly, from the action of the extensor muscles upon the bone.

Case CXXVIII.—A gentleman walking in the country, and not used to jumping, leaped a ditch of considerable breadth; and when he reached the opposite bank, being in danger of falling, he ran forward several steps, and with difficulty recovered himself; in this attempt to save himself from a fall, he felt the patella snap. I was sent for to him, and found his patella broken, and the portions of bone considerably separated.

Case CXXIX.—A lady, descending some stairs, placed her heel near the edge of one of the stairs, and was in danger of falling forwards, when, throwing her body somewhat backwards to prevent the fall and to straighten the knee, the patella snapped asunder.

That a bone should thus break by the action of muscles appears at first sight incomprehensible, but the circumstance is easily explained. When the knee is bent, the patella is drawn down on the end of the condyles of the os femoris, so as to bring the upper edge of the bone forwards; and at that moment it is that the patella is broken, by the rectus muscle acting not in a line with the bone, but at right angles with it, or nearly so, and upon its upper edge more particularly.

Mode of union.—With respect to the union of this bone, whether the separation be great or inconsiderable, it is generally effected by an intervening ligamentous substance. The bone

itself undergoes but little alteration; the lower portion has its broken cancellated structure still apparent, although a little smoothed. The upper portion has its broken cancelli covered by a slight ossific deposit, so that there is more ossific action in the upper than in the lower portion of the bone, but certainly much less than in bones which do not form a part of joints. The internal articular surface of the bone preserves its natural smoothness. Blood is immediately deposited in the place of the injured ligament, but this in a few days is absorbed. Adhesive lymph is then poured out, which extends from one edge of the lacerated ligament to the other, and even between the bones, to each of which it is firmly united. Vessels shoot from the edges of the ligament and render the new substance organized, producing a ligamentous structure similar to that from which the vessels shoot; this substance is not, however, always perfect, for I have seen apertures in it; but this will greatly depend upon the extent of the laceration of the ligament, and the too early use of the limb. In the dog and in the rabbit, or almost any other quadruped, it is possible by experiment to trace the mode of union of this bone.

Experiment I.—I drew the integuments much aside in a rabbit, and dividing them, placed a knife upon the patella and struck it lightly with a mallet; the bone was broken and directly drawn up by the action of the muscles. I let the integuments go, and the wound was not opposite to the fracture. In forty-eight hours I killed the animal and examined the part; the bones were separated three quarters of an inch, and the intervening part filled with coagulated blood.

Experiment II.—I repeated the former experiment, and having killed the animal on the eighth day, found most of the blood absorbed, and adhesive matter occupying the space between the bones.

Experiment III.—The former experiment repeated. The animal examined on the fifteenth day. The adhesive matter had acquired a smooth and somewhat ligamentous character.

Experiment IV.—The same division of the bone being made, it was examined on the twenty-second day, when the new ligament was complete.

Experiment V.—The same repeated, and the examination made in five weeks. The part was injected, and vessels were found proceeding from the edge of the ligament into the adhesive matter, now become ligamentous. So that at the end of five weeks the vascularity is complete, and some vessels proceed into the new ligament from the bone, but chiefly from the lacerated ligament. Upon the dog these processes may be equally well observed, but they are not quite so rapidly produced in a large dog as in the rabbit.

The parts were dissected and preserved after these experiments, both in the dog and rabbit, and they are deposited in the collection of St. Thomas's Hospital, where they may be always seen.

Experiment VI.—In the rabbit, having divided the bone, I sewed the two portions by conveying a needle and thread through the tendinous covering of the bone, but the ligatures separated, and the bones still united by ligament.

Experiment VII.—I divided the bone, and cut the rectus muscle across above it, yet the patella united by ligament.

I could not, either in the dog or rabbit, succeed in producing a bony union in the transverse fracture. Yet in a patient of my kind friend, M. Chopart, at Paris, I once saw a case which appeared to me to be united by bone; and Mr. Fielding, of Hull, has published a similar case.

The ligamentous union of the transverse fracture of the patella is that which generally occurs; and if there be an exception it is very rare. But still the principle which is to guide the surgeon's conduct is, to make that ligament as short as possible. If the ligament be of great length there is a proportionate weakness; for as soon as the accident has happened, the rectus muscle retracts and draws up the superior portion of the patella; and in proportion to the retraction suffered to remain, is the degree of shortening of the muscle, and consequently the diminution of its power. Those, therefore, in whom the bones have united

after being widely separated, if they walk quickly, do so with a halt, and are very liable to fall, and to break the other patella. Let then the muscle be brought as nearly as it can be to its natural length; and although complete apposition of the bone be very rarely effected, yet the ligamentous union is rendered as short as circumstances will permit, and the patient will recover the power of the limb.

The notion which was formerly entertained of the danger of squeezing the callus into a projection in the inner side of the bone, so as to destroy the smoothness of its internal surface, is not at all tenable. There is no callus to squeeze.

Treatment.—When called to this accident, the surgeon places the patient in bed upon a mattress, and extends the limb upon a well padded splint placed behind the thigh and leg, to which it is tied, and which should be hollowed. The patient's body should be raised as much as he can bear to the sitting posture, to relax the rectus muscle. An evaporating lotion is to be then applied upon the knee, consisting of five ounces of Goulard's lotion, with one of spirits of wine; and no bandage should be at first employed. The heel may be raised a little, and but little; for if much raised the posture is painfully constrained. If in a day or two there be much tension or ecchymosis, leeches should be applied, and the lotion be continued; when, after a few days, the tension has subsided, then, and not till then, should bandages be employed. I have seen the greatest suffering and swelling produced by the early application of bandages in these cases, even so as to threaten sloughing of the skin when there had been much contusion. The means which are most frequently employed in the treatment of this case are as follow:—A roller is applied from the foot to the knee, to prevent the swelling of the leg, and the upper portion of bone is pressed downwards, as far as it can be without violence towards the lower, so as to lessen the retraction of the muscles, and produce the approximation of the portions of bone. Then rollers are applied above and below the joint, confining a piece of

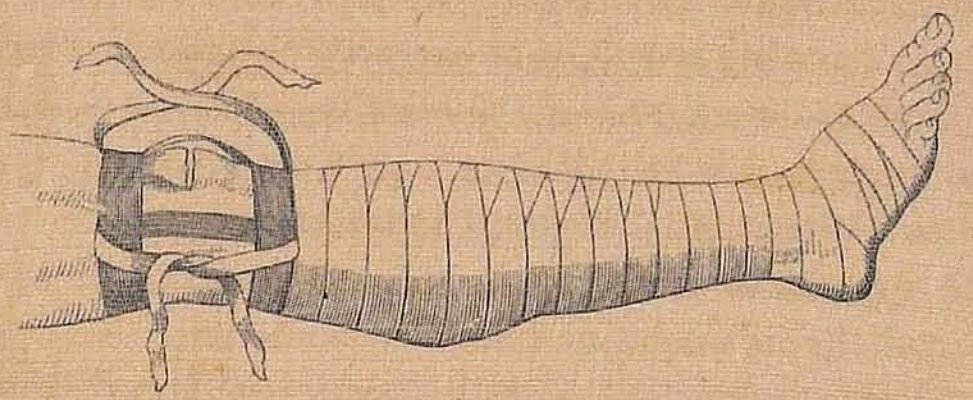

broad tape next the skin on each side, which crosses the rollers at right angles; these portions of tape are bent down and tied over the rollers so as to bring them near each other, and thus to keep down the upper portion of bone. Sometimes, instead of the tape on each side, a broad piece of linen is bent over the rollers on the fore part of the joint, and is there confined, so as to approximate the pieces of bone, and to bind down the upper portion of the patella, that its lower broken edge may not turn forwards.

Another mode is as follows:—A leathern strap may be buckled around the thigh, above the broken and elevated portion of bone; and from this circular piece of leather another strap should be passed under the middle of the foot, the leg being extended, and the foot raised as much as possible. This strap is brought upon each side of the tibia and patella, and buckled to that which is

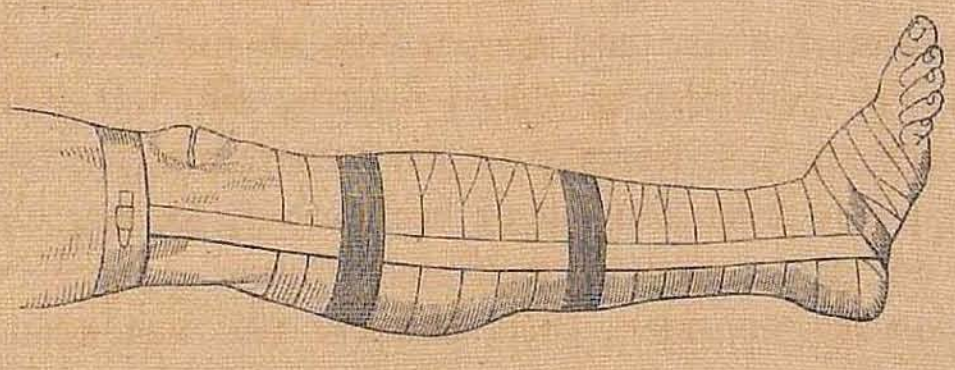

fixed around the lower part of the thigh. The strap may be confined to the foot by a tape tied to it, and to the leg at any part in the same manner; this is the most convenient bandage for the fractured patella, and for the patella dislocated upwards by the laceration of its ligament. A roller is to be applied upon the leg.*

In this position, and thus confined, the limb is to be kept for

* A very ingenious instrument has been invented by Mr. Lonsdale for keeping the portions of a fractured patella in close contact. It produces no circular constriction of the limb.—*Ed.* Vide a Treatise on Fractures, by E. Lonsdale, Lond. 1838.

five weeks in the adult, and for six weeks at a more advanced age. Then a slight passive motion is to be begun, and this must be done gently, and with so much caution that the ligament, if not firmly united, shall not give way, and suffer the bones to recede. If the union be found sufficiently firm to bear it, the passive motion is to be employed, from day to day, until the flexion of the limb be complete.

If passive motion be not used it appears that the action of the extensor muscles would never return; for those who are kept in bed, with the joint at rest, do not in many months acquire any power of bending and extending the limb. When passive motion is to be used the patient is placed on a high seat, and directed to swing the leg, by which motion is given to the rectus; and if the mind be then directed to the contraction of that muscle, its powers will be gradually renewed. When the rectus muscle has been shortened, and the upper portion of bone is drawn from the lower, all the disposition to action in that muscle ceases; and it does not seem disposed to recover its voluntary action until it becomes again elongated, which effect takes place after the union of the ligament by bending the knee; and from this point of elongation the muscle begins to contract.

Case CXXX.—A young woman was brought into my house in her father's arms, and he said, "I am obliged to carry her, for she has lost the use of her legs, having broken both her knee-pans eight months ago, and she has never been able to use her limbs since." Passive motion was directed, and she was ordered to try to extend her legs after they had been bent by the surgeon. At first she could effect but little: however, by repeated trials, she gradually recovered the use of her limbs. Mr. John Hunter, who raised surgery into a science, and who seems to have been the first who attended to the principles on which the practice of surgery ought to be regulated, always dwelt most ably upon this subject in his lectures. Patients, from the pain which passive motion produces, and the slow return of action in the muscles, are indisposed to suffer the one or to make trials of the other; but without them there can be no recovery.

The degree of approximation of the bone is, as I have stated, a matter of great consequence. The bone is rarely brought into contact so as to be united in the transverse fracture by ossific union, but the less the distance between the bones the greater

is the power which the muscle re-acquires; for in proportion as the muscle is shortened it is weakened; and in ascending there is difficulty in raising the limb,—in descending it is difficult to keep it extended; the uniting ligament is liable to be torn, and the other patella to be broken by falls; therefore the surgeon should bring the bones as near together as he can, to render the ligamentous union as short as possible, and consequently to leave the muscle with as much of its original power as the nature of the accident will permit.

Case CXXXI.—In February of the present year (1841), I received a letter from a baker at Reading, informing me that his left patella had been broken in 1838, and had united by a ligament three inches in length, and that the weakness of the limb was so great that he was almost unable to pursue his occupation. He complained also that when he wore a knee-cap, it got between the separated portions, and prevented his walking.

Sir William Blizard asserts from long experience that attention to position and to the reduction of inflammation is all that is required in the treatment of fracture of the patella, and that bandages are not only useless but pernicious.

The following case, on which I was consulted by Mr. Okes of Cambridge, in the year 1830, exemplifies one difficulty that sometimes attends the treatment of these accidents.

Case CXXXII.—Mr. W. some weeks ago, fractured the patella; and the portion attached to the rectus was so small that with all the pressure I dared to use for keeping it in conjunction with the lower portion, I was unable to bring it near enough for a bony union. The difficulty was much increased by a lacerated wound laying bare the tendinous expansion of the vastus internus. Soon after he began to use his knee he was thrown down, and the two portions again separated. I hoped this opportunity might serve to effect a better junction; but, as you will see, it has been unavailing; it was not difficult to bring the portions together, but the upper one is so small as to slip up underneath the bandage.

Perpendicular Fracture of the Patella.—We have in the collection at St. Thomas's Hospital a patella, one fourth of which has been broken off; the edge is smooth, and no attempt at ossific union appears to have been made.

A gentleman consulted me who had about one third of the

patella separated from the other part of the bone; it had united by ligament, for there was free motion between the fractured piece of bone and that from which it had been removed. He recovered quickly from this injury, and it affected his power of walking very little.

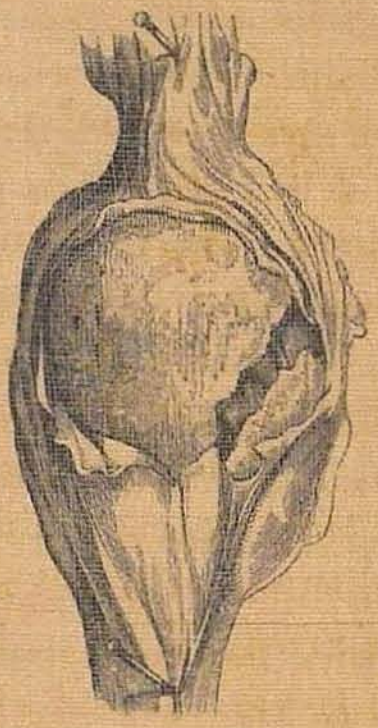

During the winter of 1822, a body was dissected at St. Thomas's Hospital, in which both the patellæ had been broken longitudinally, and although they were in contact, they were both united by ligament. Mr. Silvester, one of our pupils, had the kindness to make a drawing of one of these, of which I have given a plate.

This circumstance surprised me, because I saw no reason why the patella should not be united by bone when broken perpendicularly, as I thought the muscles would have a tendency to bring the parts together. I made it, therefore, a subject of experiment.

Experiment I.—July 31st, 1818, I broke the patella of a dog by placing a knife upon it in the longitudinal direction, having first drawn the integuments aside; and on the 12th of September following I examined the part, when I found the two portions of bone considerably separated from each other, and united by ligament. The cause was as follows:—When I had divided the bone, the knee became bent, the condyles of the os femoris pressed against the inner side of the patella, and thrust the parts asunder, and only a ligamentous union took place.

Experiment II. — August 2nd, 1818, I broke in the same manner the patella of a rabbit, and examined the parts on September 3rd, when I found the two portions of bone widely separated, and united only by ligamentous matter. I now began to think it

impossible for the patella to unite by bone, but determined to make another experiment to determine this point.

Experiment III.—I divided the patella longitudinally in a dog, but took care that the division should not extend into the tendon above or to the ligament below it, so that there should be no separation of the two portions. I examined it three weeks after, and found it united, no separation existing between the two portions. The union was partly by bone, partly by cartilage.

Experiment IV. — October, 1819. I divided the patella by a crucial fracture into four portions; the two upper portions neither united with each other, nor with the bones below, but the two lower portions became united by bone.

It appears, then, that under longitudinal and transverse fracture, a ligamentous union is generally produced, and that it arises from the separation produced in the bone; but that if they cannot separate, and their parts remain in contact, ossific union may be produced.

Case CXXXIII.—In the summer of 1819, Mr. Marryat was thrown from his gig as he was passing along the Strand: by the fall he fractured his patella transversely, and the lower portion of the bone was also broken perpendicularly, so that it was divided into three pieces. The transverse fracture united, as usual, by ligament, but the perpendicular by bone; and Mr. Parrott, of Tooting, tells me that the latter became very firmly consolidated, with a line or ridge to be traced upon the surface of the bone, which marks distinctly the place where it had been separated.

Treatment.—In the longitudinal or perpendicular fracture of the patella, the best treatment consists in extending the leg, and in using local depletion and evaporating lotions. When inflammation has subsided, a roller should be applied around the limb, and then a laced knee-cap, with a strap to buckle around the knee above and below the patella, and a pad on each side to bring its parts as nearly as possible into contact.

Compound Fracture of the Patella. — These fractures occur from injury, or from an ulcerative process under peculiar circumstances.

The cases which I have seen of this accident are as follow:—

Case CXXXIV.—A man was admitted into Guy's Hospital in the year 1796, under Mr. W. Cooper, surgeon of that hospital, with a compound fracture of this bone; violent inflammation followed; suppuration ensued, with the highest degree of constitutional irritation; and as no opportunity was given for amputation, from the great swelling of the thigh, this man died. The bone is in the Museum of St. Thomas's Hospital, disunited as at the first moment of the accident.

Case CXXXV. — A man was admitted into St. Thomas's Hospital, under the care of Mr. Birch, with a fracture of the patella, and a small wound extending into the joint. The knee was fomented and poulticed; inflammation and suppuration followed; and this man in a few days died with the highest symptoms of constitutional irritation.

Case CXXXVI.—Mr. Hawker, surgeon, called me to visit a man who had just arrived in London, who, being at work in a warehouse up one pair of stairs, on hearing the signal for dinner, seeing the doors of the warehouse open, walked quickly out, and fell into the street. By this fall he had a compound fracture of the patella. The limb was attempted to be saved. The joint suppurated; the discharge became excessively great, and the symptoms of irritation ran so high, that I thought he would not recover; but he became somewhat better, and I advised him to go into the country. I afterwards heard that he gradually recovered with an anchylosed joint.

Case CXXXVII. — Mr. R., aged thirty-nine years, was thrown from his gig, on June 18th, 1819, against a cart-wheel. His knee came violently in contact with the wheel, which fractured his patella and opened the joint. Mr. Dixon, of Newington Butts, was sent for, and he found that the knee had bled freely from a wound on its outer side, from which the synovia freely escaped, and which readily admitted his finger to the shattered patella. The accident happened at ten o'clock in the morning: I was sent for by Mr. Dixon, and when I met him at four o'clock, I found a wound on the fore part of the knee, through which I readily passed my finger into the joint. The

patella was not broken transversely, but, as I have expressed it, shattered, that is, broken into several pieces; and a small piece which was separated from the rest I removed. It was agreed between Mr. Dixon and myself that an attempt should be made to save the limb, for the patient was of a spare habit, and, from his great composure, showed that he was not of an irritable constitution. I passed a suture through the integuments, knowing the difficulty of keeping the wound closed on account of the continued escape of synovia, but taking the utmost care that the ligament should not be included in the suture. Adhesive plaster was also applied over the wound, and rollers lightly put on, which were kept constantly wet with spirits of wine and water. The leg was placed in the extended position, and he was ordered not to move it in the slightest degree, and to live on fruit.

Saturday.—He had passed a very good night, and was free from pain or fever.

The next day he was restless, and was thought delirious; but on Monday morning he was relieved by a dose of castor oil, and he afterwards had no bad symptoms. As there was no swelling, no inflammation, and scarcely any pain, the suture was not removed until the 30th of June, when the adhesive plaster was renewed.

He recovered without any untoward accident. Mr. Dixon ordered him from bed in a month, and at the end of five weeks gave the joint slight passive motion. On the 7th of August, the patient walked across his room; and he entirely recovered the use of his limb.

Case CXXXVIII.—Capt. O. of the 1st Dragoons, in riding very fast at night on the 15th July 1834, was run against by a cart, and struck his patella against the wheel, which produced a compound fracture of his right patella. Capt. O. was very much shaken from the concussion, and thrown with his horse upon the ground. He was seen immediately by Mr. Laurence of Brighton, and afterwards by Sir. A. Cooper and Mr. Vance. They directed that the leg should be kept perfectly quiet, applied a piece of lint dipped in blood, and kept it in its situation by adhesive plaster; the foot and leg were placed in an elevated posture.

A month after the accident the bandages were removed, when it was found that the wound had nearly healed; and then adhesive

plaster was applied as a bandage to keep the divided portion as much as possible together: Capt. O. remained upon his bed for four weeks and two days. For a month after his rising from the bed he went upon crutches, and he now walks with a stick. He has a tolerable motion of the joint, and the fractured portions of bone can be distinctly felt. He says he suffered very little pain, but had an occasional spasm of the muscles.

[The Editor is glad to be able to add that Capt. O. has now a perfectly useful limb.]

CASE CXXXIX.—Cornelius Michael Kelly, aged forty, a healthy-looking man, and of temperate habits, by occupation a labourer, whilst working at a wharf, fell with his leg bent under him upon some pig-iron, his whole weight being upon the knee. He was immediately brought to Guy's Hospital. When admitted he did not appear at all collapsed, as might have been expected from the severe nature of the injury. There was a laceration over the knee; the patella was fractured and comminuted, and synovia was escaping. The whole force seemed to have been concentrated upon the patella, as there was a depression in its centre, from which the fractured pieces appeared to diverge. The limb was placed upon a back splint extending from the tuber ischii to the heel, and thirty leeches were immediately applied. Mr. Cooper saw the case about two hours afterwards, and twenty more leeches were ordered, with three grains of Dover's powder and of hydrargyrum cum creta every four hours, and an aperient.

A pad of lint was placed over the wound, and the limb was bandaged above and below the knee.

May 12th. Thirty more leeches were ordered. He complains of great pain in the knee; his constitution appears to sympathise with the injury, his skin being hot, tongue furred, and pulse somewhat accelerated. The man to be kept quiet, and to have saline mixture and low diet.

May 13th. Still complains of great pain in the knee. Thirty more leeches to be put on, and whitewash to be applied above and below the knee.

May 14th. The pain still continues great, though not so severe as yesterday. Twenty leeches to be applied, and the other remedies to be continued.

May 15th. The pain has now considerably decreased. A poultice was ordered to be applied over the knee.

May 18th. Still going on well. The man not at all irritable, but keeps the limb perfectly at rest.

From this time the case continued to proceed favourably, no bad symptom occurring; and the patient was discharged perfectly cured on June 27th.

The following very fortunate case was forwarded to the Editor by Mr. Ward of Nottingham, and was published in the fifth volume of the Guy's Hospital Reports.

Case CXL.—"On the evening of the 2nd November 1838, I was called," says Mr. Ward, "to attend Mr. E. M., residing six miles from Huntingdon, who, on his return from shooting, had received a gun-shot wound of the right knee, in attempting to force his dog from its kennel with the butt-end of a loaded gun.

"When I arrived at his residence I found that he had been removed to bed, with the assistance of my friend Mr. Abbott, surgeon, of Cambridge, who fortunately happened to arrive in the village a few minutes after the accident occurred, and whose long experience and well known professional talents rendered his opinion and advice extremely valuable in the treatment of this remarkable case.

"The contents of the gun had struck the patella on the outside of the knee, carrying away the whole of that bone, except a small, solid, triangular portion, which still remained attached to the ligament; there was a nearly circular wound of the integuments, completely exposing the joint, and sufficiently large to admit my whole hand into the joint between the tibia and femur; but the cartilages of those bones appeared uninjured. The propriety of immediate amputation was the first subject that suggested itself. Upon mature deliberation, however, we resolved to attempt to save the limb, for the following reasons:—first, because the exposed bones, both femur and tibia, with their cartilages, were uninjured; secondly, because the soft parts around the wound, not being lacerated or contused, rendered it less probable that extensive sloughing would take place; thirdly, because our patient was young, of good constitution, and temperate habits; and having recently recovered from a serious wound of the thumb, from the bursting of his gun early in September, the judicious dietetic treatment enjoined by the surgeon who attended him on that occasion, which had been continued to the present time, had brought him into

the most favourable condition for sustaining the ill effects likely to arise from so formidable an injury.

"The patient was placed on his back, with the knee slightly flexed; a large poultice applied to the wound, and a full dose of opium given. He passed a quiet night, and in the morning I found him in good spirits, with a quiet and regular pulse, and with merely a slight aching in the knee. No unfavourable symptoms, either local or constitutional, occurred during the progress of the case, nor was his pulse even in any degree accelerated. An anodyne at bed-time for a few nights, and occasional aperients, were the only medicines required. Poultices were continued until granulations began to arise; after which (the remaining small portion of patella having been removed,) the surface was dressed with lint dipped in oil, and strips of adhesive plaster were applied in various directions to assist in approximating the edges of the wound. On the 21st of January, 1839, the wound being quite healed, Mr. M. was able to dress himself and sit up in a chair. In a short time, with the aid of a suitable splint and bandage, he went upon crutches; and in the middle of March he came to my house, six miles, on horseback.

"He has continued well to the present time, and has long discontinued wearing a splint or any application to the knee. The cicatrix is very firm, and there is considerable motion of the joint; so that Mr. M. can not only walk very well without a stick, and even run without much inconvenience, but in November last I saw him dancing quadrilles at a ball in this town."

The foregoing remarkable case is not altogether uninstructive: first, as it seems to show to how great an extent we may trust to nature's efforts when assisted by a sound constitution and healthy temperament; and, secondly, as it tends to confirm the observation of writers on surgery, that large wounds of joints are not so commonly followed by severe constitutional disturbance as small or punctured wounds.

The foregoing most interesting case leads the Editor to observe, that there is no class of injuries or diseases more important, none in which we may anticipate a greater improvement in the treatment, than those which occur to joints. No longer does it seem to be considered a necessary consequence that the limb should be sacrificed, either in case of a large joint being

exposed by accident or destroyed by disease. Extensive wounds into synovial membranes are now left to the restorative powers of nature, and the excision of the diseased articulating surfaces of a joint is substituted for amputation,—improvements which may be considered of the greatest importance in the science of surgery.

Recent experience appears to encourage the expectation that after an articulation has been laid open by violence, nature, aided by judicious treatment, may speedily produce such an alteration in its conditions as shall prevent, or at any rate diminish, that excessive and almost fatal degree of constitutional irritation which has generally been considered the inevitable consequence of such lesions.

In the case of extensive wounds into joints, nature does not seem to attempt to close the synovial capsule by adhesive inflammation, and thus reconvert it into a closed secreting membrane; but a granulating surface shuts up the wound into the articulations, and the joints are soon placed in a very similar condition to one which, after having been the subject of a violent inflammatory action from disease, is progressing towards a favourable termination.

In punctured wounds the same action does not seem to follow; but the synovia continues to be secreted, oozes from the wound, intercepts nature's efforts at reparation, and induces a high degree of inflammatory action, which frequently leads to suppuration and death. In the latter cases also there is not the same degree of prostration as where an extensive wound lays open a large joint, which accident is generally followed by faintness, almost approaching to collapse; a condition most favourable, and likely to prevent subsequent high inflammatory action, by allowing the membrane, when in a passive state, to be submitted to the influence of external, apparently noxious, agents.

The high degree of constitutional irritation which follows the infliction of a small punctured wound into any joint may also, in some measure, be attributable to the absence of that alarm which is created by a large wound; so that the same precautionary measures, rest, and remedies, are not had recourse to. This supposition seems verified by the fact of the operation for the removal of loose cartilages from the synovial membranes

being safely performed by skilful surgeons;—skilful, I mean, not only in the manipulation employed for the removal of the extraneous substance, but also in the judicious preparation of his patient.

If the laceration be extensive, or the contusion very considerable in these cases, amputation will be required; but if the wound be small, and the patient be not irritable, and no sloughing of the integuments or ligament be likely to occur from the nature of the accident, it will be best to try to save the limb; and the treatment of Mr. R.'s case (CXXXVII.) is that which I should pursue. The principal object is to produce adhesion immediately; and every means in our power must be used for that purpose. I know well that sutures are generally objectionable, and I never employ them if I can possibly succeed without them; but in movable parts, in those which are unsupported, and in those through which a secretion is liable to force its way, they are not only justifiable, but highly necessary. Fomentations and poultices must not be employed in these cases, as they prevent the adhesive process.

A compound fracture of the patella, if it may be so called, may sometimes be produced by an ulcer, as in the following case.

Case CXLI.—A woman was admitted into Guy's Hospital, in 1816, with a simple and transverse fracture of the patella, which had long been united by a ligament of about three inches in extent. Ulcers were formed upon different parts of the body, and, unfortunately, one of these upon the integuments over the ligamentous union of the patella. It became sloughy, and extended through the new ligament to the joint, which it laid open: violent constitutional irritation succeeded; a copious suppuration was produced, and no opportunity was given of amputating the limb, for the inflamed and swollen state of the thigh forbade it. This woman died.

SECTION II.

OBLIQUE FRACTURES OF THE CONDYLES OF THE OS FEMORIS INTO THE JOINT.

These cases are of rare occurrence; but when they happen it is difficult to prevent deformity, and to restore to the patient a

sound and useful limb. They are known by the great swelling of the joint with which they are accompanied, by the crepitus which is felt in moving the joint, and by the deformity with which they are attended. The fracture is sometimes of the inner, and sometimes of the outer condyle, and the bone is split down into the joint.

TREATMENT. — Whether the external or internal condyle be broken, the same treatment is required. The limb is to be placed upon a pillow in the straight position, and evaporating lotions and leeches are to be used to subdue the swelling and inflammation. When this object has been effected, a roller is to be applied around the knee, and a piece of stiff pasteboard about sixteen inches long, and sufficiently wide to extend entirely under the joint, and to pass on each side of it, so as to reach to the edge of the patella, is to be dipped in warm water, applied under the knee, and confined by a roller. When this is dry, it will have exactly adapted itself to the form of the joint, and this form it will afterwards retain, so as best to confine the bones.* Splints of wood may be used on each side of the joint, but they are apt to cause uneasy pressure. In five weeks, passive motion of the limb may be gently begun, to prevent anchylosis. I prefer the straight position in these cases, because the tibia presses the extremity of the broken condyle into a line with that which is not injured.

COMPOUND FRACTURE. — Examples of compound fractures of the condyles are very unfrequent: the following was under the care of Mr. Travers, in St. Thomas's Hospital, who was so kind as to send me the history of it.

CASE CXLII.—Michael Dixon was admitted into St. Thomas's Hospital, September 17th, 1816, for a fracture of the lower extremity of the femur, caused by a carriage-wheel in motion, with which his legs became entangled. There was much displacement of the fractured bone, and a small wound opposite the external condyle. Upon examination it was evident that the fracture had extended nearly in the direction of the axis of the bone, and there was a transverse fracture of the shaft of the bone above the joint; the external condyle was movable, and thrown out of its place during the accident, as if it had been drawn by

* The starched bandage is an excellent substitute. In bandaging the knee, the patella should be exempt from much pressure.—*Ed.*

the leg, which was twisted inwards. The limb was laid in a fracture-box, in a semi-flexed position on the heel; the constitutional disturbance was very slight.

Oct. 5. The external condyle is still movable: the integuments over it are ulcerated, so as to denude the bone. The health remains good.

Nov. 5. The broken bone protrudes, and appears to be dead; it is surrounded by fungous granulations, and there is but little discharge.

Nov. 18. The protruded bone having been gently twisted off by forceps, proved to be the external condyle, with its articular surface: there still protruded a small portion of bone, but this soon healed over. The limb was now placed in an extended position, as anchylosis was considered unavoidable.

Dec. 6. The boy was discharged from the hospital. The wound was healed, and he could walk tolerably well with a stick.

On the February following he called at the hospital, walking without any support, and having free use of the joint.

In aged persons these accidents sometimes prove destructive to life, of which the following is an example; and, indeed, I have known a simple fracture of the condyles produce the same effect.

Case CXLIII. — Mr. Blukwick, aged seventy-six, on the 1st of January 1822, slipped accidentally off the curb-stone, and received the whole weight of the body upon the knee. The patella appears to have acted as a wedge between the two condyles of the os femoris, which were separated by a fracture, running obliquely along the shaft of the bone, the end of which was forced through a wound in the integuments. The patella remained in its place, and was unbroken. The patient at the time of the accident was in a state of inebriation. Mr. Rowe, of Burton Crescent, to whom I am indebted for the particulars of the case, saw him about three hours after the accident: he had him conveyed to bed, and without much difficulty brought the fractured bones in apposition; they were retained in their situation by splints and bandages, and the limb was placed in the straight position. A lotion of the liquor plumbi was applied over the part, and an opiate was administered at night.

The patient passed a tolerably quiet night, and in the morning was pretty free from pain. An aperient draught was administered, which operated freely. On the evening of this day I

was called in to him. I directed a leathern cap to be strapped over the fractured part, and the straight position of the limb to be preserved. The patient was ordered a regular diet, and saline draughts, with an occasional opiate.

This treatment was continued until the twenty-first day from the accident, and the patient remained free from any bad symptom. On the evening of that day, however, he was found much heated, with a very frequent pulse, dry tongue, and a tendency to delirium: these alarming symptoms, it appears, were increased by a glass of brandy and water taken contrary to the direction of his medical attendant. Mr. Rowe ordered him an aperient, but the danger was rapidly increasing: the patient was found next morning in a high degree of fever; pulse one hundred and thirty; countenance exhibiting great depression. These unfavourable symptoms went on increasing, and on the twenty-fourth he died.

The limb, on examination after death, exhibited great signs of inflammation; a considerable quantity of matter was found between the muscles of the thigh, part of which was discharged by the external wound.

Upon examining the thigh-bone it was found that its shaft was broken very obliquely, about seven inches above the knee-joint; and that the bone was split down into the joint, near to the centre, between the condyles, but inclining somewhat to the external condyle; which portion of the bone was loose and detached from the internal condyle: there was also a piece three inches in extent, detached from the shaft of the bone, but which had fallen into the cancelli, where it remained lodged.

SECTION III.

OBLIQUE FRACTURE OF THE OS FEMORIS JUST ABOVE ITS CONDYLES.

This is a most formidable injury from its consequences on the future form and use of the limb; for it is liable to terminate most unfortunately, by producing deformity, and by preventing the flexion of the knee-joint.

It is only of late years that I have had an opportunity of investigating this case by dissection; and, consequently, of obtaining substantial knowledge of the exact nature of the injury. The appearances produced by it are, that the lower and broken extremity of the shaft of the bone projects, and forms a sharp point just above the patella, which pierces the rectus muscle, and threatens to tear the skin, and sometimes does so: whilst the patella, tibia, and condyles of the os femoris sink into the ham, and are drawn upwards behind the broken extremity of the shaft of the os femoris.

The accident happens when a person falls from a considerable height upon his feet, or is thrown upon the condyles of the os femoris with the knee bent. In all the cases the fracture was very oblique through the shaft of the bone; and hence the pointed appearance of the extremity of the fracture, and the difficulty of keeping the bones in apposition.

Case CXLIV. — A body was brought into the dissecting-room at St. Thomas's Hospital, which fell to the lot of Mr. Patey, surgeon, of Dorset-street, Portman-square, to dissect, and he kindly permitted me to make a drawing from the limb. It appeared, upon view of the thigh, that the limb had been broken just above the knee-joint, and that the shaft of the bone projected as far as the skin, just above the patella: the union was firm, but the magnitude of the bone was exceedingly increased. When the integuments were removed, the end of the superior portion of the shaft of the bone was found to have pierced the rectus muscle, through which it still continued to project; and behind this projecting portion of bone the rectus muscle was situated, which passed to the patella. The patella, on the

attempt to draw it up, was stopped by the projection of the fracture, so that its movement upwards was exceedingly limited. The condyles of the os femoris, and the lower portion of the bone, had been drawn by the action of the muscles behind the end of the fracture of the upper portion, and had united by a very firm callus to the body of the bone.

This union had necessarily produced a great diminution in the power of extending the limb; for the rectus muscle was really hooked down by the fractured extremity of the bone: but even if the bone had not pierced the muscle, still the elevation of the patella would have been prevented, by its being drawn against the fractured end of the thigh-bone in the contraction of the muscle. It appears, then, in the treatment of this case, that a most firm and continued extension must be supported to prevent the retraction which will otherwise ensue; but it will be seen by the two following cases, that this defective union is with great difficulty prevented; and that the complete flexion of the limb afterwards was not in either instance accomplished.

For the next case I am indebted to Mr. Welbank, jun., who attended it with me.

Case CXLV. — Mr. ——, of middle age, muscular and tall, was driving on the morning of July 20th, 1821, in the neighbourhood of Leicester-fields, and was thrown forward out of his gig, over the horse, which had fallen. It is probable that the external condyle of the right femur received the force and weight of the descent upon the pavement. He was brought from Leicester-fields to Chancery-lane in a coach, with his legs out of the door, no surgical assistance having been yet procured. When first seen by his surgical attendant he was lying upon his

back on the bed, with the right leg bent and lying across the middle of the left leg at an angle. There was an appearance resembling the lateral dislocation of the knee, from a deep hollow, visible on the external side of the joint, in the situation of the external condyles; above this hollow, close to the joint, and on its external or fibular side, an abrupt and sharp projection of bone was distinctly observable. Slight extension replaced the parts, and it now appeared that the thigh had, previously to the reduction, been bent inwards over the left, upon an oblique fracture, situated close to the patella. The patella itself was very obscurely felt through a circumscribed effusion in front of the joint. Just above the situation of its upper edge might still be traced the ridge of the fracture, a slight groove intervening: the appearance, indeed, at this and later periods of the accident might have been mistaken, on superficial examination, for the transverse fracture of the patella. Flexion produced great projection of the upper part of the femur, and extension readily restored the natural appearance, except in the swelling on the front of the patella. The crepitus was very indistinct, if at all observable.

Little more was done during the first week than steadying the joint in the extended position with short splints, and subduing the inflammation of the capsule which supervened. After this period, a long splint was applied from the trochanter major to the outside of the foot, and an opposing short splint from the middle of the femur to the middle of the inside of the leg; and these were firmly confined by tapes and buckles. The whole limb was supported upon an inclined plane, and flexion cautiously obviated. To prevent motion of the pelvis the stools were removed in napkins. The posture was not, however, steadily maintained; and it was frequently found that the upper point of bone varied in its degrees of projection, and at different times, more or less, encroached on the situation of the upper edge of the patella. To remedy this, slight permanent extension, with weights appended to the foot, was adopted with advantage; though I believe that the position was by no means rigorously maintained, for I have since understood that the patient, not unfrequently, even had his back washed. The ridge of the upper portion of the femur appeared, however, to project so slightly, that it was deemed better to ensure union, than to add to the fre-

quency of disturbance, by being too solicitous of exact apposition.

About September 7th, the bone was thought sufficiently united, but flexion was neither attempted by the surgeon, nor permitted to the patient. On September 10th, the patient was removed to Eastbury, Hertfordshire, in a litter-carriage, as his health was suffering: the limb being steadied with splints, and the position resumed, during the journey. In removing from one bed to another, and in other alterations of posture, it was obvious that flexion produced a greater appearance of projection of the femur than had been anticipated. This might be referred to the drawing down, or rather sinking of the patella in flexion; and, indeed, it could to appearance be nearly remedied by elevating the leg upon the thigh, as in extension. Under these circumstances, however, rest in the extended posture was again adopted for a fortnight. About September 25th, a second examination decided the necessity for further rest, as the increase of projection, on flexion of the knee, and a slight lateral motion, induced a belief of infirm union. It is worthy of mention, that the immediate vicinity of the joint, the mobility of the patella, and the general thickening, rendered all examinations of extreme difficulty and uncertainty. A circular belt was tightly girded upon the situation of the injury, with a view of compressing the fracture, and maintaining the parts in firm apposition. October 16th, the union was considered complete, and the patient allowed to get up. On November 1st, he resumed his professional duties as an advocate. For a considerable period he suffered pain and swelling of the limb, but has gradually and slowly improved.

May, 1822.—At this date he can walk about his room without assistance either of crutch or stick. He has little power of flexion at the knee-joint. The joint is, however, apparently movable to a certain extent beneath the patella, which bone is fixed beneath the projecting edge of the upper portion of the femur, which evidently overlaps and displaces it. There is visible shortening of the limb, and the *contour* of the thigh is somewhat bowed outwards.

To obviate the evils which are produced by this formidable accident, I had an apparatus constructed to preserve the thigh in a constant state of extension, as is represented in a former

page (174). The leg is to be first bent, to draw the rectus muscle over the broken extremity of the bone, and then the apparatus is to be applied, and the limb to be preserved in a constant state of extension in the straight position.

CASE CXLVI.—Mr. Kidd, who weighed fifteen stone, fell, on the 9th of November, 1819, from the height of twenty-one feet. He alighted upon his feet, and broke his thigh-bone just above the knee by the severity of the concussion. The fracture was situated immediately above the condyles, and the broken extremity of the shaft of the bone appeared through the integuments and rectus muscle, just above the patella. He was immediately carried home, and I saw him, with Mr. Phillips, surgeon to the king's household, a short time after the accident. We agreed that the projecting extremity of the thigh-bone should be immediately sawn off, and that the edges of the wound should be approximated so as to render the fracture simple; and this was immediately done. The limb was placed upon the double inclined plane. The wound healed without difficulty, and our first object was thus accomplished. On the 30th of November, splints were applied, in order to press the bones firmly together. On December 23rd, the leg was straightened, and the inclined plane was lowered, so as to bring the limb gradually into a straight position. On February the 2nd, he sat up in bed. On the 7th of February, the knee having been moved, the fractured bones appeared to separate, and on the 14th it was clearly ascertained that the bone was not united. On the 16th, a leathern bandage, with many straps, was tightly buckled around the knee. Having previously tried the position upon his side, which only led to a greater separation of the bone, he was again placed upon his back. On the 3rd of May, the bone was found to be united, and on the 12th, the leathern bandage was removed, and the limb placed on a pillow. On the 10th of July, he moved from one side of the bed to the other with difficulty, and on the 16th, was placed on another bed, which was obliged to be adjusted to the exact level with the other before his removal could be accomplished. On July the 19th, he was removed from London to Kensington on a litter. On the 8th of August, the thigh was fomented in order to remove the excessive bulk it had acquired, and to diminish its hardness; but the fomentation was discontinued on the 14th, because it was found to increase the

swelling. On the 15th, the leg was bathed with the liquor plumbi subacetatis dilutus, and spirits of wine: the skin having been ulcerated from the time that the bandage was buckled tight around the knee. On October the 24th, the leg was placed in a gout cradle. On the 26th, he was on a sofa for two hours, but on the 28th, was obliged to keep in bed, because irritation and swelling had been produced by moving on the two preceding days. On November the 3rd, he was wheeled into another room on a chair. On January the 29th, 1822, he was, for the first time, on crutches; and on February the 24th, he first walked out of doors.

His present state, March 1822, is as follows:—The bone above the knee is excessively enlarged; the patella is fixed below the broken extremity of the shaft of the bone, the point of which adheres to the skin.

Mr. Kidd possessed a very fine constitution, for his pulse after the accident never exceeded 63; and although the rectus muscle was penetrated by the bone, he never complained of any spasmodic contraction of the limb.

SECTION IV.

FRACTURE OF THE HEAD OF THE TIBIA.

Oblique Fracture into the Joint.—The head of the tibia is sometimes obliquely broken; and if it be fractured into the knee-joint, the treatment which it requires is similar to that which is necessary in the oblique fracture of the condyle of the os femoris; that is, first, to maintain the straight position of the limb, because the femur preserves the proper adaptation of the fractured tibia by serving as a splint to its upper portion, and keeping the articular surfaces in apposition. Secondly, a roller to press one part of the broken surface against the other. Thirdly, a splint of pasteboard* to assist in the preservation of that pressure. And fourthly, early passive motion to prevent anchylosis.

Fracture Just below the Joint.—But if the fracture of

* Or the starched bandage.—*Ed.*

the tibia be oblique, yet not into the joint, then it is best to place the limb upon the double inclined plane; for the cause of deformity being the elevation of the lower portion of the tibia, which is drawn up on one side of the knee-joint, (according as the fracture is on the inner or outer side of the tibia,) the weight of the leg keeps the limb constantly extended as it hangs over the angle of the inclined plane, and thus the bone is brought into as accurate apposition as the nature of the fracture permits.

CHAPTER VII.

ON DISLOCATIONS AND FRACTURES OF THE ANKLE-JOINT.

SECTION I.—ANATOMY OF THE JOINT.

The bones which enter into the composition of the ankle-joint are the tibia, fibula, and astragalus. The tibia has an articulating surface at its lower part, which rests upon the astragalus; and there is a projection on the inner side of the lower portion of this bone, which forms the malleolus internus, and this part is articulated with the side of the astragalus. The fibula projects beyond the tibia at the outer ankle, and forms there the malleolus externus, which has also an articulating surface for the astragalus. The astragalus, which is the uppermost bone of the tarsus, rises between the malleoli and the lower part of the tibia, and moves upon it in flexion and extension of the foot.

Thus nature has strongly protected this part of the body, by the deep socket formed by the two bones of the leg, between which the ball of the astragalus is received.

Ligaments.—The lower extremity of the tibia is united to the fibula by very strong ligaments, but without any intervening articular cavity, as the ligaments proceed directly from the surface of one bone, and are received into the other.

The peculiar ligaments joining the tibia and fibula to the tarsus, consist, first, of a deltoid or triangular ligament, which arises by its apex from the internal malleolus, and expands so as to be inserted into the astragalus, os calcis, and os naviculare. Secondly, the fibula is united to the tarsus by three excessively strong external lateral ligaments; one anteriorly from the malleolus externus to the astragalus, one inferiorly to the os calcis, and the third to the astragalus posteriorly. Owing to the strong ligaments of the fibula, it is much more frequently fractured than

dislocated; and even when the tibia is dislocated at the ankle-joint, the fibula is fractured in two of the species of dislocation, and generally in all; but when the tibia has been thrown outwards, I have known the fibula escape a fracture.

Before and behind the joint the interspace between the lateral ligaments is filled up by weak ligamentous fibres, proceeding from the tibia to the astragalus, which constitute what used to be called the capsular ligament, a term now appropriated to the ball and socket joints.

Varieties of Dislocation.—I have seen the tibia dislocated at the ankle in three different directions; inwards, forwards, and outwards; and a fourth species of dislocation is said sometimes to occur, viz. backwards: the foot has also been known to be thrown upwards between the tibia and fibula, by the giving way of the ligament which unites these bones; but this accident is only an aggravated state of the dislocation inwards.

SECTION II.

SIMPLE DISLOCATION OF THE TIBIA INWARDS.

Symptoms.—This is the most frequent of the dislocations of the ankle. The tibia has its internal malleolus thrown inwards, which so forcibly projects against the integuments as to threaten their bursting. The foot is thrown outwards, and its inner edge rests upon the ground. It rotates easily on its axis. There is a considerable depression above the outer ankle, much pain in the part, and considerable swelling; the foot can easily be moved laterally, and crepitus can generally be detected at three inches above the lower extremity of the fibula.

Dissection.—Upon dissection, the internal appearances are as follow:—The end of the tibia rests upon the inner side of the astragalus, instead of resting on its upper articular surface; and if the accident has been caused by jumping from a considerable height, the lower end of the tibia, where it is connected to the fibula by ligament, is frequently split off, and remains connected with the fibula, which is also broken from two to three inches above the joint; and the broken end of the fibula is carried down

upon the astragalus, occupying the natural situation of the tibia. The malleolus externus of the fibula remains in its natural situation, with two inches of the fibula and the split portion of the tibia; the ligamentous fibres attached to the fibula at the malleolus externus, and the three strong external lateral ligaments, remain uninjured.

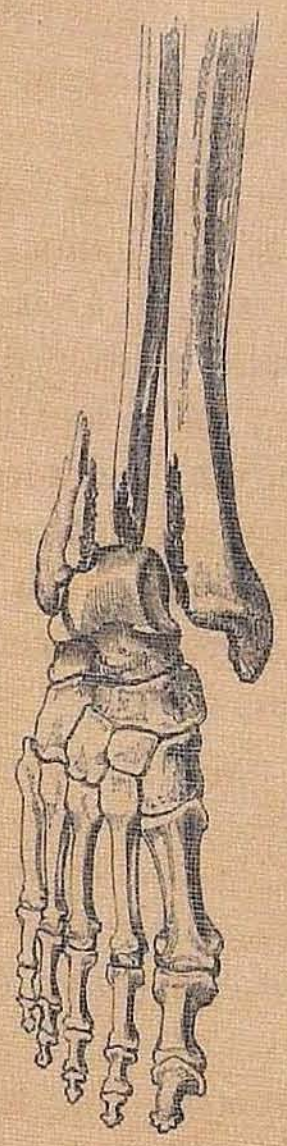

CAUSES.—This accident generally happens through jumping from a considerable height; or it may be caused if the foot is suddenly checked in its motion whilst a person is running violently with the toe turned outwards: it may also be caused by a fall to the outer side, when one foot is fixed.

To distinguish a fracture of the fibula, the hand must grasp the leg just above the ankle, and then the foot must be freely rotated; when, the motion of the foot being communicated to the fibula, pain will be felt, and a crepitus be perceived.

TREATMENT.—For the reduction of this dislocation, which cannot be too soon accomplished, the patient is to be placed upon a mattress properly prepared, and is to rest on the side on which the injury has been sustained; the surgeon is then to bend the leg at right angles with the thigh, so as to relax the gastrocnemii muscles as much as possible; and an assistant grasping the foot, must gradually draw it in a line with the leg. The surgeon then fixes the thigh and presses the tibia downwards, thus forcing it upon the articulating surface of the astragalus. Great force is required if the limb be placed in the extended position, from the resistance of the gastrocnemii; and it is pleasing to observe, after most violent attempts by others, a well-informed surgeon gently bend the limb, and, under a comparatively slight extension, return the parts to their natural situation.

When the limb has been reduced it is still to remain upon its outer side in the bent position, with the foot well supported; a many-tailed bandage is to be placed over the part to prevent it



from slipping, and this is to be kept wet with an evaporating lotion. Two splints are then to be applied; and each is to have a foot-piece, to give support to the foot, to prevent its eversion, and to preserve it at right angles with the leg. If much inflammation succeeds, leeches are to be applied, the bowels to be opened, and the constitution may possibly require relief by taking blood from the arm; but I shall say no more on this subject until I describe compound dislocation of this joint. A person who has sustained this accident may be removed from his bed in five or six weeks, long straps of plaster being passed around the joint to keep the parts together, and he may be suffered to walk on crutches; but from ten to twelve weeks will elapse before he has the perfect motion of the foot; and much friction and passive motion will be required after the eighth week to restore the natural motions of the joint.

The following case was drawn up by Mr. Bedford.

Case CXLVII.—Charles Haynes, aged fifty-seven, was admitted into Guy's Hospital on September 14th, 1839, with a dislocation of the tibia inwards at the ankle. Whilst carrying a sack of coals down a ladder into a cellar, his foot slipped, and he was precipitated to the bottom, and fell with his right ankle twisted so as to form almost a right angle with the tibia. He was picked up, unable to move spontaneously, and the dislocation found as described. When brought into the hospital he did not complain of much pain. The injured limb was placed on the outside; the foot was flexed; the tibia was pressed upon, and the dislocation became reduced in about two minutes.

SECTION III.

SIMPLE DISLOCATION OF THE TIBIA FORWARDS.

SYMPTOMS.—In this accident the foot appears much shortened and fixed, the heel is proportionably lengthened and firmly fixed, and the toes are pointed downwards. The lower extremity of the tibia forms a hard projection upon the upper part of the middle of the tarsus, under the projected tendons, and there is a depression before the tendo Achillis.

DISSECTION.—Upon dissection the tibia is found to rest upon the upper surface of the os naviculare and os cuneiforme internum; quitting all the articulatory surface of the astragalus, excepting a small portion on its fore part. The fibula is broken about three inches above the ankle, and its fractured end advances with the tibia, and is placed by its side; but its malleolus externus remains in its natural situation. The capsular ligament is torn through on its fore part. The deltoid ligament is only partially lacerated, and the three ligaments of the fibula remain unbroken.

CAUSE.—This accident arises from a fall of the body backwards whilst the foot is confined; or if a person jumps from a carriage in rapid motion with the toe pointed forwards.

TREATMENT.—The treatment consists in attending to the following rules:—The patient should be placed in bed on his back; one assistant grasps the thigh at its lower part and draws it towards the body, another pulls the foot in a line a little before the axis of the leg, and the surgeon pushes the tibia back to bring it into its place. The same principles are held in view in this mode of reduction as in the former, with respect to the relaxation of the muscles. A many-tailed bandage, dipped in an evaporating lotion, must be lightly applied afterwards. The local and constitutional treatment is the same as in the dislocation inwards.

As to position, it is best to keep the patient with the heel resting on a pillow, and to have a splint, properly guarded, on each side of the leg, having foot-pieces to keep the foot well sup-

ported at right angles with the leg, so as to prevent the muscles again drawing it from its place. As in five weeks the fibula will be united, there will then be no danger in taking the patient from his bed, and gentle passive motion may be begun.

The application of a long splint on each side, with a foot-piece to each splint, and this padded in such a manner as to give the foot a direction inwards, outwards, or at right angles, according to the direction of the dislocation, answers better than any other mode of securing it. When this is applied, the foot cannot escape from the situation in which the surgeon has placed it.

M. Dupuytren, of the Hôtel Dieu, who is a very scientific as well as an excellent practical surgeon, has recommended a single splint, well cushioned, along the outer or inner part of the leg, according to the direction of the dislocation, and fastened to the leg and foot by bandages.*

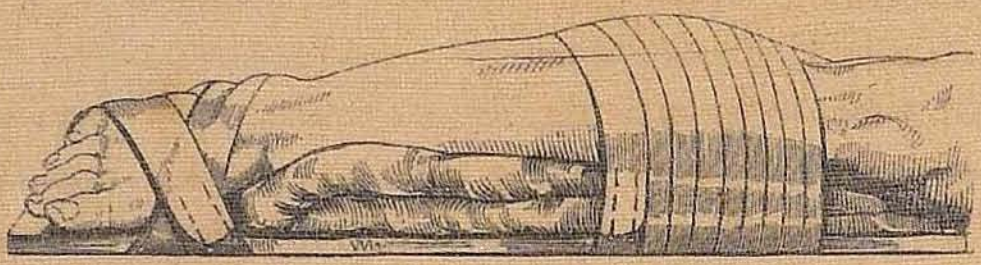

Partial Dislocation of the Tibia forwards. — This bone is sometimes partially luxated forwards, so as to rest half on the os naviculare, and half on the astragalus. The fibula at the same time is broken. The following are the signs of this accident:— the foot appears a little shortened, and is pointed downwards, and a difficulty is experienced in the attempt to put it flat on the ground; the heel is drawn up, and projects slightly; and the foot is in a great degree immovable.

Case CXLVIII.—The first case of this kind which I saw was in a very stout lady, who resided at Stoke Newington, and had by a fall, as she said, sprained her ankle. When I examined the limb I found the foot immovably fixed, pointed downwards, and attended with great pain just above the ankle. I attempted to draw the foot forwards and bend it, but could not succeed. Some years afterwards I saw this lady at Bishop's Stortford,

* See a paper on the subject in Dr. Johnson's Medico-Chirurgical Review, Vol. I.

walking upon crutches; her toe was pointed, and she was unable to bring any other part of the foot to the ground; the degree of distortion was less than that which occurs in the complete luxation of the bone forwards; but all tension having now been subdued the nature of the injury was more evident.

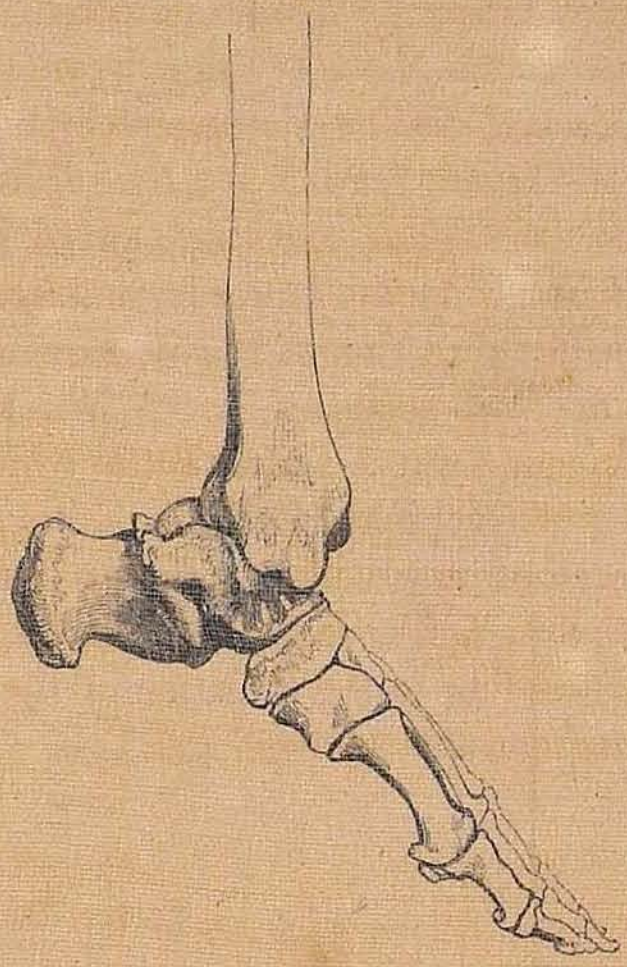

Yet I should not have known it decidedly, without an examination of a foot shown to me by my friend and late apprentice, Mr. Tyrrell, who was so kind as to give me the parts which were taken from a subject dissected at Guy's Hospital. The articular surface of the lower part of the tibia was divided into two, the anterior part was seated upon the os naviculare, the posterior upon the astragalus; these two articulatory surfaces, formed at the lower extremity of the bone, had been rendered smooth by friction. The fibula was found fractured.

The following cases were sent to me by Mr. Douglas of Glasgow.

Case CXLIX.—A woman, aged sixty, died of cancer of the breast in the Glasgow Royal Infirmary, in the year 1834. She had an unreduced dislocation of the left ankle joint forwards, of two years' standing, which I removed, and prepared for Dr. Lawrie, in whose possession it still is.

The cast taken from the limb shows the ankle in a state of complete extension, the toes being pointed down. A deep curve is seen behind where the tendo Achillis should be straight; the heel is lengthened, and the fore part of the foot is shortened. The anterior edge of the lower end of the tibia makes a projection in front, and a notch exists below it, between it and the dorsum of the foot. The outer ankle is found in its proper place; but the inner one is seen to be thrown forward about three-quarters of an inch.

The following is the appearance of the parts on dissection. I describe them with the foot resting on its sole.

The ankle is completely extended, and quite stiff. The tibia rests about three-quarters of an inch further forward than it ought. The articulating surface of the astragalus is not visible in front, but is felt far back, below the arch of the tibia. The anterior edge of the tibia is exactly over the articulation of the astragalus with the os naviculare, and is nearly three-quarters of an inch above it; so that a small part of the scaphoid cavity of the tibia behind still rests on the pulley of the astragalus. The tendon of the tibialis anticus by this means runs in a straight line to its insertion at the internal cuneiform bone, instead of curving forwards. Behind, the astragalus projects so much that the flexor longus pollicis does not run in its proper groove in the tibia at all. The astragalus and os calcis are in their proper relation to one another, and their posterior ligament is entire. Some additional ossification has taken place on the back of the tibia, close above the astragalus.

Externally, the external malleolus remains perpendicular in its situation, with its three fibulo-tarsal ligaments entire. A hollow runs obliquely upward and backward from its anterior edge, showing where a fracture had taken place, the superior anterior portion being thrown forward along with the tibia. Some new bone is deposited on their junction. The peronæal tendons preserve their proper relations.

Internally, the deltoid ligament seems to have been ruptured, though its place is now supplied. The tibio-fibular ligament must have been ruptured, though the new deposits of bone prevent its state from being accurately ascertained.

The result of this dislocation clearly proves the necessity which exists in these accidents, however slight they may at first sight appear, of not resting satisfied until the foot be returned into its natural position, and restored to its motion; for, if neglected in the commencement, severe inflammation and tension will prevent even a forcible extension from being afterwards useful; and if still longer neglected, the changes in the state of the muscles, and the union of the fractured fibula, will preclude the possibility of a reduction, even under the most violent attempts. The mode of reduction and after treatment will in no respect differ from that required in the perfect dislocation of the bone

forwards, either in regard to the relaxation of the muscles, the bandages, or the local and constitutional treatment.

No instance has been recorded by any individual of a dislocation of the tibia backwards from the astragalus. In the Cyclopædia of Anatomy a case by Mr. Colles of Dublin is noticed, which was supposed to be one of dislocation backwards; but I suspect, says Mr. Douglas, it must have been one of fracture close to the ankle-joint, such as I am going to describe.

Case CL.—Hugh Macnab, æt. forty-one, was admitted into the Glasgow Royal Infirmary in July 1834. Three years before he had fallen through the joists of a new house, upwards of sixty feet, and was struck on the anterior aspect of the left leg, immediately above the ankle-joint, by a plank which fell with him. A fracture above the joint took place; and though he was put up in splints for three months, union was never obtained, and a false joint formed.

On examination, the lower part of the tibia, with the internal malleolus, was felt attached to the astragalus, while the shaft of the tibia was thrown backwards. Considerable doubt existed among the gentlemen who examined the case whether the fibula was fractured or dislocated. Some thought it was a pure case of dislocation of both bones backwards. The leg was three quarters of an inch shorter than the right, and the foot seemed very long anteriorly, and very short behind. When he walked, the lower end of the shaft of the tibia pressed against the tendo Achillis, making it project backward, so as to cause considerable pain. The fibula was seen projecting on the outer side in a similar manner. He was thus prevented from working as a labourer, and he insisted on having his foot amputated. The following is the state of the parts, as seen upon dissection.

The tibia and fibula were both found to be fractured transversely, immediately above the ankle-joint, which remained perfectly entire. Each malleolus remained in its natural situation, with the different tendons lying in their proper grooves. A thin arch of the tibia, not a quarter of an inch in thickness, remains over the astragalus, and has formed a ligamentous connexion with its articular surface. The fractured surface had become smooth, and covered with a periosteum.

The shafts of the bones passed backwards and downwards; their extremities were covered with cartilage, and had received

new fibrous capsules, derived from the deep fascia of the leg, in front and on each side of the tendo Achillis. The end of the tibia did not rest on the os calcis, but pressed backward and downward against the tendon.

SECTION IV.

SIMPLE DISLOCATION OF THE TIBIA OUTWARDS.

This luxation is the most dangerous of the three; for it is produced by greater violence, is attended with more contusion of the integuments, more laceration of ligament, and greater injury to the bones, than either of the others.

Symptoms.—The foot is thrown inwards, and its outer edge rests upon the ground. The malleolus externus projects the integuments of the ankle very much outwards, and forms so decided a prominence, that the nature of the injury cannot be mistaken. The foot and toes are pointed downwards.

Dissection.—In the dissection of this accident, it is found that the malleolus internus of the tibia is obliquely fractured and separated from the shaft of the bone. The fractured portion sometimes consists only of the malleolus; at others, the fracture passes obliquely through the articular surface of the tibia, which is thrown forwards and outwards upon the astragalus, before the malleolus externus. The astragalus is sometimes fractured, and

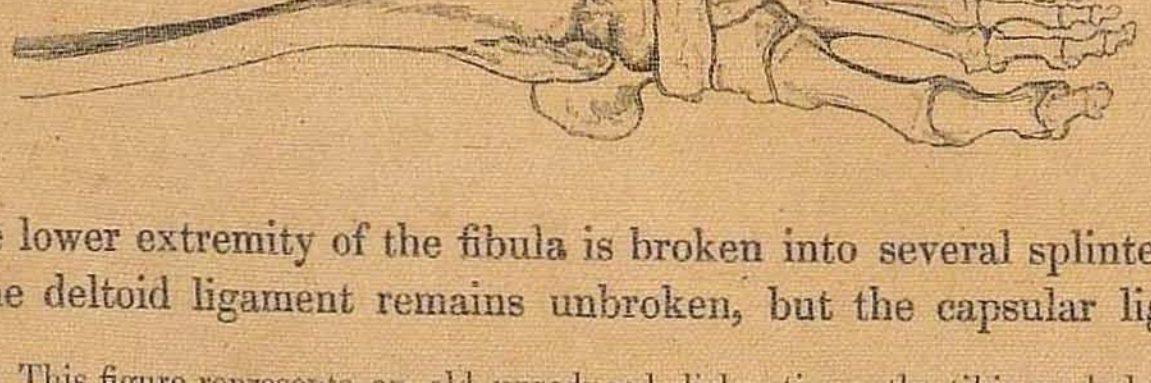

the lower extremity of the fibula is broken into several splinters. The deltoid ligament remains unbroken, but the capsular liga-

* This figure represents an old unreduced dislocation: the tibia anchylosed to the astragalus. The preparation is in the Museum of St. Thomas's Hospital.

ment is torn on its outer part. The three fibulo-tarsal ligaments remain whole in most cases, but when the fibula is not broken they are ruptured. None of the tendons are lacerated, and internal hæmorrhages scarcely ever occur to any extent, as the large arteries generally escape injury. This accident happens either by the passage of a carriage-wheel over the leg, or by a distortion of the foot in jumping or falling.

Treatment.—The mode of reduction consists in placing the patient upon his back, in bending the thigh at right angles with the body, and the leg at right angles with the thigh; the thigh is then grasped under the ham by one assistant, and the foot by another: and thus an extension is made in the axis of the leg, while the surgeon presses the tibia inwards towards the astragalus. The limb, in the simple dislocation, is to be laid upon its outer side, resting upon splints, with foot-pieces; and a pad is to be placed upon the fibula, just above the outer ankle, and extending a few inches upwards, so as in some measure to raise that portion of the leg and support it; and to prevent the slipping of the tibia and fibula from the astragalus, as well as to lessen the pressure of the malleolus externus upon the integuments where they have sustained injury.

The local and general treatment will be the same as in the former cases, although more depletion is required, as greater inflammation succeeds. The greatest care is necessary to prevent the foot from being twisted inwards, or pointed downwards, as either position prevents the limb from being afterwards useful; and this precaution is effected by having two splints, with a foot-piece to each, padded and applied to the ankle on the outer side of the leg. Passive motion should be given to the joint in six weeks after the accident, when the patient may rise from his bed, and be allowed to walk upon crutches, unless impeded by great swelling of the ankle. In the generality of these cases, from ten to twelve weeks will elapse before the cure is complete.

SECTION V.

COMPOUND DISLOCATION OF THE ANKLE-JOINT.

These accidents take place in the same direction as the simple dislocations, and the bones and ligaments suffer in the same manner as in those dislocations. The difference, therefore, in these cases is, that the joint is laid open by a wound in the integuments and ligaments opposite to the laceration of the skin, by which the synovia escapes, and through which the ends of the bone protrude. This opening in the integuments is generally occasioned by the bone, but sometimes by the pressure of some uneven surface on which the limb may have been thrown; and sometimes by a subsequent sloughing of the integuments.

The bones being replaced by the means which are employed in the simple dislocation, the effects of this accident upon the parts composing the joint are as follow:—The synovia, as I have stated, escapes by a large wound through the lacerated ligament, and in a few hours inflammation begins; and then an additional quantity of blood being determined to the part, an abundant secretion issues from the synovial membrane, and is discharged through the wound; the ligaments also participate in the inflammation, as well as the extremities of the bones which enter into the composition of the joint.

The inflammation of the internal secreting surface of the ligament, in about five days, proceeds to suppuration; at first but little matter is discharged, but it continues increasing until it becomes very abundant, and the lacerated parts of the ligaments and periosteum also secrete matter.

Under this process of suppuration, the cartilages become partially or wholly ulcerated, but in general only partially; for the ulceration of cartilage is a very slow process, attended with severe constitutional irritation, and it often lays the foundation for exfoliation of the extremities of the bones.

When the cartilages are ulcerated, granulations arise from the surface of the bones and from the inner side of the ligament, and these inosculate and fill the cavity between the extremities of the bones.

Sometimes we find after accidents to joints, that the adhesive process occurs at one part, and that the cartilage is not ulcerated; whilst granulations are formed at others, where the cartilage was removed by ulceration; and I have seen, after inflammation in joints, the cartilages remain, and their surfaces adhere.

Neither this inosculation of granulations, nor the process of adhesion, leads of necessity to permanent anchylosis; for if passive motion be begun as soon as the parts, from cessation of pain and inflammation, will permit, motion will be restored, not always entirely, but with very little diminution; and the other joints of the tarsus will acquire such an extent of motion as to render the deficiency in the mobility of the ankle-joint but little apparent. The aperture in the ligament is filled by granulations; and with respect to the extremities of the bone, when they are joined by ossific union, this junction is effected by the deposit of cartilage, and by a secretion of phosphate of lime, in the usual manner in which bones are formed and repaired.

Thus, then, the compound dislocation of the ankle leads to inflammation over a very extensive secreting surface; it produces an extended suppuration over the lining of the joint, which occasions much constitutional derangement; and, further, it becomes the source of an ulcerative process, more or less extensive, according to the treatment pursued; by which the cartilage is partly or wholly removed, and by which an irritative fever is supported for a great length of time; and the ulceration sometimes extends to the extremities of the dislocated bones, and leads to a greatly augmented constitutional irritation, and protracted disease from exfoliation.

These local effects are accompanied by the common symptoms of constitutional excitement. In two or three days from the accident, or sometimes as early as twenty-four hours, the patient complains of pain in his back and in his head, showing the influence of the accident on the brain and spinal marrow. The tongue is furred; white, if the irritation be slight; yellow, if greater; and brown, almost to blackness, if it be considerable; the stomach is disordered; there is loss of appetite, nausea, and sometimes vomiting; secretion ceases in the intestines and in the glands connected with them; and costiveness is therefore an attendant symptom. The skin has its secretion stopped; it becomes hot and dry; the kidneys also have their secretion

diminished; the urine is high-coloured and small in quantity. The heart beats more quickly and the pulse becomes *hard*, which is the pulse of constitutional irritation from local inflammation, and in great degrees of this excitement it becomes irregular and intermittent; the respiration is quicker, in sympathy with the quicker circulation; the nervous system becomes additionally affected, in high degrees of local irritation; restlessness, watchfulness, delirium, subsultus tendinum, and sometimes tetanus occur. These are the usual effects of local irritation upon the constitution, occurring in different degrees, according to the violence of the injury, the irritability of the system, and the powers of restoration.

The causes of the violence of these symptoms are, the wound which is made into the joint, and the great efforts required for its repair: for when there is no wound, and the process of adhesion can unite the part, little local inflammation or constitutional irritation can occur; and if this be the cause of the violence of the symptoms, the principle in the treatment of this accident is easily comprehended; it consists in closing the wound as completely as possible, to assist nature in the adhesive process by which the wound is to be closed, and to render suppuration and granulation less necessary for the union of the opened joint.

The first question which arises upon this subject is the following:—*Is amputation generally necessary in compound dislocations of the ankle?* My answer is, certainly not. Thirty years ago it was the practice to amputate limbs for this accident; and the operation was then thought absolutely necessary for the preservation of life, by some of our best surgeons; but so many limbs have been saved of late years, indeed, I may say, so great a majority of these cases exists, that such advice would now be considered not only injudicious, but cruel. It is far from being my intention to state that amputation is never required: I have only to observe, that the operation is unnecessary in the greater number of these accidents.

But before I give the proofs of what I have advanced, I shall state the mode of treatment which is to be pursued.

Treatment. — When the surgeon examines the limb, he finds a wound of greater or less extent, according to the degree of the injury. The extremity of the tibia projects if the dislocation of the tibia be inwards; and the tibia and fibula are protruded,

if the dislocation be outwards. The ends of the bones are often covered with dirt from their having reached the ground. The foot is loosely hanging on the inner or outer side of the leg, according to the direction of the dislocation. Sometimes, though very rarely, a large artery will be divided; and it is surprising that the posterior tibial artery so generally escapes laceration; the anterior tibial being the only vessel I have known to be torn. The arrest of hæmorrhage is the first object; and for this purpose, if the anterior tibial artery be wounded, it must be secured by ligature. The extremity of the bone is to be washed with warm water, as the least extraneous matter admitted into the joint will produce and support suppuration; and the utmost care should be taken to remove every portion of it adhering to the end of the bone.

If the bone be shattered, the finger is to be passed into the joint, and the detached pieces are to be removed; but this is to be done in the most gentle manner possible, so as not to occasion unnecessary irritation. If the wound be so small as to admit the finger with difficulty, and if small pieces of bone can be felt, the integuments should be divided with a scalpel, to allow of such portions being removed without violence; the incision should be so made as to leave the joint with as much covering of integument as possible. The integuments are sometimes nipped into the joint by the projecting bone; and then it cannot be reduced without making an incision, to allow the skin to be drawn from under the bone; and when the edges of the incised wound are afterwards brought together, no additional evil arises from the extension of the wound.

The mode of reducing the bone is, in other respects, similar to that which I have already described when speaking of simple dislocation; by bending the leg upon the thigh, so as to relax the muscles before the extension is made. When the bone has been reduced, a piece of lint is to be dipped in the patient's blood, and applied wet over the wound, upon which the blood coagulates, and forms the most natural, and, as far as I have seen, the best covering for it. A many-tailed bandage is then applied, the portions of which should not be sewn together, but passed under the leg, so that any one piece may be removed when it becomes stiff; and by fixing another to its end, the application may always be renewed without any disturbance

to the limb: this bandage is to be kept constantly wet with spirits of wine and water. A hollow splint, with a foot-piece at right angles, is to be applied on the outer side of the leg, in the dislocation inwards, and the leg is to rest upon its outer side: but in the dislocation outwards, it is best to keep the limb upon the heel, with a splint and foot-piece both upon the outer and the inner side; and an aperture in the splint opposite to the wound.

In each dislocation the patient's knee is to be slightly bent, to relax the gastrocnemius muscle. The foot must be carefully prevented from being pointed; great care being taken to preserve it at right-angles with the leg, otherwise the limb will be useless when the wound is healed. The patient is to be placed on a mattress, and a pillow is to reach from half way above the knee to beyond the foot, and another is to be rolled under the hip, to support the upper part of the thigh-bone.

Blood-letting must be adopted, or not, according to the powers of the constitution; as it is necessary to bear in mind that the patient has a great trial of his powers to undergo, and will require throughout the process of restoration, all the support which his strength can receive. Purgatives must also be used with the utmost caution, for there cannot be a worse practice, when a limb has been placed in a good position, and adhesion is proceeding, than to disturb the processes of nature by the frequent changes of position which purges produce; and I am quite sure, that in cases of compound fracture, I have seen patients destroyed by their frequent administration. That which is to be done by bleeding, and emptying the bowels, should be effected as soon as is possible after the accident, before the adhesive inflammation arises; after which the liquor ammoniæ acetatis, and tinctura opii, form the patient's best medicine, with a slight aperient at intervals.

Secondary Treatment. — If the patient complain of considerable pain in the part, in four or five days the bandage may be raised to examine the wound; and if there be much inflammation, a corner of the lint should be lifted from the wound, to give vent to any matter which may be formed; but this ought to be done with great circumspection, as there is a danger of disturbing the adhesive process, if that be proceeding without suppuration. By this local treatment, it will every now and then happen that the wound will be closed by adhesion, but if in

a few days it be not, and if suppuration take place, the matter should have an opportunity of escaping; and the lint being removed, simple dressing should be applied. After a week or ten days, if there be suppuration with much surrounding inflammation, poultices * should be applied upon the wound, leeches in its neighbourhood, and upon the limb at a distance, and the evaporating lotion should be still employed; but as soon as the inflammation is lessened, the poultices should be discontinued, as they encourage too much secretion, and relax the blood-vessels of the part, so as to prevent the restorative process.

If the cure proceeds favourably, in a few weeks the wound is healed with little suppuration; if less favourably, a copious suppuration takes place, the wound is longer in healing, and exfoliation of portions of the extremity of the bone still further retards the cure. The motion of the joint is not always lost; it is sometimes in a great degree restored; but this depends upon the greater or less extent of suppuration or ulceration. Under the most favourable circumstances, three months generally elapse before the patient can walk with crutches; in many cases, however, a greater length of time is required: he bears upon the foot at different periods of time, according to the degree of injury sustained, as in compound fracture, when adhesion is not at first produced: in compound dislocations, of course, the patient is longer in recovering.

I shall now proceed to state the cases which have induced me to say that amputation, as a general rule, is improper in these accidents.

Case CLI.—I was, many years since, going into the country with a friend of mine, and we met with a surgeon in our journey who put this question: "What do you do in compound dislocations of the ankle-joint?" I do not recollect the reply, but he proceeded to say, "I have had a case of compound dislocation of the ankle-joint under my care, in which I told the patient he must lose his limb: not approving this advice, his friends sent for another surgeon, who said he thought he could save it: the patient placed himself under his care, and the man is recovering." †

* Or the warm water dressing.—*Ed.*

† Mr. Evans of Little Hampton informs me that it was a bone-setter who prevented the amputation.

About thirty years ago, I received from Dr. Lynn, of Bury St. Edmunds, the astragalus of a man broken into two pieces, which he had taken from a dislocated ankle-joint. The case is as follows:—

Case CLII.—J. York, aged thirty-two years, being pursued by some bailiffs, jumped from the height of several feet to avoid them. The tibia and a part of the astragalus protruded at the inner ankle. I immediately returned the parts into their natural situation. Suppuration ensued; and in five weeks a portion of the astragalus separated, and another piece a week afterwards, which, when joined, formed the ball of that bone. In three months the joint was filled with granulations; it soon afterwards healed, and the man recovered with a good use of the limb.

I attended a compound dislocation of the ankle-joint, in the year 1797, with Mr. Battley, who then practised as a surgeon in St. Paul's Church-yard, and is now an eminent chemist and druggist in Fore Street. An account of this case I shall give in the words of Mr. Battley.

Case CLIII.—In the month of September 1797, a gentleman, lodging in Duke Street, Smithfield, in a fit of insanity, threw himself from a two pair of stairs window into the street, his feet first reaching the ground. He rose without help, knocked violently at the outer door of the house, and ascended the stairs without the least assistance; bolted the door after him, and got into bed. He refused to open the door, and it was obliged to be forced. A neighbouring surgeon was sent for, who, on viewing the case, proposed an immediate amputation, which was not acceded to by his friends; but Mr. Cooper and myself were requested to take charge of the case. On examination there was found a compound dislocation of the ankle-joint. The tibia was thrown on the inner side of the foot; and when the finger was passed into the wound, the astragalus was discovered to be shattered into a number of pieces. The loose and unconnected portions of bone were removed, and the tibia was replaced; after which lint, dipped in the oozing blood, was wrapped around the lacerated parts, and the limb was placed on its outer side, with the knee considerably bent. The parts were ordered to be kept cool by the frequent application of an evaporating lotion.

The patient remained as quiet as could be expected from a person in his state of mind, until the third or fourth day, when

a considerable inflammation appeared in the joint, and greatly increased the previous irritable state of his constitution. Leeches, fomentations, and poultices were applied to the limb, blood was taken from the arm, purgative medicines were given, and afterwards saline medicines with sudorifics. Extensive suppuration ensued, and continued for six weeks or two months, when it began to lessen, and healthy granulations appeared on the whole wounded surfaces: about this time the state of his mind began to improve, and it continued to amend as his leg advanced in recovery. At the end of four or five months the suppurated parts had filled up, the joint healed, and his mind recovered its natural tone. At the end of nine months he returned to his employment; but the ankle-joint was stiff. In two years he had so far recovered as to walk without the aid of a stick; and at the end of three or four years was able to pursue his avocations nearly as well as at any former period of his life.

For the following case of compound dislocation of the tibia outwards I am obliged to Mr. Rowley, apprentice to Mr. Chandler, Surgeon at St. Thomas's Hospital.

Case CLIV.—Elizabeth Chisnell was admitted into St. Thomas's Hospital on Saturday, May 29th, 1819, with a compound dislocation of the left ankle-joint outwards, occasioned by her slipping from the foot-path into the road-way. The wound communicating with the joint was situated upon the outer part of the leg, and was about four inches in extent, through which the fibula projected two inches, but it was not fractured; the ligaments connecting the malleolus externus and the astragalus were lacerated. From the inclination of the sole of the foot inwards, the whole articulating surface of the joint was so displaced as to allow two fingers to pass readily across; and on examination, I found the extremity of the tibia fractured. The parts were easily returned to their original situation by extending the foot, the leg having been first bent upon the thigh. During the reduction, the integuments became confined between the malleolus externus and the astragalus, so as to require an incision upwards by the side of the fibula, to accomplish the extrication; that being effected, its lips were brought together by four sutures, and straps of adhesive plaster. Splints were applied; and the common applications were used to subdue the consequent inflammation.

June 1. The adhesive plaster and sutures were removed, because the wound and adjacent soft parts around the ankle were in a sloughing state. Poultices of linseed meal were ordered to be used daily.

June 5. The sloughs are separated; the sore is granulating; the discharge profuse. A collection of matter has formed upon the inside of the leg, which was discharged by puncture. The wound was ordered to be dressed, and a roller was gently applied. Bark and porter were ordered by Mr. Chandler.

August 7. The wounds are almost healed. The girl sits up daily, and in a few days she will be allowed to walk.

During the progress of her cure, the constitutional disturbance has been trifling; indeed not more than in some favourable cases of simple fracture: it may be also well to observe that her bowels were regular during the whole time, so as to preclude the necessity of any laxative medicine, nor did she take any other medicine than the bark.

The following case of speedy recovery is highly creditable to Mr. Ward of Balham Hill, who communicated it to me.

Case CLV. — A man fell from a first floor window, and lighting on the outer side of his foot, suffered a compound dislocation of the ankle-joint outwards, with an oblique fracture of the inner malleolus. The reduction was very easily effected, the wound was dressed with lint; two splints with foot pieces were applied, the limb was placed on the heel, with the knee bent, and strict antiphlogistic treatment was employed for the first fortnight. I had not occasion to remove any of the dressing for the first ten days; I then found the greater part of the wound healed by adhesion, and the remaining portion filled by a clot of coagulated blood, which soon became organised; no suppuration took place, and very little constitutional disturbance manifested itself. He was confined to his bed only a month, was able to be out with a crutch and stick in six weeks, and at the end of two months was able to follow his employment as usual: he is a very temperate man, and of active habits.

The following accident I was requested to visit, by Mr. Clarke, surgeon, Great Turnstile, Lincoln's Inn Fields, who had the kindness to send me the particulars.

Case CLVI. — Mr. George Caruthers, aged twenty-two, had a compound dislocation of the ankle-joint inwards, with fracture

of the tibia, on October the 6th, 1817. The end of the tibia projected through the integuments of the inner ankle, to the extent of from two by three inches, and the bone was tightly embraced by the skin. The tibia was fractured, only a small portion of it remaining attached to the joint; the bleeding was stated to have been copious, but it had subsided before Mr. Clarke saw him. The fibula was badly fractured.

For the reduction of the protruded parts it became necessary to make an incision in the integuments, to loosen them on the tibia; and when the bone was restored to its place, simple dressings were spread over the wound. A many-tailed bandage, wetted with an evaporating lotion, and splints, were applied, and the limb was placed in the slightly bent position upon a quilted pillow. Bleeding was employed, gentle purgatives given, and saline medicines. Symptoms of great constitutional excitement naturally arose from so severe a local injury. Abscesses formed on the leg, and some exfoliations materially retarded the cicatrization of the wound, producing also considerable exhaustion of the patient's strength. Openings were made into the abscesses, adhesive straps were placed over the wounds, and lotions were applied on linen, under oiled silk, which preserved the parts constantly wet. Bark and wine were given with occasional aperients. Mr. Caruthers left town on October the 6th, 1818, having then a small opening on each side of the limb, and suffering occasional pain; but his general health had been good for some months previous. In January last, a considerable portion of bone came away, and the sore immediately healed, and has so continued: he has been ever since free from pain, and is now in better health than before the accident. He employs himself in superintending a farm, around which he walks with one crutch and a stick, but if the ground be level, with a stick only; and the limb is becoming daily more and more useful.*

To Mr. Somerville, of the Stafford Infirmary, I am indebted for the following cases.

Case CLVII.—I have a distinct recollection of the following two cases, though not of the manner in which the accidents

* In June, 1822, I wrote to Mr. Caruthers to inquire how he proceeded; and his answer was, that he could walk three or four miles easily, and eight if required; and that he would not exchange his injured leg for a wooden one for the whole of Europe.

were produced. The first occurred about fifteen years ago, the other a few years later: they were both dislocated inwards, and were both discharged cured; the one at the end of the fifth, the latter not till the seventh week. In the first case the wound, which was lacerated so as to form a flap, healed by the first intention; in the latter it was kept open by the discharge, which was at first purulent, afterwards limpid; but no untoward symptom supervened during the cure. The treatment in both cases was as follows.

After the reduction of the bone the patient was placed upon his side, with the limb in a bent position; no ligature was used, but the lips of the wound were nicely approximated, and retained *in situ* by straps of sticking plaster, of ample length, yet not sufficient to encircle the limb, lest they should, by causing undue pressure on the supervening tension, excite too much inflammation, and, in consequence, suppuration. To obviate, however, both tension and inflammation as much as possible, a plaster, spread moderately thick with Kirkland's defensative, was placed round and in easy contact with the ankle, and over the whole a tailed bandage was loosely applied. A brisk purgative was given on the following morning, and low diet was ordered till all danger of inflammation was over. The adhesive plaster was removed on the second or third day, and was not renewed; but a pledget of melilot digestive was placed over the wound, and the defensative bandage applied as before. The subsequent treatment consisted merely in the daily renewal of the pledget, and the proper adjustment of the plaster and bandage, both of which were gradually drawn tighter round the limb, in proportion as the danger of inflammation became less; and this operation was performed with the view not only to give stability to the joint, but also to facilitate the progress of cicatrization.

The use of the plaster after the manner above mentioned may, at first, appear to you a singular practice, but, by being spread very thick, it seldom requires a renewal during the period of cure, unless the discharge from the wound should be so great as to render a change necessary; but if it should not, it will appear obvious that there can be no necessity for disturbing or moving the limb from its original position, the retention of which I have ever considered, in cases both of compound dislocations and compound fractures, of the highest importance to facilitate

the cure. The plaster is composed of two parts of emp. plumbi, and one each of oil, vinegar, and chalk finely powdered; and I have ever found it a most powerful repellent in all cases of violent local inflammation.

The following case I received from Mr. Scarr, surgeon, of Bishop's Stortford.

CASE CLVIII. — John Plumb, aged thirty-eight, was in the act of ascending a ladder with a sack of oats on his shoulders, and had mounted ten feet from the ground, when the ladder slipped from under him, and he was precipitated to the ground, lighting on his feet. I was passing about two hundred yards from the place at the moment when the accident happened, and was, consequently, in immediate attendance. On the removal of his stocking, I found that the tibia and fibula had penetrated through the integuments at the outer ankle, and were lying on the outside of the foot; the articulating surface of the astragalus had penetrated through the integuments of the inner ankle, showing, on a view of the case, the foot nearly reversed, the bottom of the foot being placed where the side of the foot is naturally situated. The wounds through which the surfaces of the bone had penetrated being free, I immediately reduced the joint to its natural situation with as little violence as possible; the wounds were closed by adhesive straps, the limb placed on its outer side, and cloths applied constantly moistened with lotion of acetate of lead. The patient was then bled to about sixteen ounces; a saline mixture was given, and attention was paid to his bowels; in short, the antiphlogistic plan was persevered in with due regard to his constitutional powers: abscesses took place, which were opened in the most favourable points, and after five and twenty weeks the man was convalescent; union of the articulating surfaces took place, the wounds healed, and the patient became able to walk; he could not bear much on his foot to work till about twelve months after the accident, from which time he has constantly been able to follow his ordinary occupation.

This man (Plumb) was sent to town, and I had an opportunity of witnessing the happy result of Mr. Scarr's skill and attention.

For the following most interesting case I am indebted to a very excellent surgeon and ingenious man, Mr. Abbott, at

Needham Market, Suffolk. It is an admirable proof of what may be accomplished in these cases by extraordinary skill and attention.

Case CLIX.—April 25, 1802, Mr. Robert Cutting, a butcher by trade, near seventy years of age, corpulent, very intemperate, and subject to gout from his youth, in a dispute, when in a state of intoxication, was thrown violently to the ground, and suffered a compound dislocation of the tibia at the ankle-joint. The end of the bone was forced through the integuments nearly four inches; the wound was large and semicircular; in the struggle to stand erect, he supported his weight upon the end of the bone, which was covered with sand and dirt; the cavity of the articulating surface of the joint was filled with blood and sand, and the fibula was fractured a few inches above the joint, and the foot completely turned outwards. In this state he was driven in an open cart to his residence, a distance of four miles.

It was nearly five hours from the time the accident took place, before surgical assistance arrived, in the middle of a cold night. I attended with a well-informed pupil of mine, Mr. John Jeaffreson, who has now resided many years at Islington. A case so formidable, a large wound, the connecting ligaments lacerated, the surfaces of the articulating parts long exposed and much injured, led me to conclude, that it would be impossible to save the limb, in a constitution so disordered; however, no persuasion could prevail with a mind obstinate and inflexible; he would not submit to amputation. The surfaces were, as carefully and expeditiously as possible, made clean with warm water; the reduction was easily accomplished, the lacerated parts properly placed, and the edges of the wound nearly brought in apposition, without stitches or adhesive plasters; the limb was laid upon a proper sized thin board, excavated so as to take the form of the leg, with an opening to receive the outer ankle; this was well padded, the foot-piece raised somewhat higher than the leg; plaits of lint, wetted with the tinctura benzoini composita, were placed over the wound, which, in a few hours, formed a hard sealed cap, of a circumference that effectually excluded the air; a folded flannel bandage was applied over the limb from the foot to the knee; and the leg was laid in a flexed position. He was bled to twelve ounces. A saline purge was

given every two hours until his bowels were relieved; milk broth only was allowed for his support.

April 27th. The heat was raised a little; sleep interrupted; pulse 96; surface moist; darting uneasiness about the ankle and foot; no thirst; bowels kept cool, and the same support continued. Upon unfolding the flannel some swelling appeared to surround the ankle: a little gleety discharge had escaped from beneath the lower part of the dressing. The inflammation did not appear to be more than might be wished. Lint, wetted with the tincture, was applied so as to prevent the escape of any discharge, and to seal the covering more securely; six leeches were applied at a small distance from the inflamed part: the wounds bled freely, and afforded ease.

April 29th. He passed a good night; heat lessened; free from thirst; limb easy without tension; and the inflammation about the ankle abated.

May 2nd. The pulse had regained the natural standard. Upon examining the ankle, a small quantity of pus escaped from the lower part of the dressing. Lint, wetted in the same manner, to glue the covering securely, was used. From this time my visits became less frequent. The tincture was used whenever the surface of the cap appeared to lose its hold. At the end of ten weeks he was taken from his bed daily, and laid upon a sofa. After the first stage of symptoms, healthy actions were established. Between the third and fourth month the cap or dressing was taken from the ankle; the wound was completely cicatrised; a small abraded surface only appeared over the cicatrix, occasioned by incrusted matter. Simple dressings rendered this sound and well in a few days. During the time of the curative process the fœtor was very trifling. The thickening upon the wound was not more than might have been expected: the form of the joint was natural, and bore the appearance of being perfect. At the end of five months he was allowed to go on crutches, to place the foot on the ground, and to use such weight or pressure as his feelings could admit. For many months an application of oil, obtained from the joints of animals, was made night and morning, for an hour each time, by friction; and to please himself, the patient plunged his foot and ankle in the paunch of an ox. With these means an imperfect motion in the joint was recovered, and within twelve months he

could walk without a stick; he pursued his occupation, and lived to the age of eighty-three. The last ten years he was able to walk as well as ever he could.

To Mr. Chandler, of Canterbury, Surgeon to the Kent and County Hospitals, I am obliged for the following case.

Case CLX. — July, 1818. A bricklayer, aged thirty-six, of slender make, but of good constitution and of sober habits, fell from a height of between thirty and forty feet upon loose materials for building, and alighting upon his feet, received a very severe shock, attended with comatose symptoms, a fracture of the right thigh, and a considerable contusion and laceration of the left ankle-joint, accompanied with a dislocation of the bones inwards, the tibia resting upon the inner side of the astragalus. A portion of the lower extremity of the tibia was fractured, and the fibula was broken about three inches above the malleolus externus, and the surrounding ligaments of the joint were lacerated. Little difficulty was found in reducing the dislocation, and in replacing the fractured bones; but in consequence of the violent injury done to the joint, a question arose on the propriety of amputation. As the man had enjoyed uninterrupted health, and was of the constitution and habit least liable to the attack of inflammatory affection, I ventured to give him a chance of saving the limb. A union by the first intention of the external wound, as far as practicable, was attempted, and the limb was laid in the most convenient, yet relaxed and easy posture. Evaporating lotions were applied, and the strictest antiphlogistic system enjoined.

Considerable inflammatory symptoms ensued, with a copious discharge of synovial fluid; the limb and joint were much swollen, and it became necessary to vary the treatment by applying warm spirituous and opiate fomentations and poultices, which appeared more genial to the patient's feelings, and were therefore continued. A disposition of the contused parts to gangrene appearing, muriatic acid was added to the cataplasm, and the medicines were changed according to the state of the constitution. The disposition to gangrene ceased soon after the application of the muriatic acid: from this medicine I have often derived, in similar circumstances, great advantage. After the first fortnight, my hopes of saving the limb were confirmed by the abatement of pain and swelling, and by the mitigation of the

constitutional symptoms, the colour of the discharge improving, with less synovia, and granulations arising round the wound. The patient continued gradually to improve till about the tenth week, when the wound was nearly healed. This man was discharged in fourteen weeks quite well, although with rather an unsightly and partially stiff joint.

Mr. Chandler adds, that he had seen another case in which the injury was not so great as in the preceding, and which had perfectly recovered.

The following valuable communication I received from Sir S. Hammick, of the Royal Naval Hospital, Plymouth, in the year 1819.

Several cases of compound dislocation of the ankle-joint have fallen under my care and observation, during the eight years I served as assistant-surgeon, and the sixteen years I have been the first surgeon of this hospital; during nearly the whole of which period the country was engaged in active naval warfare, and, consequently, this hospital was in the constant receipt of important surgical cases; and I have also witnessed a few more from other causes. The result of my observations has been, that in cases of compound dislocation of the ankle-joint there is not only a chance of saving the limb, but of that limb being at a future time useful. The dislocated bones should be replaced in their situation with as little violence and injury as possible to the surrounding parts; and should any difficulty arise in returning the bones, from the smallness of the wound, I freely enlarge it with a scalpel. After they are replaced, I lay the limb perfectly extended on very soft cushions of lint arranged on three pillows, the centre one reaching the length of the leg, the upper one crossing under the ham and inferior part of the thigh, and the lower one crossing under the heel, having previously placed on these pillows a fine sheet, folded so often that when its edges are turned in, it may protect the limb from the pressure of the splints; under this sheet are laid several slips of calico, about eighteen inches long and three broad. When the limb is thus comfortably placed, taking care to fill up every hollow with lint, I draw the edges of the lacerated integuments as near together as they can be brought by the gentlest means, retaining them with small slips of adhesive plaster, and covering this with pledgets of soft lint; this done, I direct the foot to be

kept very steady, whilst I ultimately place the slips of calico, already described, over the whole length of the extremity, draw up the edges of the sheet, and apply on each side of the leg, outside of all, a very broad splint of common deal, of such length as to reach at least three inches below the foot, and as far above the knee-joint. These splints are well covered with lint, and then so secured as to afford support (but no pressure) to the whole of the leg and foot, the breadth of the splint materially contributing to the latter purpose, and allowing the tape to pass around the limb without injury. The foot ought also to be prevented from dropping or altering in the least its position, by passing a broad tape through a hole in the lower ends of the splints, which tape is to be tied, so as to secure the sole of the foot, and effectually keep it up; and it should also be secured by a stirrup bandage. When every thing is thus accomplished, the foot and leg are directed to be kept constantly wet with cold water, taking care not to sponge it immediately over the wound.

The subsequent treatment of the patient must depend upon the symptoms which arise. This is the plan I pursue in those cases where there is a probability of saving the limb.

I have seen more than one case, where, after great perseverance and risk, the limb has been saved, but, when the wounds were all healed, has been found of little or no use; as an example, a man who had had a compound dislocation of the ankle in the West Indies, from whence he was sent to England as an invalid, became my patient in this hospital, and when received, a period of thirteen months from the accident, had the whole of the lower head of the tibia (although in its proper situation) exposed, black, and carious, which at the end of a year and a half came away, more than three inches in length; and at the expiration of three years and a half from the injury, he quitted the hospital, with the wound healed, but with a shortened, deformed, and anchylosed leg, liable to break out on the slightest injury.

The great question to be decided, however, in these accidents is, in what cases the surgeon is justified in attempting to save the limb, and in what cases immediate amputation is necessary.

From all I have seen, I should not hesitate to advise the immediate removal of the limb, where the lower heads of the tibia

and fibula are very much shattered; where, together with the compound dislocation of these bones, some of the tarsal bones are displaced and injured; where any large vessels are divided, and cannot be secured without extensive enlargement of the wound and disturbance of the soft parts; where the common integuments, with the neighbouring tendons and muscles, are considerably torn; where the protruded tibia cannot by any means be reduced; and where the constitution of the patient is enfeebled at the time of the accident, and not likely to endure pain, discharge, or long confinement.

I have received the following case of compound dislocation of the tibia forwards, from Mr. Maddocks.

Case CLXI. — A stout, healthy young man, by a fall from a vicious horse, dislocated his ankle. The accident happened a few miles from Nottingham. He was immediately brought to his master's house, where I saw him, and found the end of the tibia protruding through a large lacerated and contused wound on the fore part of the ankle. The fibula was broken about four inches above the joint, and its lower end was separated from its connexion with the tibia, by a laceration of the ligament connecting it with that bone, but it did not protrude. Appearances in many respects were unfavourable, as there was much ligamentary and some tendinous laceration; but as the tibia was sound, and the fibula only transversely fractured, I was encouraged by the resources of a good constitution, and more particularly by the sanction of my friend, Mr. Wright, a practitioner of much experience, to attempt the preservation of the joint. The bones were reduced with little difficulty, and the limb was placed in a flexed position on its side on a broad hollow splint; the supervening symptoms were more favourable than could have been expected from the nature of the accident, though some portion of the integuments sloughed away, and two different suppurations took place in the joint, followed by two small exfoliations. The patient in three months recovered the use of the joint, and at this time experiences no inconvenience from the accident.

"I had also," says Mr. Maddocks, "two cases of external dislocation in boys, both of whom were healthy, and the accidents were occasioned by falls from horses; the malleoli interni were in both instances broken off, and the tibia and fibula protruded two or three inches through the integuments. In one case, the

projecting end of the fibula was left adhering by its ligament to the anterior part of the astragalus; in the other it was whole. I removed the loose portion of the fibula; the bones easily united, and the limbs were placed in an extended position, supported by long splints. In both cases the inflammation was high. In one, a large abscess formed about the middle of the leg, and a discharge of matter from the joint continued for some weeks, attended with a separation of sloughing ligamentous and membranous parts. The wound gradually healed, the discharge abated, and the boy recovered, with very little impediment to the free motion of the joint. The other boy would have been equally fortunate, but exfoliations took place on the end of the tibia, which, though small, retarded his recovery for several weeks, and left the joint less perfect in its motion than in the preceding case, but quite sufficient for the common occupations of life. You have here a plain statement of facts, without comment or embellishment. My mode of treatment has been uniformly to keep the limb *in the most quiescent state*, and to meet symptoms as they arise; and I cannot but attribute the success which attended the treatment of these cases in a great measure to that precaution."

The next case was sent me by Mr. Ormond of Trowbridge.

CASE CLXII.— On the 22nd of October last, I was called upon to attend Thomas Saxty, a lad about thirteen years of age, whose left foot had got entangled in a strap of the machinery used in the clothing business. On examination, I found a very bad compound dislocation of the tibia and fibula outwards; the bones were protruding four or five inches through the integuments, which were dreadfully lacerated; the wound extended from the external malleolus in an oblique direction to the posterior part of the tibia, and within five inches of the head of that bone, which articulates with the femur. On putting my fingers into the cavity of the ankle-joint, I found the astragalus very loose, being torn from its connecting ligaments.

On the first view of so serious an accident, I thought it would be impossible, with safety to my patient, to save the limb; but as he had received so severe a shock, the countenance being pale, and the extremities cold, I determined to defer the amputation until the constitution should be recovered from the first impression of the accident, and proceeded in reducing the limb to its

proper situation, which I accomplished with but little difficulty. I applied lint to the wound, and covered the limb with a many-tailed bandage lightly bound on; still I had no idea but that amputation must take place, and the next morning I requested Mr. Carey, a very intelligent surgeon of this town, to assist me in the operation. Owing to professional engagements, he could not accompany me to the boy before six in the evening, when, on examining the limb, there was considerable inflammation in the leg above the lacerated parts, and great tenderness in the thigh, which I then learnt had received some injury at the time of the accident. Under these circumstances, it was determined to delay the operation for the present. The limb was wrapped in a warm poultice of oatmeal and yeast, the boy placed on his left side with the limb in the bent position, and a draught with twenty drops of laudanum ordered to be taken immediately; he passed a restless night. On the following morning, October 24th, the inflammation of the leg above the injury was considerably increased, with very great tenderness on pressure; and the wound had a dry, dark, sphacelated appearance. I ordered my patient some wine and an opiate at bed-time; he passed a more comfortable night, and the next morning the appearence of the wound had improved; in the course of the 26th, a distinct line, marking the extent of mortification, could be traced.

It would be useless to record the daily progress of the case, as the detail would take up too much of your valuable time; suffice it to say, that in the course of three weeks the whole of the sphacelated parts had separated, leaving a most extensive wound. The poultices were now laid aside, and simple dressings substituted; a many-tailed bandage was applied to give support to the limb, and a splint attached on each side the leg. The discharge about this time, a month after the accident, was very considerable; but the boy having a good constitution, I began to think there might be some chance of saving the limb, and I determined not to amputate unless the symptoms should imperiously demand that operation. About four inches of the inferior extremity of the fibula were exposed to view, and would evidently exfoliate.

On November the 26th, I placed the boy on his back, the limb resting on the heel: I was induced to make this alteration in his position because my patient had experienced considerable

pain every time the limb was dressed, as it was obliged to be moved daily for that purpose.

The wound at this time did not go on so well as could be wished; it had an unhealthy appearance, with large, flabby, and shining granulations. I tried the effects of stimulants, such as a weak solution of nitrate of silver, a solution of vitriolated zinc, &c., but still without decided benefit.

On November the 30th, nearly six weeks from the time of the accident, that part of the fibula which forms the external malleolus exfoliated; and three days afterwards I succeeded in bringing away a broad portion of the articulating surface of the tibia. In a few days the discharge lessened, but there seemed no disposition in the wound to heal.

I had repeatedly witnessed the good effects of the adhesive plaster in ulcers of the leg, in the manner recommended by the late Mr. Baynton; and, as in the present case, a stimulant was required, as well as support to the edges of the wound, I considered that this dressing, applied in the form of a many-tailed bandage from the ankle to within four inches of the knee (the extent of the wound), would in all probability amend its condition and appearances. I was not disappointed, for in the course of a few days after the application of the plaster the wound began to heal; and from that time to the present the rapidity of the cure has been beyond my most sanguine expectations.

The boy is now, fifteen weeks from the time when he received the injury, able to walk, with the assistance of crutches, to the factory, a distance of half a mile from his house. To-day I observed that he could put the foot flat on the ground, and walk across the room without the assistance of a stick.

For the last two months I have daily given passive motion to the ankle-joint; but I fear, from the great extent of injury, that he will never recover the perfect use of it, though it is not so completely anchylosed as to prevent all motion.

It appears wonderful that in such a very extensive laceration, no artery requiring a ligature should have been wounded.

I do not claim to myself the merit of having saved the boy's limb, as you will perceive by the preceding statement, that he is more indebted to a fortuitous circumstance. At the time when my friend, Mr. Carey, saw it, there was too much inflammation above the seat of the injury to warrant us in amputating.

It happens occasionally, although very rarely, that complete dislocation of this joint occurs without any fracture of either tibia or fibula. An instance of this is quoted in Mr. Liston's Practical Surgery.

CASE CLXIII. — William Broughton, æt. 21, was admitted July 16th, into the North London Hospital, under the care of Mr. Liston. He was one of the men working in a tunnel of the London and Birmingham Railway, when a heavy load of clay fell upon the labourers; he observed the mass of earth giving way, and attempted to retreat, but in doing so his foot got entangled under one of the sleepers of the railway, and he was crushed. When brought into the hospital, he was in a state of collapse; the skin was rather cold, and covered with a copious sweat; both thighs were much contused about the middle and upper parts; the right was much swelled on the outer side, where there was a small wound of some depth which admitted the little finger; over the external malleolus there was a transverse wound about three inches long, exposing the cavity of the joint, and from this wound the bone projected about one inch and a half; the foot was very much inverted, and placed almost at right angles; the internal malleolus on the inner side of the astragalus, and the articular surface of this latter bone were seen through the wound. After a most careful examination by Mr. Duncan, the house surgeon, no fracture could be detected. The dislocation was very easily reduced by extending and everting the foot; the limb was then put upon a splint; and as soon as the oozing from the wound had ceased, the edges were approximated by isinglass plaster. The poor fellow made a perfect recovery.

The preceding cases must be sufficient to establish the safety and efficacy of the practice which I have recommended. In the earlier editions of this work, there were inserted communications to the same effect from many others of my friends. Mr. Richards, of Seale, in Kent; Mr. Fiske, of Saffron-Walden; and Mr. Ransome, of Manchester, favoured me with cases of severe compound dislocations, which ended in the preservation of useful limbs; and Mr. R. Smith, the surgeon to the Bristol Infirmary, and Mr. W. Wickham, surgeon to the Winchester Hospital, added the weight of their experience in favour of the same practice.

REMOVING THE ENDS OF THE BONES. — There is another

mode of treatment in these accidents, which consists in sawing off the extremity of the tibia before the bone is returned into its natural situation; and the reasons which may be assigned for pursuing this practice are as follow:—

First. That there is in some cases much difficulty in the reduction of the tibia, and great violence must be employed to effect it.

Secondly. The extremity of the bone is often broken obliquely, so that when reduced it will not remain upon the astragalus, but when the point is removed by the saw, it rests without difficulty upon that bone.

Thirdly. The spasmodic contractions of the muscles are much diminished by shortening the bone, as it throws them all into a state of relaxation; whereas, if the bone be reduced by violence when the saw has not been used, the spasm of the limb will be sometimes very violent.

Fourthly. The local irritation is much diminished by the greater ease with which adhesion is produced of the sawn extremity of the bone to the parts to which it is applied; for it is a mistake to suppose that the sawn end of the bone will not adhere; the contrary is seen in amputation, in sawing off a bone in exostosis, and in the union by adhesion of compound fractures; and that adhesive matter can be thrown out upon cartilaginous surfaces is known to every person who has dissected a diseased joint; and it is thus that the end of the tibia adheres to the surface of the astragalus.

Fifthly. When suppuration does occur it is much diminished, and a considerable part of the ulcerative process is prevented by the mechanical removal of the cartilage; for nearly half the articular surface of the joint no longer remains. Cæteris paribus, therefore, the case recovers more rapidly.

Sixthly. The constitutional irritation is very much lessened by the diminution of the suppurative and ulcerative process, and by the ease with which the parts are restored. In the cases which I have had an opportunity of seeing, there was not more irritative fever than in the mildest cases of compound fracture.

Seventhly. It has been found that in cases in which the extremities of the bones forming the joint have been broken into small pieces, and in which these have been removed by the finger,

the patient has suffered less, and has more quickly recovered, than when the bone has been returned whole.

Eighthly. I have known no case of death when the extremities of the bones have been sawn off, although I shall have occasion to mention some cases which terminated fatally when this was not done.

OBJECTIONS.—The objections which may be made to this mode of treatment are, that the limb becomes somewhat shorter by the removal of the cartilaginous extremity of the bone; but this I do not think an objection of any considerable weight, if the danger of the case be, as I believe, lessened by it; for the diminished length, which is very slight, is easily supplied by a shoe made a little thicker than usual.

The other objection is, that the joint becomes necessarily anchylosed. I doubt very much the reality of this objection, as in two instances I have seen the motion of the part remain; but even when the joint becomes anchylosed, a consequence to which it is liable in either mode of treatment, still the motion of the tarsal bones becomes so much increased as to compensate for that of the ankle, and the patient walks with much less halting than would be imagined, and has a very useful limb.

It is not my intention, however, to advocate either mode of treatment to the exclusion of the other, but to state the reasons which may be justly assigned for the occasional adoption of either. It is only by a comparison of the different results of varied practice that a safe conclusion can be drawn; and from what I have had an opportunity of observing in my own practice, and of learning from that of my friends, I feel disposed to recommend to those whose minds are not settled upon the subject, not hastily to determine against either treatment in the different cases of this injury, as from each mode, under varied circumstances, a strong and useful limb has been saved without any additional risk to the life of the patient.

If the dislocation can be easily reduced without sawing off the end of the bone; if the bone be not so obliquely broken, but that it remains firmly placed upon the astragalus when reduced; if the end of the bone be not shattered (for then the small loose pieces of bone should be removed, and the surface of the bone be smoothed by the saw); if the patient be not excessively irritable so as to occasion the muscles to be thrown into violent spasmodic

actions in the attempt at reduction, which leads to subsequent displacement when the limb has been reduced; the bones should be at once returned into their places, and the parts should be united by the adhesive inflammation; but rather than amputate the limb, if the above circumstances were present, I should certainly saw off the ends of the bones.

I shall now proceed to state the cases which I have myself had an opportunity of witnessing, and some which have been furnished by my friends, and shall leave the reader to judge of the propriety of the advice I have given.

Case CLXIV. — I was sent for to Guy's Hospital, to see Nathaniel Taylor, aged thirteen years, and was directed to bring my amputating instruments with me, being informed that the boy had so bad a dislocation of the ankle that the limb could not be saved.

As soon as I arrived at the hospital, I ordered the patient into the operating theatre; and making inquiries into the cause and nature of the accident, I found it to be as follows: — The injury had been occasioned by a boat falling upon the leg. A large wound appeared at the outer ankle, through which the tibia and a fractured extremity of the fibula projected; one inch of the malleolus externus remained attached to the astragalus by its natural ligaments; the foot was turned inwards so as to be capable of being brought in contact with the inner side of the leg; and as the muscles were no longer on the stretch, the foot was very loose and pendulous. I tried to reduce the limb, but found that the bone could only by great violence be brought on the astragalus, and that it immediately slipped from its place. The case was, therefore, as regarded the state of the parts, the most unfavourable possible, and those around me urged an immediate amputation; but seeing the character of health which the boy bore, I thought I should not be justified in probably dooming him to a life of mendicity, and I determined to try to preserve the limb. Finding that the lower end of the fibula, although still connected by ligament, was very loose and movable, I removed it with the scalpel; I then sawed off half an inch of the lower extremity of the tibia. When these operations had been accomplished with the greatest care, I reduced the bones, and they maintained their situation, as there was no force of muscular action upon them, on account of the shortening of the bones.

Lint, dipped in the patient's blood, was then applied, with adhesive plaster over it; and the leg was put in splints, and placed on the heel. Scarcely any constitutional irritation occurred; the wound and ankle-joint secreted but little matter, and gradually healed. On the 17th day, an abscess showed itself on the tibia, which was suffered to burst, as it had little affected his constitution. In two months he was allowed to sit up and use his crutches. In twelve weeks the wound was healed, and the boy was able to bear on his foot; and at the end of four months he walked well. I experienced inconceivable pleasure in seeing this boy walk before the students, at my desire, from one end of the ward to the other, four months after the accident, with very little lameness. There seemed to be some motion at the ankle, but the tarsal bones soon acquired sufficient mobility to give to the foot so much play as to prevent the appearance of stiffness, which a partially anchylosed state of the ankle would otherwise have produced.

Case CLXV. — —— West, Esq. aged forty, on December 11th, 1818, jumped out of his one-horse chaise, alarmed by the horse kicking. He fell, and when he attempted to rise, found his left ankle dislocated, and the bone projecting through the skin. Mr. Mackinder, surgeon, brought him to the house of his father-in-law, in London, where Mr. Jones, of Mount-street, and myself attended him.

Upon examination of the part, I found the tibia projecting at the inner ankle through the integuments, which were nipped under the projecting bone into the joint; the foot was loose and pendulous, and very much thrown outwards. Having prepared several pieces of linen to form a many-tailed bandage, and procured pillows and splints, the patient was placed on a bed on his left side, and an attempt was made to reduce the bone; but hearing from Mr. Jones, that Mr. W. was of a most irritable constitution, and finding that most powerful extension must be made, and that the integuments must be divided opposite to the joint, so as to lessen the probability of an easy adhesion of the wound, which was placed one inch and a half above the articulation, I sawed off the end of the tibia, and the bone most easily returned into its natural situation, in which it remained without difficulty. The edges of the wound were brought together by a fine thread, so as to be very closely adapted to each

other, and lint dipped in blood was applied over the wound; the many-tailed bandage was used; the limb was placed on its outer side, with the knee bent nearly at right angles with the thigh, and splints were applied. The leg was ordered to be kept constantly wet with the liq. plumbi, acetat. dilutus, ℥ v., and spir. vini. ℥ i.; a dose of opium was given to him, and ten ounces of blood were taken from his arm. In the evening, more opium was administered; and a dose of infusion of senna and sulphate of magnesia was ordered for the morning.

Dec. 12. As the limb felt hot, the upper splint was removed, its pressure being somewhat painful, and preventing free evaporation. Opium was ordered at night.

Dec. 13. The foot was vesicated. He had chillness succeeded by heat; slight tension of the leg, and some pain for three hours. His mind was much agitated by seeing his children.

Dec. 14. The limb was less inflamed, and he had scarcely any constitutional irritation.

Dec. 15. A slight discharge of serum mixed with red particles from the wound; some pain in the foot and leg, but no irritative fever.

Dec. 16. There was more discharge, and some air passed from the wound; a poultice was applied, and a generous diet allowed, as his stomach, naturally weak, had become very flatulent. Pulse 90.

Dec. 17. A fomentation and poultice applied.

Dec. 18. The discharge was becoming purulent; but as his stomach was deranged, he was visited by Dr. Pemberton, who ordered him hyoscyamus with the mistura camphoræ in the day, and opium at night.

From this time to the 7th of January, the discharge from the limb was copious, but it then began to lessen; and when the leg was examined on the 12th of January, it had become firm; a small wound remained, on which the granulations were prominent. In the first week in February, he was allowed to get upon his sofa, the limb being now firm, and only a small wound remaining, from which an exfoliation will occur, as the bone can be felt bare.

In August I saw him; the wound still remained open, and the portion of bone had not separated.

This gentleman, with the worst constitution in regard to the state of his stomach, did not suffer so much irritation as a compound fracture usually produces.

Mr. Charles Averill, dresser to Mr. Forster, Surgeon of Guy's Hospital, had the kindness to send me the following particulars of a case, the progress of which I often witnessed with pleasure.

Case CLXVI.—John Williams, a sailor, aged thirty-eight, a very robust man, was brought into Guy's Hospital, under the care of Mr. Forster, August 9th, 1819, at four o'clock in the morning, with a compound dislocation of the right ankle inwards, and considerable injury to the left, occasioned by his falling from a height of about twenty-six feet, in endeavouring to escape from the Borough Compter, in which he was imprisoned. On examining the injured part I found the tibia protruding three inches through a large transverse wound of four inches in extent, and resting on the inner side of the os calcis; the cartilaginous surface of the astragalus could be readily felt on passing my finger into the wound; the fibula was broken. I first sawed off the whole of the cartilaginous end of the tibia, when the bone was easily replaced; the edges of the wound were then brought as much in contact as possible; lint dipped in blood was applied, and over it straps of adhesive plaster; the foot and leg were wrapped in cloths wet with a lotion of acetate of lead, and the limb was laid on its side. He complained of great pain in the left leg, which was very much swollen all around the ankle; ten leeches were applied to it, and afterwards the liquor plumbi subacetatis dilutus, which relieved the pain; thirty drops of laudanum were given; and he remained easy. On the following day, sixteen ounces of blood were taken from him, and five grains of calomel were given. On the 12th, the dressings were removed; the wound looked well. On the 17th, suppuration had commenced, and the discharge having rather a fœtid smell, the nitric acid lotion was applied.* September 2nd, the matter gravitating to the outer side of the leg, an opening was made, by which it was discharged, and adhesive plaster applied to the original wound,

* The nitric acid lotion, during the sloughing process, is the best application with which I am acquainted. I order it in the proportion of fifty drops of the acid to a quart of distilled water, and apply it by linen covered with oiled silk.

which was healing fast; the discharge gradually diminished, and on the 21st of September, six weeks from the accident, both wounds were quite healed. He has not yet left his bed. There is motion at the ankle; the toe turns out but very little, and does not point downwards. He wears splints, and the strength of the limb is daily increasing. When the swelling of the left ankle diminished, a fracture of the external malleolus was also there discovered.

This man escaped from the hospital on the 24th of October, and two months afterwards was retaken, and confined in the Borough Compter. He has free motion of the right ankle, and suffers more from the injury to the left.

For the following communication I am indebted to Dr. Kerr, of Northampton, who, at the age of more than eighty, (July 1819,) still continues to practise his profession with all the ardour of youth, and with a strength of intellect which has been seldom surpassed.

"Several cases of compound dislocation of the ankle have fallen under my care, and it has been uniformly my practice to take off the lower extremity of the tibia, and to lay the limb in a state of semiflexion upon splints; by this means a great deal of painful extension, and the consequent high degree of inflammation, are avoided. The splints I use are excavated wood, and much wider than those in common use, with thick movable pads stuffed with wool. I keep the parts constantly wetted with a solution of liquor ammoniæ acetatis, without removing the bandage. In my very early life, upwards of sixty years ago, I saw many attempts to reduce compound dislocation without removing any part of the tibia; but, to the best of my recollection, they all ended unfavourably, or, at least, in amputation. By the method which I have pursued, as above mentioned, I have generally succeeded in saving the foot, and in preserving a tolerable articulation."

To Dr. Rumsey, of Amersham, I am obliged for the following interesting communication.

Case CLXVII.—On June the 21st, 1792, Mr. Tolson, aged forty years, was thrown from a curricle. The injury he received consisted in a compound dislocation of the tibia and fibula at the outer ankle of the left leg, with a fracture of the astragalus (the superior half of which was attached to the dislocated

bones of the leg), and likewise a simple fracture of the os femoris on the same side. He was conveyed to a friend's house on the common, where he had the advantage of an airy, healthy situation, with every kind of domestic attention. I saw him about two hours after the accident, and found the bones protruding at the ankle through a very large wound, with the foot turned inwards and upwards, and the integuments beneath the wound exceedingly confined by the dislocated bones, which descended nearly to the bottom of the foot. A considerable hæmorrhage had taken place, but was stopped by the spontaneous contraction of the lacerated vessels.

From such a formidable accident, in so large a joint, there appeared very little probability of the patient's recovery without immediate amputation; I therefore requested that a consultation with some other surgeons might be expeditiously held on the case, and expresses for this purpose were accordingly sent to Mr. Pearson, surgeon in London, and to my brother, Mr. Henry Rumsey, surgeon at Chesham, in this county. While I was waiting for their arrival, the patient requested me to examine his thigh, when I plainly discovered an oblique fracture of the os femoris at its superior part. This additional evil appeared to me a great obstacle to an amputation. My brother, when he arrived, being of a similar opinion, I attempted to reduce the fractured dislocated joint into its proper situation. This I found very difficult without first separating that part of the astragalus which was pendulous to the tibia, having its capsular ligament lacerated half way around the joint. This portion of the astragalus consists of the broad smooth head by which it is articulated to the tibia; of almost the whole of the inner and outer sides of this head, by which it moves on the inner and outer malleoli; and of about the upper half of the posterior cavity on its under surface, by which it is united to the os calcis; so that the bone was divided nearly horizontally, and the part left behind consisted of the lower half of the last-mentioned cavity, of the whole of the other or anterior cavity which connects it with the os calcis, and of the anterior portion or process by which it is articulated to the os naviculare. I therefore removed it without hesitation, being persuaded that if it had been practicable to reduce it into its original situation, so large and movable a portion of bone would have been a source of pain and irritation,

and have rendered the cure more difficult and uncertain. I then divided that portion of the integuments of the foot which was confined by the protruded end of the tibia, which enabled me with ease to reduce it and the fibula into their proper situation. I applied some dossils of lint dipped in tincture of opium to the wound, and covered the whole with a poultice of stale beer and oatmeal. We now reduced the fractured femur, and placed the limb in a bent position, expecting that our greatest success would be in procuring a complete anchylosis, the failure of which I concluded would leave a useless foot. The under splint was a firm excavated piece of deal, of the shape of the leg and foot, with a hole opposite the ankle. Mr. Pearson arrived in the evening, and approved of the preceding treatment, giving it as his opinion that it would be safer to attempt the preservation of the limb than to amputate, under such complicated circumstances. The wound was concealed as much as possible from the external air, and the cataplasm renewed no oftener than the discharge rendered necessary.

June 22nd. The preceding night had been very painful, with delirium and vomiting; the pulse was full and frequent: I took away ten ounces of blood, and gave potassæ tartras and manna in doses sufficient to procure stools. A common saline draught, with antimonial wine and tincture of opium, was given every four hours, and a fuller dose of tincture of opium at bed-time.

23rd. The vomiting continued; the ankle and thigh had been less painful through the night; the saline draughts were continued, but without the antimony, on account of the vomiting; during this period the antiphlogistic regimen was strictly adhered to.

24th. The night had been tolerable; the vomiting had ceased; the pulse was softer; the saline draughts were continued, with the opiate, at bed-time; this evening the leg was very painful; he passed a pretty good night; a discharge from the wound now commenced, and the tension of the muscles of the thigh began to diminish.

26th and 27th. The same treatment was continued. The discharge increased, and the tension of the thigh still more abated.

28th. The ankle was much swelled and inflamed; I therefore exchanged the beer-grounds in the cataplasm for the liquor plumbi subacetatis dilutus. The patient had this day much pain

in the bowels from flatulence; from which circumstance, and that of the discharge being very thin, it was judged expedient to vary his mode of living, and likewise his medicines.

29th. He was allowed a small portion of animal food, some table beer, and some port wine; and he took the bark liberally, both in substance and in decoction. This change of treatment agreed with him perfectly well. At this time I found it necessary to alter the position of the limb, on account of the pressure on the wound, occasioned by its lying in the bent position, and by the pain caused in turning to dress it, which, from the copious discharge, there was now a necessity for doing night and morning. I therefore placed it on the heel, using the common deal flexible splint, of the length of the limb, and confined it in a box, whose sides and lower end let down; the space between the sides of the box and splint was filled with pieces of flannel. By these means, and the use of the eighteen-tailed bandage, the dressings were applied with very little disturbance to the leg, and thus the patient escaped much pain. The upper end of the box under the ham being raised, gave the muscles some degree of flexion, and at the same time was favourable to the discharge. The foot having a tendency to fall inward, and the end of the fibula to protrude through the wound, it required great attention to prevent the deformity which the neglect of these circumstances might have occasioned. The mode of prevention which I adopted, and which proved successful, consisted in employing a number of small deal wedges, about six inches long, two broad, and a quarter of an inch thick; as many of these as were found sufficient were placed opposite the inside of the foot, between it and the side of the box; others, in the same manner, were placed on the outer side of the calf of the leg, by which means the limb was kept steady; and by keeping the heel in an easy and rather hollow position, none of the usual evils arising from pressure on the heel occurred.

30th. The bark agreed very well; the opiate was continued at bed-time; the discharge was great, but more purulent; the pulse was become softer and less frequent, and the urine, which had hitherto been clear and very high coloured, was now turbid; the pain and inflammation being much diminished, the cataplasm was discontinued; the wound was dressed with dry lint, with a pledget of cerat. plumbi superacetatis over it, and a mo-

derate compression was made by means of a bandage. From this period the wound progressively mended; the discharge diminished; granulations formed, and the surrounding skin began to heal. The use of the bark and of the opiate was continued till the beginning of August. About the end of July, the progress of the cure was retarded by matter collected under the integuments, above the inner ankle, which on pressure came out at the wound. After in vain trying the effects of permanent pressure for the prevention of this deposit, I made an incision into the cavity and filled it with dry lint, to produce inflammation on its internal surface, which consolidated it; and the wound became perfectly cicatrised by the middle of September, without any exfoliation of bone larger than the head of a pin having taken place. The fracture of the femur went on very well, excepting that its obliquity, with the impossibility of producing a permanent extension on account of the leg, occasioned a degree of curvature which it otherwise would not have had. The limb gradually acquired strength, and the patient is able to walk very well with only the aid of a small stick, and even this assistance he will probably not require long. There is no anchylosis to render the ankle immovable; but a sufficient firmness has been produced in the surrounding parts by the long continued inflammation to assist in the formation of an artificial joint, which possesses a degree of motion nearly equal to that of the natural.

For the following most interesting case I am indebted to Mr. Hicks, of Baldock.

Case CLXVIII. — Early in the morning of November 10, 1812, the Stamford coach, from the carelessness of the guard in neglecting to chain the wheel, ran with great velocity down the hill a mile below Baldock, and fell on its side a little before it reached the foot of the hill; in its fall, the side of the coach caught the coachman's right leg, and turned the foot upon the outside of the leg, by which the tibia became dislocated on the inner side; the tibia and fibula protruded through the integuments about four inches; the oblong end of the fibula was fractured, and several small portions of it remained within the integuments; the end of the tibia had some small portions chipped off, it appearing as if it had been ground by the side of the coach. In this state he was brought to Baldock, with his foot

dangling to his leg; the wound was very large, so much so, that the foot appeared almost separated from the leg; the ends of the bone were covered with dirt.

As there was not the least chance of success in returning the tibia and fibula within the integuments, in this state, and as the patient was anxious for the preservation of his leg, which I likewise was very desirous to save, I judged it prudent to saw off the ends of the tibia and fibula, the foot at the same time lying on a pillow below the leg. After removing the ends of the tibia and fibula, I searched for the fractured portions of the fibula left within the integuments, by introducing the fore-finger of my right hand into the wound, and found its external malleolus fractured into several small pieces, but still adhering by its ligaments to the astragalus. Being fearful that these shivered portions might be deprived of the properties of life, and that, if so, they might produce much mischief, I resolved to dissect them out, by means of a bistoury, through the wound. Having thus removed every fragment of the fibula, and rendered the ends of the tibia and fibula perfectly smooth by means of a saw, not only removing their fractured ends, but making the separation as high up as they were stripped of their periosteum, (about one inch and a half in length, measuring from the malleolus internus,) I then returned the remaining part of the tibia and fibula that had perforated the integuments, placing it in a straight line with the leg; the lacerated integuments I brought into contact, and secured them by straps of adhesive plaster; the limb was then placed upon a soft pillow, supported by Mr. Pott's long splints placed on the outside of the pillow, and fastened with tapes; compresses of soft linen cloth were applied, and the leg was kept constantly wet with the diluted solution of the acetate of lead, and a saline purgative with ipecacuanha was given for the first few days, every four hours, and afterwards every six or eight, with a regimen strictly antiphlogistic.

Through the whole of the cure the man went on remarkably well, and had little symptomatic fever; pulse constantly below the natural standard, between 60 and 70; skin soft and moist; the action of the intestines was regularly kept up by the draughts; and the integuments united by the first intention without the least secretion of pus. On the day seven weeks from the accident, the patient was removed from Baldock to his residence

at Hewlington, and did not require chirurgical aid afterwards. In a few months afterwards he paid me a visit at Baldock, walked perfectly well, and the leg was very little shorter than the other. The last time I saw him was by chance in April, 1815, at the Bell New Inn, about three miles below Baldock, where his coach stopped, and he descended and ascended his box with great agility.

My friend and late dresser, Mr. Cooper, of Brentford, an ingenious surgeon and an excellent man, sent me the following valuable communication.

Case CLXIX.—Thomas Smith, aged thirty-six, by trade a painter, whilst at work on the 28th of October, 1818, fell with a ladder to the ground, when his leg getting between two of its steps, the foot was dislocated inwards. The fibula was broken five inches above the joint, the tibia was fractured from the ankle-joint longitudinally about three inches; this small piece of tibia, three inches in length, remained attached to the joint at the inner malleolus, while an inch and a half of the remaining portion of the tibia, with the extremity of the fibula, were thrust through an opening in the integuments, at, and rather anterior to, the outer malleolus. I was passing at the time, and attempted by very moderate extension to reduce the dislocation; this not succeeding, and finding the integuments tucked under the protruding portion of bone, with a scalpel I dilated the wound anteriorly and posteriorly about half an inch, and then, by means of a metacarpal saw, removed rather more than an inch of the tibia, and a small portion of the fibula. This dislocation was now reduced without any difficulty. The wound was closed by two ligatures and a few straps of adhesive plaster. The patient was placed on a mattress with the limb on the heel, enveloped in an eighteen-tailed bandage, which was applied just sufficiently tight to give moderate support, without producing or increasing tension; on either side was placed a splint, and the limb was kept constantly cool by means of an evaporating lotion.

Subsequent to the operation, and during the whole of the night, there was some hæmorrhage from the articular arteries, but not sufficient to induce me to undo the limb in order to secure the bleeding vessels, and I did not open it till the 31st of October, the fourth day, when considerable adhesion had taken place, and the parts looked better than I could have expected;

but on the eighth day there was a line of separation formed about five or six inches in circumference; the wound was now fomented, a linseed meal poultice was applied to it every six hours, and the evaporating lotion was still applied to the limb as far upwards as the knee. On the thirteenth or fourteenth day the slough came away, and healthy granulations were observable, both upon the integuments, and also upon the extremity of the tibia; when these granulations became exuberant, they were kept down by the nitrate of silver, and the wound was slightly dressed either with ungt. cetacei, or equal parts of ungt. resinæ and cerat. calaminæ. In five weeks the wound was perfectly healed: the union of the fractured portions of the tibia went on so well, and the ossific deposit at the joint became so firm, that on Christmas-day, being fifty-eight days from the time of the accident, I found the man sitting at his table dining with his family, and in three months he was in the street, on crutches.

This patient had repeatedly suffered much from colica pictorum; his digestive organs were unhealthy, and he was a man of nervous temperament; all which particulars I had to discover after the accident. As early as the third day he was very restless; on the fourth, his sensorium was much affected, and he was constantly vomiting; by the frequent administration, however, of the saline mixture in the act of effervescence, his stomach was quieted.

I ought to have observed that, on the night of the accident, he took an opiate, and on the following day, I purged him; but from the state of his pulse, and from the degree of hæmorrhage, I did not find it requisite to take blood from the arm. By the eighth day, his stomach being tranquil, we were enabled to assist the separation of the slough, by invigorating the powers of the system with bark and port wine; from half a pint to a pint of which, with eight ounces of the decoction of cinchona and opium, the quantity being regulated by his state of irritability, enabled him to support the immense suppuration at the joint, which, from this time to the fourth week, discharged most copiously.

I may here mention, that I never observed, on the one hand, the stimulating effects of opium, and on the other, its sedative effects, so strikingly exemplified as in this man: for if he did not take quite enough to produce sleep, he was literally mad, tearing the bed clothes, swearing, praying, singing, and making the odd-

est grimaces possible; but if he had a full dose, which by the third week had been increased to two drachms of laudanum, he slept soundly and awoke refreshed; and I believe from his extremely susceptible state, that, but for opium, which produced a directly sedative effect upon his nervous system, he would have sunk from constitutional irritation. At the end of the second week, his stomach being in a fitter state for digestion, he was allowed a plentiful supply of animal food and good beer, with which, and wine, bark, and opium, continued for a week or two, he perfectly recovered.

I saw this man on March the 1st, 1820, and I said, "Would you rather have your present or an artificial leg?"—"Sir," said he, "my injured leg is nearly as useful to me as the other; I can go up a ladder, and follow my business as a painter, nearly as well as ever."

Mr. Tyrrell, surgeon to St. Thomas's Hospital, sent me the next case in the year 1824.

Case CLXX.—James Price, aged thirty-nine, a very robust man, was coming to town on Monday, the 1st of March, in a light cart drawn by one horse. In passing through Clapham the horse ran away, and falling, overturned the cart, and threw Price's legs under one of the shafts; in endeavouring to extricate himself he received a severe injury to the right ankle. By the direction of Mr. Parratt, he was immediately conveyed to St. Thomas's Hospital, where I saw him; and on examination found that the tibia had been dislocated forwards and a little inwards, its inferior extremity resting on the fore part of the astragalus and os naviculare: the deltoid ligament must have been torn through, as the inner malleolus was not fractured. The heel projected very considerably, and the foot was turned outwards in a slight degree and downwards, the toes being pointed. The fibula was fractured about two inches above the external malleolus, at which part there was a considerable depression. The reduction was very easily accomplished by flexing the leg on the thigh, which was firmly held by my dresser, Mr. Campbell, as I drew the foot downwards and forwards, and pressed the tibia backwards. The limb was placed in the flexed position, on the heel; since which time the patient has been perfectly tranquil, and the limb remains in its proper position.

For the next case I have to thank Mr. Carden of Worcester.

CASE CLXXI.—A boy, fifteen years of age, was admitted into the Worcester Infirmary, under Mr. Sandford, with compound dislocation of the ankle; the protruding portion of the tibia was sawn off, the anterior tibial artery was taken up, the limb was placed on its outer side, the wound dressed superficially, and the dressings retained with a many-tailed bandage, kept wet with the liq. ammon. acet. Suppuration and granulation came on kindly. The boy wore tin splints for a length of time, and on his recovery had a slight motion of the ankle-joint.

To the foregoing cases I might add many others. My friend Dr. Lynn, and Mr. Needham of Leicester, each sent me a case of perfect recovery. Mr. Fletcher of Gloucester told me in 1819, that of six cases which he remembered, four were amputated immediately; one after seven months; the other recovered without amputation: but all of these were very severe accidents from machinery.

EXPERIMENT.—I was anxious to ascertain what steps nature pursued in order to restore a part in which the extremity of a bone, forming a joint, had been sawed off; and I therefore instituted the following experiment.

I made an incision upon the lower extremity of the tibia, at the inner ankle of a dog, and cutting the inner portion of the ligament of the ankle-joint, I produced a compound dislocation of the bone inwards. I then sawed off the whole cartilaginous extremity of the tibia, returned the bone upon the astragalus, closed the integuments by suture, and bandaged the limb to preserve the bone in this situation. Considerable inflammation and suppuration followed; and in a week the bandage was removed. When the wound had been for several weeks perfectly healed, I dissected the limb. The ligament of the joint was still defective at the part at which it had been cut. From the sawn surface of the tibia there grew a ligamento-cartilaginous substance, which proceeded to the surface of the cartilage of the astragalus, to which it adhered. The cartilage of the astragalus appeared to be absorbed only in one small part; there was no cavity between the end of the tibia and the cartilaginous surface of the astragalus. A free motion existed between the tibia and astragalus, which was permitted by the length and flexibility of the ligamentous substance above described, so as to give the advantage of a joint where no synovial articulation or cavity was to

be found. This experiment not only shows the manner in which the parts are restored, but also the advantage of passive motion: for if the part be frequently moved, the intervening substance becomes entirely ligamentous; but if it be left perfectly at rest for a length of time, ossific action proceeds from the extremity of the tibia into the ligamentous substance, and thus produces an ossific anchylosis.

CASES WHICH RENDER AMPUTATION NECESSARY. — But still cases occur in which the operation of amputation will be rendered absolutely necessary, either to preserve the life of the patient, or to prevent his being doomed to the constant necessity of using crutches on account of the deformity and stiffness of the limb.

It seems to me, however, to be by much too prevailing an opinion, that the amputation of the limb is a sure means of preserving life; for when this operation used to be more frequently performed in our hospitals than it now is, for compound dislocation of the ankle and compound fracture of the leg, a considerable number of our patients died. Very lately a man at Tring had his foot torn off by a threshing machine, and the limb was obliged to be amputated at the usual place below the knee. The operation was performed by Mr. Firth, but the man died in the evening of the sixth day; and a case has occurred since the publication of the second edition of my Essays of equally fatal termination.

The circumstances which I have known to create this necessity are,

(1.) *The advanced Age of the Patient.*—Under great age the powers of the body become so much weakened, that the patient is unable to bear the constitutional excitement which the suppurative inflammation of the joint produces; and as amputation does not expose him to this process, it is better to have recourse to that operation. However, I ought to observe, that when in my lectures I have stated what I have now advanced, the pupils have flocked around me after lecture, and have told me of cases of recovery, even of very old persons; but in the practice of hospitals in this great metropolis, very aged persons sink under these accidents, if the limb be not amputated.

(2.) *A very extensive lacerated Wound will give rise to a necessity for this Operation.*

Case CLXXII. — July 10th, 1806, Mr. Dudin, a gentleman residing in Horselydown, Borough, jumped out of his one-horse chaise, and dislocated the tibia inwards at the ankle, through a large lacerated wound, and a portion of the malleolus internus was broken off and remained attached to the astragalus. The wound bled freely, and the foot was loose and pendulous; I therefore felt myself obliged to amputate the limb.

Mr. D., after this operation, proceeded in every respect favourably; recovering without any untoward symptom.

Case CLXXIII. — James Morrise, aged thirty-six, was admitted into St. Thomas's Hospital, on the 29th of January, 1824, under the care of Mr. Green, having sustained a dislocation of the ankle-joint, in consequence of having his leg caught in the coil of a rope, to which a great weight was appended.

The injury was accompanied with so much loss of integument, that immediate amputation was proposed, to which the man would not give his consent. Mr. Green sawed off the end of the bone and replaced the tibia upon the astragalus; but the end of the tibia, from deficiency of skin, still remained exposed. The constitutional and local irritation which followed, rendered it necessary to amputate the limb, which was done on March the 19th, being seven weeks and one day after the accident. With Mr. Green's permission I then dissected it, and the following is the result.

Dissection.—The cellular membrane was loaded with serum; all the muscles remained in a sound state, but the tendon of the tibialis anticus was partially torn, as was that of the peroneus tertius; those of the tibialis posticus, and flexor longus digitorum pedis adhered strongly to the posterior portion of the capsular ligament. An abscess extended between the tibialis posticus and gastrocnemius muscles from the ankle nearly to the place of amputation. The arteries and nerves were undivided, but the anterior tibial artery was greatly diminished by the altered position and pressure of the tibia. The deltoid ligament, the anterior part of the capsular ligament, and the tendon of the tibialis anticus in part, were torn through. The fibula was broken four inches from the ankle-joint; its lower fractured extremity overlapped the upper about an inch, and the latter was situated between the lower portion of the fibula and the

tibia. The bones were not completely united, and the fibula was exfoliating at the upper end of the lower portion; a part of the fibula also remained detached, which had been broken off at the time of the accident. The lower end of the tibia was dead and exfoliating, and rested upon the astragalus: its periosteum was much thickened above the exfoliating part. The outer posterior portion of the tibia next the fibula was broken off, and strongly adhered to the fibula. The surface of the astragalus was in parts deprived of its cartilage by ulceration.

The exposure and subsequent exfoliation of the tibia, the exfoliation of the fibula, and the large abscess, led to the necessity for amputation.

(3.) *A difficulty in reducing the Bones has been considered as a reason for Amputation.*—This circumstance, however, is rather a motive for removing the extremities of the bones by the saw than for performing the operation of amputation, after which the reduction of the tibia is easily effected, and a useful limb is preserved to the patient.

(4.) *The Bones are sometimes extremely shattered.*—If the lower extremity of the tibia be broken into small pieces, the loose portions of bone ought to be removed, and the end of the tibia be smoothed by a saw; but if, in addition to this comminution, the lower extremity of the tibia be obliquely broken, and a large loose portion of bone be felt with the fingers, then it will be proper to amputate; also, if the astragalus be broken, the portions of this bone should be removed, otherwise they will separate by ulceration, or occasion considerable local irritation. (See Case CLXVII.) But if the end of the tibia and tarsal bones, as the astragalus and os calcis, are broken, then amputation will be required. The following case shows well the necessity of the operation in such a state of parts.

Case CLXXIV. — I was requested to see a lady, aged thirty-four years, who, on August the 9th, 1819, had, in a fit of insanity, jumped out of a two pair of stairs window, and produced a compound dislocation of the tibia and fibula at the outer ankle. At the lady's residence I met Mr. Stephens, a surgeon residing in Hunter-street, Brunswick-square, who had been called in immediately after the accident. As she appeared almost insensible, and Mr. Stephens feared an injury to the brain, he took away twelve ounces of blood. When he examined the

ankle, he found the malleolus externus of the fibula projecting through the wound, but unbroken, the tibia dislocated and broken, and the foot very much turned inwards. He extended the foot, and thought that the bones had exactly returned into their natural situation; adhesive plaster was applied upon the wound, and its edges nicely adjusted. She was placed on a mattress with the limb upon the heel, and with a splint on each side of the leg. For seven days she complained of little pain, and had but slight constitutional disturbance; on the day week from the accident I was requested to see her, and finding little local or constitutional irritation, I recommended that the limb should not be disturbed, and the dressings were not removed.

On the 10th day from the accident, Mr. Stephens finding her in more pain examined the wound, and found that it had not adhered.

On the 12th day, a considerable discharge issued from the wound.

On the 16th day a slough had separated and exposed the bones, which appeared shattered and projecting. On this day I again saw her, and upon examining the ankle found the astragalus projecting, and a portion of it broken; and as the surrounding parts were dead I removed the projecting bone. Introducing my finger into the wound as soon as the astragalus had been separated, the tibia was found to be shattered, and the os calcis broken into many pieces. As her pulse was 100 and small, and her strength was failing, I immediately recommended her to submit to the operation of amputation; to which she consented.

On the Monday following, the stump was dressed by Mr. Stephens, and the greater part was adhering. Two of the ligatures separated on the 10th day, and the other came away on the 16th day.

September 29th. The stump was healed, excepting about the size of the section of a pea, and she had no complaint remaining excepting a sore upon her back, and pain in her left foot.

It is proper to mention that she hurt her spine and kidneys by the fall, so as to discharge urine tinged with blood for three weeks after the accident.

The other ankle also was most severely injured, and she suffered exceedingly from pain in it.

Upon examination of the amputated limb, the tibia was split up from the malleolus internus to the extent of three inches; the fibula was unbroken; the astragalus was broken and detached; and the os calcis was fractured into several pieces.

I have lately had another case of the same kind in which I was obliged to amputate.

(5.) *The Dislocation of the Tibia at the outer Ankle* produces much more injury and danger than that at the inner, and amputation will be more frequently required for it, because both the bones and soft parts suffer more than in the dislocation inwards.

(6.) *It sometimes happens that when the Bone is replaced it will not remain in its Situation, and all the Symptoms of the Injury become renewed.*—This circumstance arises when the tibia in the dislocation outwards is obliquely broken, and only a small portion of the articulating surface remaining on the dislocated extremity of the tibia, it will not rest on the tibia when it is reduced.

Mr. Andrews, of Stanmore, and Mr. Foote, of Edgeware, consulted me on the following case.

Case CLXXV.—Mr. Andrews and Mr. Foote were sent for on August the 9th, 1817, to the Hyde, six miles from London, to visit Charles Tomlin, a higgler, forty-eight years of age, who falling in a state of intoxication, the wheel of his cart passed over his left leg, and produced a protrusion of the bones through the integuments at the outer ankle. Mr. Andrews reduced the dislocation on the evening of the accident. On the same night Mr. Andrews and Mr. Foote having visited him again, found his pulse very quick, and spasms in the limb, which had again displaced the bone. They gave him a large dose of opium, and succeeded in reducing the bones.

On the 10th he had a very quick pulse, accompanied with strong spasms in the limb, but not sufficiently severe to displace the bone.

On the 11th, I was requested by Mr. Andrews and Mr. Foote, as I was going through the village, to stop and see this man; and as soon as the bandages were removed a violent spasm threw the bones from the astragalus, and all the efforts I could make would not replace them. Seeing therefore no hope of the man's recovering without the amputation of the limb, I immediately proposed it, and he readily gave his consent.

For three or four days he had a great deal of nervous irritation, which was most effectually relieved by occasional doses of opium and æther.

On the 18th the stump was inflamed, and in some parts sloughy; and on the 22nd it bled profusely.

On the 25th a poultice was applied; and from this time the appearance of the stump improved, and he proceeded without interruption in his recovery. In a month he returned to his home at Bushey, a distance of seven miles.

Upon examination of the limb I found the cellular membrane around the ankle loaded with extravasated blood; the ligamentum annulare tarsi was torn. The muscles were all remaining whole, though some of them, as the peronei, were much put upon the stretch. The fibula was broken one inch above the lower extremity of the malleolus externus, which remained in its place, still united by its ligaments to the tarsus. The tibia was split down from two inches above the joint, leaving the greater part of the articulating surface still resting upon the astragalus; but the remaining portion of the articulating surface, with the shaft of the tibia and the fibula, passed through the wound at the outer ankle. If, therefore, the bone had been again returned to its situation it could not have remained there, from the small portion of articulating surface attached to it; and if the projecting portion had been removed by the saw, it would not have adapted itself to the portion of the tibia which remained attached to the astragalus.

(7.) *The division of a large Blood-vessel, concomitant with an extensive Wound of the Integuments, might sometimes lead to a necessity for Amputation.*—But I should not, on that account, at once proceed to the operation. The case from Mr. Sandford, of

Worcester, sent me by Mr. Carden, (Case CLXXI.) clearly shows that the division of the anterior tibial artery does not, if it be well secured, prevent the patient's recovery. I also once saw a compound fracture close to the ankle-joint, accompanied by a division of that artery; yet, although the patient was in the hospital, and being a brewer's servant possessed the worst constitution to struggle against severe injuries, this man recovered without amputation.

The posterior tibial artery is a vessel of more importance, and is accompanied by a large nerve, which would not be likely to escape injury when the artery was divided by the dislocated bone. Yet the magnitude of the anterior tibial artery, and its free anastomosis with the posterior, would not entirely preclude the hope of preserving the foot under an injury of the posterior tibial artery.

(8.) *Mortification of the Foot* sometimes ensues, and becomes a sufficient reason for amputating the limb; but this must be generally done when limits appear to be set to the extension of the mortification. However, it may be observed, that in the mortification which ensued from the division of a blood-vessel, where the brachial artery had been divided, and the elbow-joint dislocated, I have seen the arm removed above the injured part, while the limb was still dying towards the seat of the wounded artery, and the patient was restored to health. And I have also known a case of popliteal aneurism, in which the artery and the surrounding parts were so compressed by the swelling, that mortification began at the foot, and was extending to the knee; and, although no limit was yet set to the mortification, the limb was amputated, and the patient recovered. So that mortification, when it arises from injury to a blood-vessel, or other local injury in a healthy constitution, admits of a practice different from that which is pursued in mortification arising from constitutional causes.

(9.) *Excessive Contusion may be another reason for Amputation.*— And, therefore, in those cases in which heavily laden carriages pass over joints, and bruise the integuments so as to occasion the formation of extensive slough, and produce at the same time, generally, the worst examples of compound dislocation, in regard to the state of the bones, I should immediately amputate; for such cases are very different from those which are caused by

jumping from a considerable height, from a carriage rapidly in motion, or by a fall in walking or running.

(10.) *Extensive Suppuration will also be a reason for Amputation.*—I have known, after an attempt to save the limb, the patient have more extensive suppuration than his constitution could support, followed by an ulceration of the ligaments, by which the joint became additionally exposed, and the bones were again displaced; hence there arose an absolute necessity to remove the limb for the preservation of his life.

(11.) *A necessity for Amputation may also be produced by Exfoliations of Portions of Bone,*—which, locked in the surrounding parts of the bone, are incapable of becoming separated, and thus keep up a state of continued irritation. My friend Mr. Hammick had the kindness to send me a specimen of this kind, which he was obliged to amputate. The loose portion of bone was seated between the lower extremity of the tibia and fibula, and reached to the ankle-joint; both the bones had been broken, and had become reunited, and the uniting medium had enclosed and incarcerated the dead black portion of bone. It is probable, from the appearance of the parts, that this portion of bone never would have been able to escape from the place in which it was locked.

(12.) *Excessive Deformity of the Foot* will also give rise to a necessity for amputation; and this deformity will take place in three directions: first, when the foot is suffered to turn outwards, whilst the leg is placed upon the heel, in the dislocation inwards; secondly, when it is turned inwards; and thirdly, when the foot remains pointed. The first is best opposed by placing the leg upon its outer side, when that is compatible with the treatment of the wound; in the second case it is best to keep the foot on the heel; and in both cases, splints, having a

foot-piece both on the inner and outer side of the foot, must be applied: the third requires similar splints, and a tape, as a stirrup, placed under the foot, and fastened to the splint on the fore and middle part of the leg to keep the foot supported; and the splints should be so padded as to preserve it in its proper direction.

The following case from Mr. Norman, of Bath, shows the necessity for amputation when great deformity is permitted to occur.

CASE CLXXVI.—I was sent for to Bradford, some years since, to amputate a leg directly after an accident of this kind. I found the lower extremity of the tibia, with the astragalus loosely attached to it, projecting at the inner ankle. The wound was not large, and the soft parts were little injured. I removed the astragalus, and reduced the tibia, leaving it to rest upon the os calcis. I did not again see my patient during the healing of the wound; I believe it got well without any severe symptoms; but the os calcis became drawn up against the posterior part of the tibia, to which it firmly united, and the foot became immovable, with the toe pointed downwards. In this state he came to Bath two years afterwards, when I amputated the leg, and the patient did well.

(13.) *Amputation has been recommended in those Cases in which Tetanus occurs after this Injury.*

CASE CLXXVII.—Of tetanus I have seen one case from compound dislocation of the ankle, and have heard of another. That which I saw was in a Mr. Yare, stable-keeper, who had a compound dislocation of the tibia inwards, and in whom I reduced the bones, and placed the limb on its outer side. For a few days he proceeded without any alarming symptoms. The only circumstance in which his case differed from what I expected was in the slight inflammation which succeeded upon the joint, for the restorative process seemed to be scarcely established in him. When I paid him my morning visit, several days after the accident, he said, "Sir, I believe I have caught cold, for my neck is stiff;" and as he said this, with his lower jaw raised and his teeth closed, I begged him to show me his tongue, to ascertain if the jaw was locked; and he tried to open his mouth, but was unable to do so. I then desired that Dr. Relph might see him, who did all that his

mind could suggest to arrest the progress of the symptoms, but unsuccessfully, as the different muscles of volition became affected in the back, the extremities, and the abdomen, until he was exhausted by irritation. To amputate under such circumstances would be most unjustifiable, as far as the experience of cases in this climate will enable me to form an opinion. I have not seen amputation performed for compound dislocation of the ankle, but I have seen it performed for compound fracture just above the joint, and it seemed to me to precipitate the fatal event. I have also known, in one case, the finger amputated for tetanus arising from injury to it, yet the patient died; and I have also heard of a third case in which it was practised, but still the issue was fatal. There is a species of *chronic tetanus*, which sometimes even succeeds wounds, and which will occasionally subside, and the patient recovers, although, apparently, little be done by medicine, and nothing by surgery; in such cases it would not be justifiable to amputate. If any medicine be efficacious, submurias hydrargyri, with opium, is that under which I have seen the majority of these cases recover; and opium should also be applied to the wound.

(14.) *A very irritable State of Constitution* will sometimes render all treatment unavailing to save the limb, and will now and then prove destructive, even if the operation be performed. There are some persons originally constituted with so irritable a system, that the slightest injuries will destroy them. There is a much greater number whose constitutions, originally good, have been so much injured by excess, by want of exercise, by over-exertion of mind, by drinking freely of spirits and eating but little, that to them the slightest accidents prove fatal.

Case CLXXVIII.—One of the most curious examples of this kind which I have seen was in a man who worked at Barclay's brewhouse, in the Borough. The circumstances were these.

On Saturday he was turning a cask, and a splinter of wood entered his thumb, which he immediately drew out.

On Sunday night he requested his wife to rise and make him a poultice; for his thumb, he said, was painful.

On Monday he sent for Mr. John Kent, surgeon in the Borough, who found his thumb inflamed and painful.

On Tuesday the inflammation had extended to the hand and fingers.

On Wednesday a swelling appeared at the wrist, above the ligamentum carpi annulare, and the man had a great deal of irritative fever, and was obliged to keep his bed.

On Thursday, after lecture, Mr. Kent came to me, requesting I would see this man, who had been delirious during the night; his arm being much convulsed, and his body becoming generally so. I went with Mr. Kent, and feeling the thumb, discovered a fluctuation in the theca. I put a lancet into the extremity of the thumb, and a considerable quantity of pus issued. Gratified with the expectation of his being relieved by the discharge of the matter, I was going out of the room to express this feeling to his friends, when I heard a rustling on the bed behind me; and upon Mr. Kent and myself turning back, we saw him under the influence of a convulsive fit, which raised him in his bed, and in which he fell back and expired.

Living as these persons generally do, principally upon porter and spirits, they have constitutions which render them the worst subjects for accidents.

The following case shows the violent symptoms and quick dissolution which will, from the same cause, occasionally ensue in compound dislocation of the ankle.

Case CLXXIX.—On June the 10th, 1809, I was requested to go immediately to Gracechurch Street, to see a Mr. Fenner, who, in walking opposite to the City of London Tavern, had slipped from the foot-way, which produced a compound dislocation of the ankle. The tibia projected at the inner ankle; the fibula was broken, and the skin was tucked in under the extremity of the tibia.

First: I immediately procured a mattress for him, instead of a feather bed.

Secondly: A many-tailed bandage; splints lined with wool; and pillows and tapes.

Thirdly: The skin was divided, and the bone reduced; but it was much opposed by violent spasm of the muscles.

Fourthly: The edges of the wound were closely adjusted.

Fifthly: The bandage and splints were applied, and the limb was placed upon pillows on its outer side, with the knee bent.

Sixthly: Bled to 14℥, and opium given; tinct. opii gtt. xxx.

June 11th. His night had been restless; his tongue was white; his pulse beat 110 strokes in a minute; he had violent

pains in the ankle, and had vomited. Ordered oleum ricini, as his bowels had not been relieved. Evening: he had almost constant spasms of the muscles of the leg; he had not slept, and had no appetite. The oleum ricini had produced four evacuations.

June 12th. His pulse was 120: his tongue more furred. He had violent and very frequent spasms. He had nausea, but had not vomited since the last report. He had had one evacuation. Blood was extravasated about the ankle, and a sanious serum was discharged from the wound. Ordered opium.

June 13th. Had slept three hours. There was some inflammation about the wound, and swelling of the leg, with spasms, but they were less violent than yesterday. A poultice was applied to the ankle, and fomentations ordered. Pulse 120: his tongue was very much furred. Evening: in most violent pain; he was ordered submurias hydrargyri five grains, with two grains of opium, and the saline medicine with antimony.

June 14th. The spasms continued, but the pain had in a great degree ceased. He had had several evacuations, but had been delirious during the night. The limb was but little swollen; the foot appeared slightly inflamed, but there was no healthy discharge, nor any granulations beginning to form. The former treatment was ordered to be continued.

June 15th. He had passed a bad night, being delirious through a great part of it. He had a violent spasm in the limb this morning, which produced a slight hæmorrhage, which was stopped by pressure. His leg was swollen, and the wound appeared to be without action. His pulse was equally quick, and he took no nutriment.

June 16th. He had spasms in the thigh of the same side, and in the other leg, as much as in the injured limb: in other respects he remained the same.

June 17th. He was delirious during the previous night, and bleeding was again produced by the violence of the spasms. His pulse was considerably quicker than before.

June 18th. He died at four o'clock in the afternoon.

Persons who are much *loaded with adeps* are generally very irritable, and bear important accidents very ill; indeed they frequently perish, whatever plan of treatment be pursued: to this statement, however, there are exceptions in those who, though

corpulent, are still in the habit of taking much exercise, as they will retain some vigour of constitution; and in such persons the limb may be attempted to be saved, as in the case described by Mr. Abbott, surgeon at Needham Market; but in those who have become extremely fat, and who have been addicted to habits of indolence, there is but little chance of preserving life but by amputation.

Having thus endeavoured to explain what has fallen under my own observation, and what I have been able to learn from others upon this difficult subject, I beg leave to express a hope that any of my friends who may have had cases under their care which would throw further light upon the subject, will have the kindness to communicate them to me, whether they make for or against the advice that I have given, as I have no further wish but that all the points respecting this severe accident may be fully elucidated and established; and shall only add, that the observations which I have made in favour of saving the limb in compound dislocations of the ankle-joint, will apply much more strongly in country practice than in that of the large hospitals in London.

DISLOCATION OF THE ANKLE FROM ULCERATION.

Case CLXXX.—Sept. 23rd, 1823. With Mr. Dixon, surgeon, of Kennington, I visited Mr. P., a patient of his, who had a dislocation of the ankle produced by ulceration. An ulcer existed at the inner ankle, which had discharged synovia. The ankle-joint was red and greatly swollen, the foot drawn outwards by the action of muscles, and the internal malleolus thrown inwards upon the astragalus. The tibial arteries were greatly stretched; and the fibula, by its pressure on the malleolus externus, produced considerable and constant pain. Mr. P. is a very old man, and dying of the disease.

The following case illustrates another occasional cause for amputation.

Case CLXXXI. — Francis Lanigan, a very muscular man, aged fifty-three, was brought into St. Bartholomew's Hospital on the evening of the 27th April, having received severe injury in his right leg whilst in a state of intoxication. The limb presented the following appearances:—The heel rather raised, the sole of the foot turned slightly outwards, and the internal malleolus

projected inwards and forwards. On examination, it was found that the internal lateral ligament was lacerated, and that the tibia was completely luxated; the fibula was also found to be fractured about two inches above the joint: no fracture of the tibia could be detected. The patient being placed on his right side in bed, extension was made, and the foot brought into its proper position; the limb was then placed between two splints, the upper one extending only about two-thirds down the leg, so as to admit of the application of twelve leeches, and cold lotion after the bleeding had ceased.

28th. He has passed a restless night, and complains of having suffered much from the cramp, to which he states he is very subject; the foot was again completely thrown out of position by the violent action of the muscles during the night; there was great difficulty in reducing it again, in consequence of the very irritable state of the muscles; the limb was now placed between two common splints, extending from the knee to the foot. Some constitutional excitement. Bled from the arm to ℥xvi. and ordered calomel gr. iii., pulv. jalapæ gr. xviii., to be taken immediately.

At the usual hour Mr. Earle visited the patient, and wishing to see the position of the limb, the upper splint was very carefully raised; but, immediately on the pressure being taken off, the dislocation was violently reproduced by the spasmodic contraction of the muscles. But little difficulty was now experienced in reducing it, and the splints were immediately replaced. Træ. opii gtt. xxxv. h. s.

May 1st. He has been rather restless during the night; and complains a little of pain from the tightness of the splints; the inflammation and swelling have extended a little upwards; tongue rather furred; pulse full. At noon Mr. Earle saw the patient, and let out a small collection of matter in front of the ankle by a free incision. Ordered hyd. submur. gr. v., ant. tart. gr. ss. statim. A large bread and water poultice to be applied.

4th. Complains of pain about the inner ankle; more pus evacuated from the neighbourhood of the internal malleolus by free incisions, and from the outer side over the fracture in the fibula. The patient was now placed on his back, with the limb in a fracture-box, to facilitate the flow of matter. The poultice was again applied.

5th. He has had a very restless night, and in a fit of delirium made some violent attempts to turn in bed, and to extract his leg from the box, by which the foot has again been displaced and the tibia thrust through the integuments, which are now in such a sloughy and lacerated state as to render it impossible to retain the parts in a proper position.

Mr. Earle, on seeing the patient at noon, advised immediate amputation, which was also recommended by Messrs. Vincent and Lawrence, whom Mr. E. requested to see the patient. To this the patient objected. His general health does not seem to suffer from the increased extent of mischief. The poultice ordered to be continued. Træ. opii ʒ ss. h. s.

6th. He has had a pretty good night, and is now tolerably easy. The limb presents much the same appearance as last night.

At noon, the man still refusing to part with his leg, Mr. Earle ordered him to be placed upon one of his bedsteads, when he succeeded in securing perfect quietude of the limb, by binding the foot tightly to the footboard and applying the nine-tailed bandage. The dressing could now be applied without the slightest risk.

Evening. States that since his removal he has been easier than at any period since the accident. Ordered tr. opii. m. xl. h. s. s.

11th. Health much the same; but the discharge not having quite so healthy an appearance, a week solution of the nitrate of silver was ordered to be applied on lint under the poultice.

12th. Ordered sulph. quininæ gr. ii. bis die.

14th. The quina was omitted yesterday in consequence of diarrhœa. Pulse rather weaker. Ordered tr. camp. compositæ fʒi.; infus. cascarillæ ℥iss. bis die; vini rubri ℔ss; sago, &c. daily; pulv. ipecac. c. gr. x. h. s.

The man consents to lose the limb on Saturday (day after to-morrow), being the usual operating day.

16th. The patient was conveyed to the theatre, when the operation was performed in the usual manner. Cold cloths were ordered to be kept constantly applied to the stump, and Mr. Earle, before leaving the hospital, requested that the patient might be well watched, as he thought in all probability there would be some hæmorrhage. At half-past four o'clock, P.M. there having been a slight oozing of blood for some time, the

stump was opened, when a good deal of coagulated blood was removed, and two large muscular branches secured; it was now kept open until all fear of hæmorrhage had ceased. The patient complained of no pain. Continue the cold application.

17th. Has had no refreshing sleep, though he dosed a great deal during the night, talking incoherently. The stump looks well, though rather dark coloured. The bowels have not acted since the operation, and there is some enlargement about the region of the stomach. The pulse is rather weaker, the tongue dry and brown. At noon Mr. Earle saw the patient, and ordered, calomel, gr. iii., opii gr. i., statim. s., and an effervescing draught of carbonate of ammonia and lemon-juice, every six hours.

Evening. Does not complain of any pain. Ordered to take brandy and water ad libitum.

18th. The external part of the stump presents a gangrenous appearance. Ordered a large fermenting poultice with yeast.

20th. The stimulants were continued; but he died at half-past two this morning.

On the Tuesday morning following the operation the leg was examined in the presence of Mr. Earle and several of the pupils. The whole of the anterior and internal part of the capsule was lacerated, as was also the internal lateral ligament; the posterior inferior edge of the extremity of the tibia (within the capsule) was broken off. This not having been generally described is probably rare, and may, no doubt, in some degree account for the frequent luxations which took place, and for the great difficulty experienced in retaining the parts in situ. In the fibula there was an oblique fracture, about an inch and a half or two inches above the joint. The portion of integument in front of the leg, which had a bruised appearance, and required to be dissected back, was the part which became gangrenous; and it was remarked, that the minute injection had not passed into the corresponding portion of the integument of the amputated leg. The condensation which had taken place, in consequence of inflammation, Mr. Earle considered might have diminished the vascularity of the part.

Post-mortem examination.—About thirteen hours after death the body was examined, when there was found to be no extension of inflammation or gangrene in the stump. The mucous

membrane of the air passages was slightly inflamed, and there was an ulcer in the larynx, at the base of the arytænoid cartilages. Nothing else was found apparently connected with the patient's death.

The patient had, since his admission into the hospital and for some time previous, been troubled with a constant cough, which, after the accident, proved a source of great distress; his voice was thick and latterly almost unintelligible; for this the morbid appearances in the vocal organs amply account.*

The following case of displacement of the foot upwards, in which neither the tibia nor the fibula were fractured, was communicated to the Editor by Mr. Luke.

Case CLXXXII.—A street musician, aged thirty-four, the subject of the above accident, was admitted under my care into the London Hospital, March 22nd, 1836. He stated that on the preceding evening, in endeavouring to get out of the way of a cabriolet, he fell to the ground on his side, while his foot remained fixed in a hole of the pavement. Fainting from extreme pain, he was removed in an insensible state to a neighbouring public-house. On the succeeding morning, when he was brought to the hospital, the foot and ankle were very greatly swollen. There was therefore little manual examination made of the part, but it was raised on an inclined plane, and bathed with an evaporating lotion. When it came under my observation, I was informed that the swelling was diminished: it still, however, existed to a very great extent. The foot was manifestly displaced from its natural relations with the tibia in a direction outwards, but had not sustained any inclination of its plane, nor depression of either of its edges, as is usual in common lateral dislocations. The malleoli were separated widely from each other, producing an unnatural appearance of breadth to this part of the leg. The fibula was found to be entire. It was ascertained by measurement that the distance from the lower edge of the patella to the sole of the foot was less by one inch on the injured than on the uninjured side.

The conclusions which I drew from the foregoing appearances were, that the tibio-fibular and interosseous ligaments had been lacerated, and the tibia and fibula thrust asunder by the astra-

* Lond. Med. Gaz. vol. iv. p. 61.

galus becoming wedged between them, while the plane of the foot had retained its accustomed horizontal position.

The reduction was accomplished without much difficulty, by first relaxing the muscles of the calf, and by applying the extending force by means of a loop of bandage carried over the instep and around the heel. After reduction a considerable disposition to a recurrence of the dislocation was evinced, but effectually counteracted by encircling the lower part of the leg a few times with a bandage, so as to preserve the tibia and fibula in contact with each other by a temporary substitute for the tibio-fibular ligaments during their reunion. Under common treatment the patient made a good recovery of the use of the ankle.

SECTION VI.

FRACTURE OF THE FIBULA NEAR THE ANKLE-JOINT.

SYMPTOMS.— The *fibula* is frequently broken from two to three inches above the ankle-joint, and the patient instantly becomes conscious of the accident by feeling a snap a little above the outer ankle; by the pain which he suffers in his attempt to bear upon the foot; by his inability to place his foot flat upon the ground, resting it rather on the inner side to throw the bearing of the body upon the tibia; and by pain and a sensation of motion at the injured part when the foot is bent or extended. The surgeon discovers the nature of the accident by rotating the foot with one hand, and by grasping the lower part of the leg with the other; at each rotation a crepitus is generally felt. There is also frequently an inequality of the bone at the broken part, which assists in pointing out the nature of the injury.

CAUSE.—The cause of this injury is a blow upon the inner side of the foot, or some violence which forces it outwards against the lower extremity of the fibula; and I have known it broken by distortion of the foot inwards. A fall laterally, whilst the foot is confined in a deep cleft, also produces this accident. I broke my right fibula by falling on my right side

whilst my right foot was confined between two pieces of ice, and I could with difficulty support myself to a neighbouring house by bearing upon the inner side of my foot. I went home in a carriage, and every jolt of it gave me pain at the fractured part as I suspended my leg upon my hand. I knew that the bone was broken by the severe snap which I felt in the part at the moment of the accident.

Treatment.—The treatment which this injury requires is, to apply a many-tailed bandage upon the limb, and to keep it wet with a lotion of spirit of wine and water; to apply a splint, with a foot-piece on each side, padded with cushions in such a manner as to preserve the great toe in a line with the patella, (an invariable rule on these occasions,) and to place the leg upon its side in the semiflexed position, so as to relax the muscles, and render the patient's position as easy as possible.

A want of attention to the treatment of this accident leads to permanent lameness. Dr. Blair, a naval physician in the American war, informed me that he found great difficulty in walking the streets of London on one side of the way, but upon the other he walked better than on flat ground; and when I remarked his lameness, and inquired into its cause, he informed me it had arisen from a fracture of the fibula, which happened many years ago, and to which not having applied splints, the foot became twisted, so that he walked better upon an inclined plane than upon flat ground.

SECTION VII.

FRACTURES OF THE TIBIA AT THE ANKLE-JOINT.

The tibia is often broken into the ankle-joint, or through the bone a little above it; and these fractures may pass either obliquely inwards, or obliquely outwards: the first in a line from the usual seat of fracture of the fibula, that is, from one to two inches above the external malleolus to the inner ankle; the second from one to two inches of the tibia above the ankle, downwards and outwards into the joint.

DIAGNOSIS.—The first is distinguished by crepitus at the ankle when the foot is rotated, bent, or extended; and by a slight inclination of the foot outwards. If the fracture does not enter the joint, but obliquely crosses the tibia above it, the lower part of the tibia slightly projects over the malleolus internus.

The treatment in this case consists in using evaporating lotions; the many-tailed bandage; and splints with a foot-piece to each, padded so as to incline the foot inwards, and to bring the toe into its natural line with the patella, which is easily effected with the splints to which I have alluded.

CASE CLXXXIII.—James Aire, aged thirty, fell, while intoxicated, from the top of a house; he walked a short distance, and was then brought to the hospital. The tibia was found to be broken very obliquely inwards about an inch and half above the joint; the fibula near its centre. When laid on the bed the appearances were, unusual projection and fulness of the *outer* malleolus, inclination of the foot *inwards*, a sinking and unnatural roundness above the joint, with a point of bone projecting and nearly perforating the skin. He also had a compound fracture of the jaw. He died on the fifth day from gangrenous inflammation of the leg.

The symptoms of the oblique fracture of the tibia downwards and outwards into the joint are, as in the former case, a crepitus upon rotation, flexion, and extension; but the foot is slightly inclined inwards, and the malleolus externus projects more than it naturally would. The same bandages and splints are to be used as in the former case; and the position in both these accidents should be as follows.

The leg should be raised so as to bend and elevate the knee; and the limb should rest upon the gastrocnemius muscle, and upon the heel. The splints will support the foot on each side, and the leg should be supported by a pillow, reaching from the knee to beyond the foot, secured by tapes around it. I have seen both these cases do well when the patient and his leg rested upon the outer side; but the advantage of placing the limb upon the heel is, that it gives the surgeon an opportunity of observing the least deviation in the line of the foot, relatively to the axis of the leg; and this is also an easier position to the patient.

The outer portion of the lower extremity of the tibia, at the part at which it joins the fibula, is sometimes fractured and

split off from the shaft of the bone in jumping from a considerable height; the foot then rises between the tibia and fibula; a dislocation of the tibia inwards is produced, and the foot is elevated between the two malleoli. The treatment required in this case is the same as in the dislocation inwards.

Oblique compound fractures into the ankle-joint generally do well if care be taken to produce adhesion of the wound, which is to be effected by applying lint, embued in blood, to the lacerated skin, and by leaving it there until it separates spontaneously. The same bandages and splints are required as in simple fractures, but the position must be varied according to the situation of the wound. Even if suppuration occurs the patient will generally recover, unless he be much advanced in years.

But if, with compound fracture into the joint, there be much comminution of bone, and hæmorrhagy from any large vessel, it will be proper to amputate immediately, more especially if the patient be obliged to obtain his bread by his labour; for after recovery, under great comminution, the limb will bear but slight exertion.

Case CLXXXIV.—Jane Moore was admitted a patient of Guy's Hospital, July 10th, 1822. She states, that she slipped off the curb-stone into a hole, where the pitching of the street had been taken up, by which means her ankle was forcibly twisted under her. The appearances of the foot were as follow:—The outer edge was depressed and turned inwards, the heel appeared to project, and a part of the dorsum of the foot was lost. Upon examination the fibula was found to be broken about an inch and half above the outer malleolus; a fracture also extended obliquely upwards in the tibia, separating the internal malleolus and articulating surface from the shaft of the bone, and this portion was thrown forwards on the metatarsus, and at the same time partially inwards. The fracture was reduced by pressing on the lower and fore part of the tibia, at the same time as extension was made by depressing the toes and by the os calcis: this extension had not been long continued before the part was replaced. As the tumefaction of the parts was not considerable, the extent and nature of the injury could be readily and clearly ascertained. The leg was afterwards placed on the outer side, cold lotions applied for two days, and the limb is now done up in one of Mr. Amesbury's splints.

Dislocation of the Tendon of the Peronæus.—Whilst on the subject of injuries to the ankle-joint, it will be as well to allude to a displacement which sometimes occurs, and which might be confounded with a severe sprain. I have already spoken of a supposed displacement of the lower edge of the glutæus, and shall hereafter speak of dislocation of the long head of the biceps from its groove; and the accident of this kind to which I allude at present, is dislocation of the tendon of the peronæus from its groove in the fibula. I was consulted about the following case by Mr. Sankey, of Dover, in the year 1838.

Case CLXXXV.—In June, 1837, says Mr. Sankey, I was called upon to attend Miss H., who had been nearly thrown from her horse, and had severely sprained her ankle. Upon examination I discovered a very unusual circumstance, viz. dislocation of the tendon of the peronæus longus from its sheath. I applied for some weeks compresses and bandages; and when she went from this place everything appeared going on favourably; but Mr. Heming writes me that she still suffers inconvenience, and requested I would give you a description of the injury.

I recommended one of Shoolbred's laced stockings.

CHAPTER VIII.

DISLOCATIONS OF THE FOOT.

Dislocations of the Astragalus.—The astragalus is connected above and on each side with the tibia and fibula; below, it has articulating surfaces for its junction with the os calcis, to which it is united by means of a capsular and strong interosseous band of ligament; and anteriorly it is articulated to the os naviculare, by a capsular and internal lateral ligament. A simple dislocation of the astragalus sometimes, though rarely, occurs; a compound dislocation is still more rare.

A simple luxation of the astragalus is a most serious accident, being very difficult to reduce; and should the reduction not be effected, the patient is ever after doomed to a considerable degree of lameness.

Case CLXXXVI. — Being sent for into the country to visit a patient, the surgeon, Mr. James, of Croydon, whom I met there, requested me to see a gentleman who had a dislocation of the foot, which had happened several weeks before, but had not proceeded to his satisfaction. Upon examination, I found the astragalus dislocated outwards, and the tibia broken obliquely at the inner malleolus. Every attempt to reduce it was made which Mr. James, who is an extremely well-informed man, could adopt; five persons kept up a continued extension when

the accident first happened, but without effect; the patient was then taken home, and several persons were employed in extending the foot, and it was thought, after a time, with some success; but the reduction could not, by all their efforts, be rendered complete, as the astragalus still remained projecting upon the upper and outer part of the foot. The extension could not be carried further; the integuments sloughed from that which had been already made: and the wound was a long time in healing. The limb now deviates much from its natural shape; the toes are turned inwards and pointed downwards; there is some little motion at the ankle, and only a slight degree of it between the projecting and raised astragalus, and the other bones of the tarsus.

This accident, then, is of a most serious nature; for the gentleman in question had placed himself under the care of a most intelligent and persevering surgeon, and yet the attempts which he made at reduction were not successful; merely from the nature of the accident, and not from any fault in the means which were pursued. In these cases the use of pulleys will be required, and the action of the muscles should be lessened by tartarized antimony.

I attended the following case with my friends, Mr. West, surgeon of Hammersmith, and Mr. Ireland, surgeon, in Hart Street, Bloomsbury. It is highly interesting and instructive, and shows most clearly the necessity that surgeons should be upon their guard in amputating limbs, and in performing operations, as the resources of nature are sufficient, under very formidable circumstances, to effect restoration.

Case CLXXXVII.—On July the 24th, 1820, Mr. Downes had the misfortune to dislocate the astragalus, by falling from his horse. The accident happened at Kensal Green, about six miles from London; and Mr. West, surgeon, at Hammersmith, who was called in to him, made an attempt to reduce the dislocation, which could not be effected. The patient was largely bled; the limb was placed in splints; Goulard's lotion was applied, and an anodyne given. The patient felt great pain, and a sense of pressure against the skin and ligaments, on the evening of the accident. A purge was directed to be given, and anodynes occasionally in saline draughts.

On the following day, the 25th, Mr. Ireland, who had visited

Mr. Downes the evening before, called upon me and requested me to accompany him to see the patient, and to meet Mr. West. When I examined the limb I found the astragalus dislocated forwards and inwards; and the fibula appeared to be broken a little above the joint. I made an attempt to reduce it, but found the bone immovably fixed in its new situation, projecting so as to make the nature of the case perfectly clear, and bearing so strongly against the skin that a slight incision would have exposed it. My first impression was, that I ought to dissect away the astragalus; but aware of the resources of nature in accommodating parts under luxations, and in restoring the limb to usefulness, I observed to Mr. West, and to Mr. Ireland, that I would not operate, and that perhaps the skin might give way, and the bone become exposed, when we should be justified in removing it. The previous treatment was continued.

On the 26th he had some irritative fever, when the saline medicine with antimony was given.

On the 28th there was considerable local irritation, and leeches were applied.

On the 29th the leeches were repeated and the lotion continued.

On August the 10th the skin began to be disposed to slough, opposite the projection of the astragalus at the inner ankle.

On the 14th, fomentations and a yeast poultice were directed to be applied, and bark and wine were given.

On the 16th the skin sloughed.

On the 20th there was a great discharge of pus, and the astragalus became exposed. The same means were continued; and

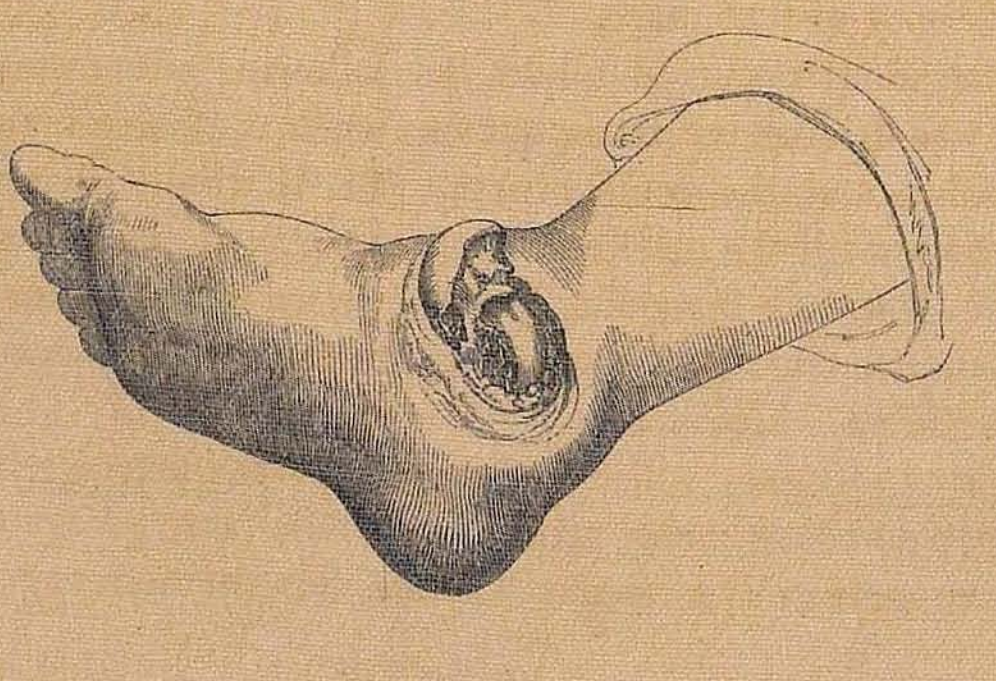

the inflammation and discharge gradually lessening, the wound was dressed with lint and adhesive plaster.

The astragalus gradually became dislodged; the ligament sloughing or ulcerating. In September, the patient was able to be removed to London.

On October the 5th, 1820, I again saw him, and finding the astragalus very loose, removed it with forceps, dividing only some slight ligamentous adhesions. The bleeding was trifling, and was suppressed by the application of lint alone.

In December some slight exfoliations occurred, which produced pain and inflammation; but at the end of the month he began to walk.

After the astragalus was removed, soap plaster was applied; and Mr. Downes gradually recovered his strength, and was able to walk without the aid of a stick.

In October, 1821, he had a slight motion at the ankle, which has been gradually increasing.

Simple Dislocation of the Astragalus Backwards.—The two following cases of this accident are worthy of notice. They were published by Mr. B. Phillips in the Medical Gazette, vol. xiv. p. 596.

Within the last three years, says Mr. Phillips, I have been twice consulted about an accident which is at present scarcely known: a complete dislocation backward of the astragalus, without any other change in the relative position of the other bones, or external injury to the integuments.

Case CLXXXVIII.—The first case on which I was consulted was that of Mr. Goss, a merchant at Bristol. I saw this case in consultation with his usual attendant, Mr. R. Smith, surgeon of the Infirmary of that place.

The accident occurred under the following circumstances:—Mr. G. was driving out in a phäeton, when the horse became unmanageable, and the reins broke. Mr. G. threw himself from the carriage with the intention of stopping the horse; he alighted upon his feet, but immediately fell forward to the ground. He was brought home; and in about two hours from the occurrence of the accident I saw him.

The kind of injury which had occurred was immediately apparent by the remarkable projection which was presented just above the heel. The tendo Achillis was pressed out by the

displaced astragalus, so as to form an angle of forty degrees, and at one point the bone had reached so near to the surface that vesication was produced directly over it. The anterior part of the foot appeared shortened; and a projection was presented anteriorly by the inferior extremity of the tibia. There was very little ecchymosis; and it was not at all evident upon what portion of the foot he had rested on coming to the ground. As he fell forward upon reaching the ground, it appeared probable that the foot was suddenly and forcibly flexed; and this is the more probable, because in that movement the anterior border of the articular surface of the tibia meets the neck of the astragalus, which arrests the movement of flexion before it has proceeded far enough to produce luxation of the foot upon the leg. If the place upon which he rested was, as is probable, the side of a bank, the accident would appear as much more likely to occur, for in that case the axis of the tibia is oblique in relation to the articular surface of the astragalus, in front of which it is precipitated in obedience to the impulsion which it receives from the weight of the body.

Before the reduction was attempted, the patient was bled to twenty ounces, and was nauseated by tartar emetic, the effect of which was maintained for an hour, during which the efforts to reduce the bone were sustained.

These efforts were unsuccessful; and therefore only one of two modes of proceeding remained for our choice:—to leave things in their present state, merely combating any untoward symptoms which might occur, or to extract the astragalus. Having in my recollection three cases in which the dislocation forwards of the astragalus had occurred, in which a long and painful operation had been attempted for its removal, in which a long convalescence had followed, and in which permanent lameness had been the consequence, I declined to accede to this proposition. Leeches in considerable number were applied around the injured part, the bowels were carefully regulated; no bad symptom occurred; a new articulation was formed between the bones of the leg and the os calcis; little inconvenience was occasioned by the astragalus: and when I last heard of him, the patient walked nearly upright.

Case CLXXXIX.—The second case upon which I was consulted occurred during the last summer. A gentleman, aged

thirty-two, was occupied in playing cricket. While fielding, and running very rapidly after the ball, a gutter which was in his course was not observed. The toes rested upon the further side of this gutter, while the heel was jammed directly into it, and he fell forward. He was unable to rest upon the injured leg, and it was evident to the bystanders that a displacement had occurred. I was not summoned till the following day, when the leg presented an appearance very similar to that which I have described in the former case, except that there was more ecchymosis about the external malleolus. Some inconsiderable attempts at reduction were made on the previous evening. He was bled to the extent of twenty ounces, and twenty leeches had been applied to the injured part. In this case I declined to make any further attempts at reduction, or to remove the displaced bone.

It was necessary from time to time, during the first three weeks, to apply leeches to the part, and to keep the leg motionless, for the purpose of keeping down the inflammation with which he was threatened.

The accident occurred in August; the first week in November he was able, with the aid of a stick, to walk a short distance; and on the 1st of January scarcely any lameness remained. Considerable power of motion was already produced in the new articulation; and the only inconvenience of which he has complained is the necessity which has been imposed upon him for the present of wearing a low-heeled shoe, which does not come into contact with the projecting astragalus.

The appearance of the limb in these two cases was very similar. The astragalus had passed backward from the mortise which is formed for it by the tibia and the fibula. There was elongation of the heel, a projection of the tendo Achillis, a shortening of the anterior portion of the foot; and an anterior projection upon the dorsum, formed by the inferior extremity of the tibia. The projection had interposed between it and the dorsum a transverse fold of integument; and as the tumefaction lessened, the form of the astragalus was distinctly marked between the tibia and the tendo Achillis: there was also immobility of the foot.

That a reduction of this bone, when it has completely escaped backward, can rarely, if ever, be effected, appears to be certain. For the purposes of this consideration we may almost compare

the astragalus to a wedge, the base of which is presented towards the tibio-tarsal articulation; and I can scarcely conceive it possible to separate the os calcis from the tibia to a sufficient distance to allow of the admission of the astragalus. If this reasoning be correct, it will be useless to torture the patients with attempts at reduction. If, however, the bone be not completely removed from between the os calcis and the tibia, — that is, if only a partial dislocation occur; or, if the displacement be forward, when the apex of the wedge will be presented towards the joint,—we ought to employ such means as appear best adapted for reducing it. All that can, therefore, remain for us, in complete dislocation of this bone, is, I apprehend, either to extract it, making by this means a communication between the cavity of the joint and the exterior, or to suffer it to remain in its new resting-place, as was done in the foregoing cases.

COMPOUND DISLOCATION OF THE ASTRAGALUS.

Case CXC. — In the first case of this accident which I had an opportunity of witnessing, the astragalus was thrown inwards and forwards upon the os naviculare; and when I afterwards saw the limb upon the table of the dissecting-room, it having been removed by amputation, I exclaimed, "Surely that limb might have been saved."

Case CXCI.—In the case of which an account was sent me by Dr. Lynn, of Bury St. Edmunds, it will be seen that the discharge of the astragalus, in a compound dislocation of the ankle-joint, did not prevent the patient's recovery; for he says, "In five weeks a portion of the astragalus separated, and another piece a week afterwards, which, when joined, formed the ball of that bone."

Case CXCII.—Mr. Trye, of Gloucester, had also under his care a case of compound luxation of the astragalus, in which he cut out the luxated bone, and the patient had a good recovery, with a tolerably useful foot.

The following case was under the care of Mr. Henry Cline, in St. Thomas's Hospital.

Case CXCIII.—Martin Bentley, æt. thirty, was admitted into St. Thomas's Hospital, 21st of June, 1815. Some heavy stones had fallen upon him, and had caused a compound fracture of the left leg, and a dislocation of the right astragalus from the other bones of the tarsus.

The appearances presented by the right foot were as follow. The whole foot seemed to be somewhat displaced outwards; the os calcis projected much beyond the outer ankle, the prominence of which was nearly lost; there was a remarkable depression below the outer ankle, between it and the displaced os calcis, whilst there was an equally remarkable projection below the inner ankle, produced by the dislocated astragalus. It thus appears that the astragalus was dislocated inwards from the navicular bone and os calcis, so as to have its inferior articulating surfaces resting on the inner edge of the os calcis.

The left leg was amputated below the knee; and after that operation the dislocation was reduced by fixing the knee, having the thigh bent at right angles with the body; then laying hold of the metatarsus and protuberance of the os calcis, and drawing the foot gently and directly from the leg. During this extension, Mr. H. Cline put his knee against the outside of the joint, and the foot being pressed against it, the os calcis and navicular bones slipped into their place, carrying with them the rest of the foot; and the deformity disappeared. The patient was then carried to bed, and an outside splint was applied, being well padded, and secured by tapes; and the leg, as far as could be, placed on the outer side.

This patient recovered without much difficulty. He was able to walk in the hospital square on the 7th of August, and was discharged, cured, on the 27th of the same month.

Case CXCIV. — Mr. J. H. Green gave me the particulars of a case of compound luxation of the tarsal bones, which was admitted into the hospital under the care of Mr. Henry Cline; in which the astragalus was thrown outwards; or, in other words, the other tarsal bones were dislocated inwards from it. The foot was turned considerably inwards; the articular surface on the head of the astragalus, which is received into the cup of the navicular bone, was exposed through an extensive, but tolerably clean, cut through the integuments; and the articulating surface of the os calcis, with the astragalus, might also be perceived on the outer side. The accident was said to have been occasioned by the fall of a heavy stone, which had struck the patient's heel. Reduction of the dislocated parts was accomplished, first, by bending the leg so as to relax the muscles, and then by extend-

ing the foot in the manner described in the former case, rotating it at the same time outwards.

The patient was a robust, but not corpulent, labouring man, between forty and fifty years of age. He stated that he had been in the habit of drinking, and that he was occasionally subject to gout.

His recovery was retarded by extensive erisypelatous inflammation, which terminated in sloughing, and by the formation of matter at the part, accompanied by irritative fever and loss of strength; but his recovery, although tedious, was complete.

For the following case I am also indebted to Mr. Green, whom I am proud to call my colleague, and who is an admirable anatomist, an excellent surgeon, and an amiable man.

Case CXCV. — Thomas Toms, twenty-three years of age, was admitted into St. Thomas's Hospital on July the 14th, 1820. He had fallen, whilst engaged in his business, that of a bricklayer, from a three-story scaffold; and his descent had been arrested by his foot catching between the spikes of an iron railing, from which he hung with his head nearly touching the ground. A wound was found extending beneath the inner malleolus of the left leg; and the head of the astragalus, which was torn from the articulatory surface of the os naviculare, protruded through the divided integuments. Part of the articulatory cartilage of the displaced bone had been separated, and the bone was girt by the edges of the wounded skin, which was puckered under it. The tendons of the tibialis anticus and of the flexor muscles were tightly stretched, and the foot was turned rather upwards and outwards. Further examination showed that the posterior tibial artery was torn through, and that the accompanying nerve was partially lacerated.

An attempt was made to reduce the luxated astragalus by fixing the knee, after having bent the leg upon the thigh, and by making extension of the foot directly from the leg, laying hold of the heel with one hand, and placing the other on the dorsum of the foot. This, however, failed; and as it appeared that the skin, which firmly embraced the bone beneath, prevented the replacement, it was divided, and the extension renewed, but with the same unsuccessful result. This difficulty seemed to arise from the small size of the wound in the capsule of the joint, and in consequence of the bone being tightly held by the tendons.

Fearing, then, that the reduction was impracticable, I was led to consider whether the amputation of the leg ought not to be proposed; but Sir Astley Cooper happening to be in the hospital, I requested him to see the case, and after a careful examination of the injured limb, he suggested that the astragalus might be removed. I concurred, of course, in this proposal, as it afforded a probability of saving the limb, and I proceeded accordingly to perform the operation. I first applied a ligature on the posterior tibial artery, which, however, had not bled, the orifice being so contracted that a pin could not have been introduced. I then cautiously used a scalpel, detached the ligaments by which the astragalus is connected with the bones of the leg and tarsus, and found no considerable difficulty in removing the bone. The parts were then readily brought into apposition, and the wound was closed with straps of adhesive plaster. The leg was placed on its outside, resting on a well-padded splint, with a foot-piece; the foot was supported above the level of the knee, and the constant use of an evaporating lotion was ordered.

In the evening of the same day slight fever had come on, but the limb was tolerably easy; and the patient had an evacuation of the bowels.

During the first week he suffered considerably from constitutional irritation; and his recovery was retarded by the formation of two abscesses in the leg; but on the 25th of October the discharge had ceased; and the parts about the joint were perfectly sound, and bore pressure without inconvenience. He was capable at this time of bending the foot on the leg to a considerable extent, but he could not extend it. He was discharged from the hospital on November the 2nd, and has since resumed his business without inconvenience.

Case CXCVI. — John Haggart, æt. eighteen, was admitted into the Edinburgh Royal Infirmary under the care of Mr. Liston, September 29th, 1836. He had fallen on the pavement from the top of Holyrood Palace, a height of seventy-six feet. Immediately below the left external malleolus there is a wound an inch and a half in length, through which the astragalus, broken into numerous fragments, protrudes. The foot is displaced inwards. There is little or no bleeding, and the skin around the wound is of its natural appearance.

The comminuted astragalus was removed, the margins of the

aperture were brought together by suture, and the limb was placed on M'Intyre's splint. There was also dislocation of the left humerus, which was easily reduced.

30th. He complains of severe pains in the back and loins; but there is no wound or dislocation of the integuments in these regions, and no crepitus can be felt. Pulse 96, and of moderate strength. Great drowsiness, and considerable mental aberration.

October 4th. There is slight discharge from the wound, and the integuments of the ankle retain their natural appearance. He has slept ill; pulse 101; bowels open. Ordered nourishing food, and an opiate.

6th. He has been restless during the night, and the discharge from the wound is thin and scanty. Pulse 112; bowels constipated. Thirty minims of liquor sedativus and three aloetic pills were administered. Mr. Liston stated, that in consequence of the cerebral symptoms, and the constant and severe pain of the back and loins, the patient's chance of recovery would be very much diminished were amputation performed.

9th. The discharge is more profuse, and the wound looks well; but he still complains of pain in the back. Bowels regular. Habeat vini ℥xii.

10th. He has been delirious during the night; the discharge from the wound has increased, and is of a gleety appearance; pulse 120; bowels confined, thirst, severe pain of the back. Enema commune vespere; habeat vini ℥xvi.

12th. The delirium has somewhat subsided, but he is still incoherent: bowels moved; pulse 110.

13th.—He has rested well, and appears more composed; the pus is of a more healthy character, but has much increased in quantity; several small fragments of bone have been discharged; bowels regular; pulse 108; skin cool; less thirst.

14th. He has had several liquid dark-coloured stools. Habeat statim opii gr. ii. et rep. vespere si opus sit.

15th. The diarrhœa continues; the wound has assumed a more unhealthy aspect, and the pain of the back is undiminished.

16th. He is incoherent, but the dirrahœa has abated. There is slight discoloration around the wound, and a small vesicle over the internal malleolus, with considerable œdema of the leg;

much thirst; tongue dry and furred; pulse 112, soft and feeble. Cont. opium, et habeat enema c. tinct. opii ʒi.

17th. He has slept little: the discharge from the wound is very copious and fœtid, resembling serum mixed with blood and synovia; pulse 130; diarrhœa; skin cold; countenance exsanguine.

18th. The discoloration of the ankle extended rapidly during the night; he fell into a state of low muttering delirium, and died this morning at 6 A.M.

Inspection.—There was no appearance of reparation in the ankle-joint. The external malleolus was found detached, and an abscess extended among the muscles to the middle of the leg. Over the upper and posterior part of the sacrum there was a small aperture, evidently recent, from which pus escaped on pressure; and, on dividing the integuments, an extensive abscess was found, occupying the back part of the sacrum and lower lumbar vertebræ, and communicating with another larger abscess within the pelvis, and situated in the concavity of the sacrum. A longitudinal fracture extended through the centre of the sacrum.

Case CXCVII.—Mr. S., æt. forty-eight, stout, thick-set, of irregular habits, and short stature, was driving along the Greenwich-road, on the 4th of May, 1839, when the horse took fright and ran away. After in vain attempting to stop the horse, Mr. S. jumped out, and alighted on his left foot, which gave way under him; and, as he felt himself very severely injured, he was conveyed home, and sent for Mr. Miles, of Throgmorton-street, to whose son, Mr. John Shirley Miles, a pupil of Guy's Hospital, the Editor is indebted for a knowledge of the case.

Mr. Miles (with whom Mr. Eccles and Mr. Callaway were joined in consultation) found on examination the foot turned very much inwards and a little upwards; and there was a wound about an inch and a half long opposite to the outer ankle, from which protruded the astragalus, whose articulating surface with the os calcis was exposed. There was no fracture of the fibula.

As the dislocated parts could not be reduced, Sir A. Cooper was sent for, who recommended the astragalus to be removed. This was immediately done by Mr. Callaway; the wound was then closed by three sutures, and compresses of lint and plaster;

the limb was raised by pillows and made to rest on the heel, and two long splints with foot-pieces were applied. Sir Astley ordered a lotion of lead and spirits of wine, venesection to sixteen ounces, and a gentle aperient. The patient took also an effervescing draught with henbane every four hours, and a dose of calomel and Dover's powder at bed-time.

May 5th. The patient had a good night, but is excessively feverish to-day; another aperient was given, and perfect quietude enjoined.

In the evening the fever had considerably increased; pulse 120 and feeble; skin hot, and tongue very dry; he seemed also rather excited. A cold lotion was ordered for the head.

May 6th. This morning it was found that he had passed a favourable night; the bowels had been moved, the fever was abated, and the leg easy: pulse 90. In the evening, however, the pulse rose to 125, and the cerebral excitement returned. Five grains of carbonate of ammonia were added to each draught, and he took a dose of calomel and rhubarb at bed-time

May 7th. Much the same; pulse 110, skin moist.

May 8th. The wound was examined, and looked well; there was some redness of the knee, and vesication of the leg. He continues the effervescing draughts with ammonia, and takes half a grain of acetate of morphia at bed-time; and jelly, sago, beef-tea, &c. for his diet.

9th. Last night he was very restless; the head was hot, and there was much delirium. The wound looked tolerably healthy, and the ligatures were cut away. No matter was pent up. In the evening the patient was more wandering and excited; pulse 110. He took two grains of muriate of morphia.

10th. Last night he was again exceedingly restless; to-day the leg is much vesicated, and an erysipelatous redness is creeping up the thigh. Poppy fomentations and poultices were ordered; and a draught, containing four grains of quinine and five of carbonate of ammonia, to be taken every three hours; punctures were made to relieve the tension, and about a tablespoonful of pus was discharged from an opening made above the inner ankle. Coffee with isinglass, port wine, and jelly were ordered, and he took another morphia draught at bed-time.

11th. The leg was more swollen, and a gangrenous spot or two made its appearance; to these lint was applied, dipped in

solution of chloride of soda; incisions were made which discharged a sero-purulent fluid, and flakes of sloughing cellular tissue; and the limb was fomented and poulticed. Port wine and eggs were given ad libitum, and the patient was indulged with some turtle soup, as he expressed a great fancy for it.

12th. Fresh incisions were made, and the wounds discharged copiously; the tongue is dry and brown; and there was much delirium during the night; pulse 110.

13th. He passed a better night; the skin cool; pulse 100; the leg looking better, and healthy pus discharged in great abundance: but his powers are very low, and the belly becoming tympanitic; three or four fresh incisions were obliged to be made, and some swelling is observable in the right leg.

14th. He passed a very restless night; the tongue dry and brown; pulse very weak; belly more distended, and the discharge more profuse and fœtid. In the evening he appeared rapidly sinking; and on the 15th he expired.

Post-mortem examination. — The tibia and fibula were quite free from fracture, but the articular surface of the tibia was abraded by inflammation. A large abscess was found underneath the metatarsal bones; and a prodigious quantity of matter had burrowed up the leg under the gastrocnemii, nearly as far as the knee; showing pretty clearly, that even if the patient had survived, his limb must eventually have been amputated.

Case CXCVIII.—The Editor has now (November 1841) a case under his care of most extensive fracture of the lower ends of the tibia and fibula, with compound dislocation of the astragalus inwards, which is at this moment in rapid progress towards recovery, under the simple treatment recommended by the author; namely, semiflexed position of the limb, lint dipped in the patient's blood placed over the wound; the continual application of evaporating lotions; calomel and opium to subdue irritation, and saline aperients with antimony to maintain the secretions. The accident occurred to Mr. ——, near Aylesbury; and Mr. Ceeley, an eminent practitioner of that town, reduced the dislocation, applied a long splint along the outer side of the limb, and in conformity with the patient's desire brought him up to town to his own residence. When we examined the limb together, on the patient's arrival at his

own house, a part of the astragalus still projected through the wound, and confined a portion of skin so tightly under it that I considered it advisable to remove the piece of bone. By this means the skin was immediately liberated, and the foot readily placed in its natural position. The result of this treatment is a further illustration of the validity of the views of the late Sir Astley Cooper respecting severe compound injuries to the ankle-joint; especially as to the propriety of removing projecting portions of bone, rather than by violent extension attempting to return them into their natural position. Although this case is still under treatment, I have no hesitation in pronouncing the patient's life safe, and that there is every prospect of his regaining the use of the limb.

Dislocation of the Os calcis and Astragalus.—The five anterior bones of the tarsus are sometimes dislocated from the os calcis and astragalus. There is a joint placed transversely between the os calcis and astragalus, on the one hand, and the os naviculare and os cuboides, on the other; and this joint is sometimes, but rarely, luxated by very heavy weights falling upon the foot, of which the following case is an example.

Case. CXCIX.—A man working at the Southwark Bridge had the misfortune to have a stone of great weight glide gradually on his foot: he was almost immediately brought to Guy's Hospital, and the following were the appearances of the foot. The os calcis and the astragalus remained in their natural situations, but the fore part of the foot was turned inwards upon these bones. When examined by the students the appearance was so precisely like that of a *club foot*, that they could not at first believe that it was not a natural defect of that kind; but upon the assurance of the man that previously to the accident his foot was not distorted, an extension was made by fixing the leg and the heel; the fore part of the foot was then drawn outwards, and thus the reduction was effected. This person was discharged from the hospital in five weeks, having the complete use of his foot.

The following interesting case was under the care of Mr. Henry Cline; and for the particulars I am indebted to Mr. South.

Case CC.—Thomas Gilmore, an Irish labourer, aged forty-five years, was admitted, under Mr. H. Cline, into St. Thomas's

Hospital, about eleven o'clock of the morning of March 28th, 1815. Whilst walking at the New Custom-house this morning, he received a blow on the heel from the falling of a stone (said to be half a ton weight), which made a wound on the fore part of the ankle-joint, and dislocated the astragalus.

The parts were in the following state:—A wound extended from opposite the middle of the base of the tibia, round the upper part of the instep, to the external malleolus, which exposed the articulating surface of the astragalus with the navicular bone on the fore part, as well as that with the os calcis on the outside; from both of which bones the astragalus was displaced: its connexion with the tibia and fibula, however, was undisturbed. The tuberosity of the os calcis projected outwards, but the rest of the foot turned in, so that the toes pointed much inwards, towards the opposite foot.

The reduction was effected by extending the foot, and rotating it outwards; the wound was brought together with straps of adhesive plaster; the leg was covered with soap plaster and put in a fracture box, on the heel; the parts were kept uncovered, and a slight hæmorrhage supervening, linen rags, dipped in cold water, were applied.

He was a robust man, had been in the habit of drinking, and says he has been subject to the gout.

During the treatment he had a severe attack of erysipelas of the leg, which led to the formation of numerous abscesses; so that he did not leave the hospital till September the 12th, when he was able to walk pretty well with a stick.

Dislocation of the os cuneiforme internum.—I have twice seen this bone dislocated: once in a gentleman who called upon me some weeks after the accident, and a second time in a case which occurred in Guy's Hospital very lately. In both these instances the same appearances presented themselves. There was a great projection of the bone inwards, and some degree of elevation, from its being drawn up by the action of the tibialis anticus muscle; and it no longer remained in a direct line with the metatarsal bone of the great toe. In neither case was the bone reduced. The subject of the first of these accidents walked with but little halting, and, I believe, would in time recover the use of the foot so as not to appear lame. The cause of the accident was a fall from a considerable height, by which

the ligament was ruptured which connects this bone with the os cuneiforme medium, and with the os naviculare.

The second case, which was in Guy's Hospital, my apprentice, Mr. Babington, informs me, happened by the fall of a horse, and the foot was caught between the horse and the curb-stone.

The treatment of this injury will consist in confining the bone in its place, by at first binding it with a roller dipped in spirits of wine and water, with which it must be constantly kept wet; and when the inflammation is subdued, a leathern strap is to be buckled around the foot, to keep the bone in its place till the ligament be united.

The following case was treated by Mr. Luke, in the London Hospital.

Case CCI. — P. Power, a labourer, was brought to the London Hospital with an injury to the right foot. Upon examination the three cuneiforme bones appeared to be partially dislocated upwards. The internal cuneiforme bone was chiefly displaced from the navicular bone, and projected upwards and inwards. No crepitus was perceived, and the ankle-joint was uninjured. By extension from the toes, and by pressure upon the displaced bones, they were returned after some time, with an evident sensation. A great deal of inflammation followed, which was subdued by leeches and cold lotion. The strength in his foot returned slowly, and he was not able to bear on it, or to walk, till six weeks after the accident.*

Case CCII.—" J. H. æt. fourteen, a bricklayer's boy, fell from a height of forty feet, and alighted on the extremity of the right foot. The ligaments on the dorsal surface of the foot appear to be started; the scaphoid and cuboid bones project a little upwards from their usual situation. The foot is half an inch shorter than the other one. The leg was elevated; fomentations, &c.; but no attempt was made to reduce the misplaced bones.

" In about three weeks he left the hospital: he was able to stand on the foot. The instep appears higher than the other one; the foot is shorter by half an inch, and has a somewhat clubbed appearance."

Case CCIII.—" Dislocation of the distal extremity of the metatarsal bone of the great toe will sometimes occur from direct violence. The following case is an example of it. J. B. M.,

* Med. Gaz. vol. vii. p. 704.

æt. fourteen, was thrown from his horse, which fell from him, and in getting up trod on his foot. He had received a wound on the inner side of the foot, opposite the distal extremity of the metatarsal bone of the great toe; the articulating extremity of the bone was protruding through the wound, and was broken off from the rest of the bone. The broken head of the bone was removed. The wound healed in about six weeks, and the patient had the perfect use of his foot." *

The metatarsal bones I have never known luxated: their union with each other, and their irregular connexion with the tarsus prevent it; and if it ever happens, it must be a very rare occurrence.

DISLOCATION OF THE TOES FROM THE METATARSAL BONES.

Case CCIV. — This is a very uncommon accident; but I had a man under my care at Guy's Hospital, who had such a degree of lameness as to be unable to get his bread by his daily labour, owing to an injury sustained by falling from a considerable height, and alighting upon the extremities of his toes. Upon examination of the bottom of the foot, a considerable projection was found at the roots of all the smaller toes, the extremity of each metatarsal bone being placed under the first phalanx of its corresponding toe. Several months had elapsed from the time of the accident; and, at first, from the swelling of the foot, it had not been detected. No extension, at the time when I saw him, could answer any purpose, and the only mode of relief was to wear a piece of hollow cork at the bottom of the inner part of the shoe, to prevent the pressure of the metatarsal bones upon the nerves and blood-vessels.

The toes are sometimes dislocated, but as the mode of their reduction will be the same as that of the fingers, I shall reserve the subject until the dislocations of the fingers are described.

Fracture of the os calcis.—The ensuing case, which was communicated to me by Mr. Marsden, of Gargrave, Yorkshire, affords a good parallel to those cases of fractured patella and olecranon which occur from muscular contraction only, without the direct application of an external force.

Case CCV. — Miss N., a lady about forty years of age, was walking in a field on the 6th of December last, towards

* Liston, Practical Surgery.

the close of day, when she stumbled and fell to the ground, and for some time was unable to rise. By good fortune, some men were returning home from work, and finding she could not walk, carried her to a neighbouring house. I was sent for to examine the accident, and she informing me that she felt something strike the back part of the leg, I immediately supposed she had ruptured the tendo Achillis of that leg, and I instantly commenced examining that part, when I was surprised to feel something uncommonly sharp and hard, not like the feel of a ruptured tendon; I found it to be the os calcis which was fractured, and which was drawn up by the action of the gastrocnemii to three inches from its situation. I immediately informed the lady of the accident she had sustained, and the necessary treatment; but, unfortunately, she was extremely deaf, and of a very obstinate temper, so that I could scarcely prevail upon her to go to bed. Though she had violent pain, she would continue to irritate the part by bending and extending the foot with her hands, thinking it was only a sprain, and would soon be better; the consequence of which was, that most violent inflammation ensued, and I was afraid she would lose her leg. By evaporating lotions and poultices, however, in a week the inflammation and swelling were reduced, and I applied a bandage similar to the one described by Dr. Monro; but was unable to bring the bones in apposition, nor could I prevail upon her to wear the bandage more than a week; therefore, I ordered her to wear a high-heeled shoe, which she has done ever since, and is now able to walk very well by the aid of a stick, and can bend and extend the foot at pleasure, the bone remaining in the situation before mentioned, and the interspace being filled up by ligamentous substance.

Case CCVI.—My friend, Mr. J. H. Green, related to me, some years ago, the case of a lady, who, going up stairs in the dark and believing there to be another stair, when she had really ascended the whole flight, fractured this bone by the violent action into which the muscles of the leg were thrown in consequence of the efforts she made to preserve herself from falling. The patient was placed in bed, with the knee flexed and the foot extended until the inflammation was subdued. A high-heeled shoe was then used for the purpose of keeping the tendo Achillis in its most complete state of relaxation, but ligamentous union only could be effected.

CHAPTER IX.

ON DISLOCATIONS OF THE JAW.

SECTION I.—ANATOMY OF THE JOINT.

The parts which constitute the articulation of the lower jaw are the glenoid cavity of the temporal bone, and the condyloid process of the lower jaw-bone, between which is situated an inter-articular cartilage. The ligaments of the joint, are, first, a thin capsular ligament; secondly, an external lateral ligament, which passes from the tubercle of the zygoma to the external surface of the neck of the jaw; and thirdly, an internal lateral ligament, which arises from the apex of the spinous process of the sphenoid bone, and is inserted into the margin of the dental foramen, which is situated an inch and a half below and anterior to the condyloid process. The last is not, properly speaking, a ligament of the joint, for it is not connected with the synovial membrane and interarticular cartilage, as the two first are; and it is separated from the joint by the internal maxillary artery.

In front of the glenoid cavity of the temporal bone is an eminence which forms one of the roots of the zygomatic process. This eminence is covered with cartilage and synovial membrane,

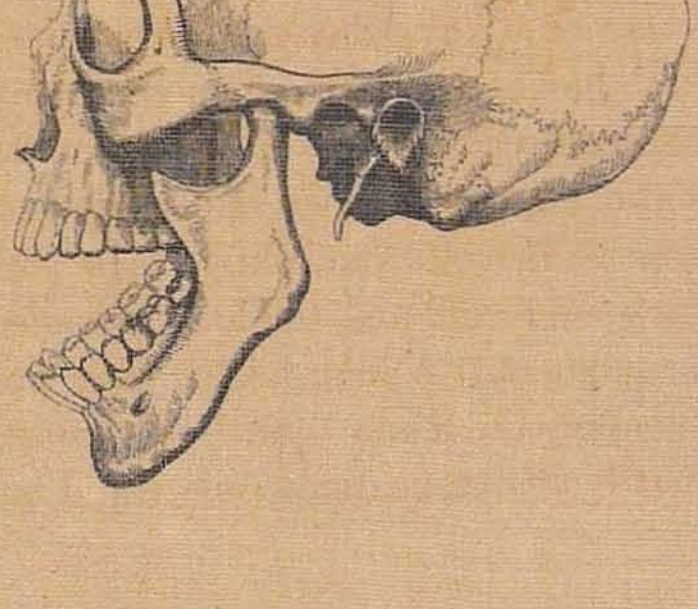

and is included in the joint. When the mouth is open widely, the condyloid process slips forwards and rests upon it; for, from the manner in which the jaw is *hung*, it will readily be seen that when the chin is depressed or thrown backwards, the condyloid processes tend to come forwards on these eminences; and it may also be readily seen that a blow on the chin when the mouth is open may throw the condyloid process on each side, completely over these eminences, into the space between the zygomatic arch and the surface of the temporal bone.

The jaw has the following motions:—It may be drawn upwards and downwards, backwards and forwards, and transversely. Its elevation is produced by the temporal, the masseter, and the pterygoideus internus: its depression by the platysma myoides, digastricus, mylo hyoideus, genio-hyoideus, and genio-hyo glossus muscles. The jaw is drawn backwards by a part of the masseter; and (when the os hyoides is fixed) by the digastricus, the genio-hyoideus, and genio-hyo glossus. It is pulled forwards by a portion of the masseter, and by the combined action of the pterygoidei externi.

The lateral motions of the jaw are principally produced by the contractions of the external pterygoid muscles, which in alternate actions pull the jaw from side to side, and give it its grinding action, in which these muscles are assisted by the oblique motion forwards, given to the jaw by the pterygoideus internus.

SECTION II.

DISLOCATION OF THE JAW.

Symptoms.—Dislocation of the jaw *on both sides* is known to have happened by the open state of the mouth, and by the impossibility of closing it, either by the patient's efforts, or by pressure made upon the chin. It may, however, be still in some degree approximated to the upper by muscular efforts; but the lower teeth, if the mouth could be closed, would be in a line anterior to the upper. Some degree of depression of the jaw may also still be produced, but to an inconsiderable extent.

Thus the appearance of the patient is that of a continued yawning. The cheeks are projected by the advance of the coronoid processes towards the buccinator muscle, and there is a depression just anterior to the meatus auditorius, from the absence of the condyloid process from its cavity. The saliva is not retained in the mouth, but dribbles over the chin; and a very considerable increase of this secretion follows, in consequence of the irritation of the parotid glands. The pain accompanying the accident is severe, but I have never seen any dangerous effect produced by it; on the contrary, the jaw becomes more nearly closed by time, and a considerable degree of motion is recovered.

Causes.—This accident may be caused by taking into the mouth too large a body, as I have known when, two boys in play struggling for an apple, one has forced it into his mouth, and dislocated his jaw. A blow upon the chin, when the mouth is widely opened, produces the same effect. Yawning very deeply is also a frequent cause of the accident, in relaxed states of the system; the mouth being opened so widely as to throw the condyles completely over the articular eminences.

A sudden spasmodic action of the muscles will produce this dislocation when the mouth is opened, and it has often happened in attempts to extract the teeth, where the mouth has been opened too widely. Mr. Fox, the dentist, whose death we have to deplore as a man of science, told me that he was called to a lady who had a tooth which required to be extracted, and that in the attempt to do so, a sudden spasm dislocated the jaw.

Treatment.—The jaw must be immediately restored to its situation, and the mode of reduction I shall explain by the following case.

Case CCVII.—A madman, confined in one of the houses in Hoxton, during an attempt to give him some food, which the keeper was obliged to force him to receive, had his jaw dislocated. Mr. Weston, surgeon, in Shoreditch, was sent for, who, finding the man very powerful and very unmanageable, preferred rather to send for some other surgeon, to consider with him the best mode of making the attempt at reduction. When I saw the man I thought that a surgeon must be as insane as the patient who would employ the usual means of reduction, and I therefore desired that the keepers would place the patient on a table

upon his back, with a pillow under his head, and that he should be held by several persons. I ordered two table forks to be brought me, and wrapped a handkerchief around their points: placing myself behind the patient's head, I carried the handles of the forks into the mouth, on each side, behind the molar teeth; then directed them to be held, and placing my hand under the chin, I forcibly drew it to the upper jaw, and the bone was easily and quickly reduced.

In the above-mentioned case the handles of the forks were not used as levers, by lifting them; they only rested upon the jaw, which was used as a lever upon them, depressing the processes as the jaw was elevated, and thus directing the bone backwards into its natural situation. But as wood is liable to injure the gums, it is better to substitute two corks, which are to be placed behind the molar teeth on each side of the mouth, and over these the chin is to be raised. They are equally effectual in reducing the bone, and are less likely to injure it, or to bruise the soft parts. It has been recommended in these cases, to use a piece of wood as a lever, by introducing it between the molares teeth, first on one side and then on the other, reducing one side first, and then using the same means to the other. Mr. Fox, in the case before alluded to, succeeded thus: he placed a piece of wood, a foot long, upon the molar tooth on one side, and raising it at the part at which he held it, depressed the point at the jaw on that side, and succeeded in reducing the jaw. He then did the same on the other side, and thus replaced the bone. But the corks, the recumbent posture, and the elevation of the chin, constitute the mode which I prefer.

In the ordinary way of reducing this dislocation, the surgeon wraps a handkerchief round his thumbs, placing them at the roots of the coronoid processes; and, depressing the jaw, he forces it backwards as well as downwards, when the bone suddenly slips into its place; but this mode does not so easily succeed as the others, excepting in recent dislocations. When the jaw has been once dislocated, it is very liable to the same accident, and therefore a broad tape, with a hole cut in it to receive the chin, divided into four ends by splitting it on each side some way down, is to be tied over the summit of the head and occiput, to confine the jaw until the lacerated parts have healed, by which the tendency to subsequent luxation is diminished.

I received the following case from Mr. Morley.

CASE CCVIII.—"Sarah Jobson, residing at Horncastle, aged thirty years, of a strong muscular habit, some hours after her delivery had a fit, during which her mouth became widely distended, for which blood-letting, blisters, and other antiphlogistic remedies were employed: she quickly recovered, but the mouth continued open. The surgeon who attended her conceiving this to arise from a spasmodic action of the muscles, treated it as such without success. At the expiration of one month and five days I was desired to see her, and on examination found her jaw dislocated on both sides; under the zygomatic arches there was great fulness, caused by the rami of the jaw, which were very distinctly felt just within the angles of the mouth, with considerable depressions anterior to the ears; the upper and lower front teeth were nearly one inch and a half apart, and the lower teeth were a little more than half an inch advanced; the dentes sapientiæ were in close contact with each other, and saliva was constantly flowing from the mouth. Still at this time she was entirely free from pain, although previously she had suffered severely. I tried by my unaided force to move it, but was unable, and therefore proposed that she should lose some blood from her arm, but this was objected to. I then procured three assistants, by whom she was firmly held in a chair. I protected my thumbs in the usual manner with strips of linen, and placed them as far back as possible on the molar teeth, at the same time putting my fingers under the chin and base of the jaw, with a napkin interposed; I then attempted reduction by making moderate pressure with the ends of my thumbs, downwards and backwards: this did not at first occasion much pain, but its continuance occasioned severe sufferings. I at the same time elevated the chin. This process was continued for about three minutes, after which the right condyle slipped back into its articular cavity, but was immediately brought forwards again by the action of the muscles. I then made pressure more particularly on the other side, when it soon returned into its proper cavity; the right was again easily replaced, and so they remained by supporting and holding back the jaw, which seemed very prone to return to its former situation. Two pieces of bandage were then crossed obliquely, and a hole was cut at their crossing to receive the chin; the ends were brought over the upper and

back parts of the head and secured; a piece of cork, half an inch thick, was also placed between the teeth of both sides and fastened by ligatures to the bandage, so as to admit of a spoon being introduced between them; antiphlogistic medicines were administered, and an evaporating lotion was kept constantly applied to the face, &c.

On the following day she complained of much pain about the temporal muscles, ears, and face, accompanied by so much swelling that she could scarcely open her eye-lids. On the third day it had much subsided, and the pain was somewhat abated. She was not allowed to masticate any food for nearly a fortnight; after which time the cork was removed, and the hole for the chin was gradually enlarged, so as to permit the mouth to open wider. She wore the bandage for six weeks, and then could perform every motion with her jaw as well as before. It is now nearly seven months ago, and she has not had the least symptom of a second displacement. Her friends remarked to me, that the deformity appeared at first much greater than when I saw it; that for the first fortnight she could scarcely articulate, or swallow anything, and that the lower teeth also projected nearly one inch beyond the upper ones."

Dislocation of the Jaw on one side only. — When the jaw is dislocated on one side only, there is an incapacity to close the mouth; but it is not so widely opened as in the dislocation of both sides. It is easy to distinguish this accident, as the chin is thrown to the side opposite to the luxation, and the incisor teeth are not only advanced upon the upper jaw, but are no longer in a line with the axis of the face. The cause of this accident is a blow on the side of the face when the mouth is opened, and in one case it occured from vomiting in sea sickness. In this example, the lady, Miss Belfour, daughter of the late Admiral Belfour, of Portsmouth, reduced her jaw by an oyster-knife, which she turned half round upon the side of the jaw between the teeth, and so returned it to its place.

In treating this injury, the lever of wood reduces the bone most easily, but the cork may be used on one side, and the chin be elevated, as in those cases in which the dislocation is complete.

Subluxation of the Jaw.—As in the knee, the thigh-bone is sometimes thrown from its semilunar cartilages, so the jaw

appears occasionally to quit the interarticular cartilage of the temporal cavity, slipping before its edge, and locking the jaw, with the mouth slightly opened. It generally happens, that this dislocation is quickly removed by natural efforts alone; but I have seen it continue for a length of time, and the motion of the jaw, and the power of closing the mouth have still returned. This accident happens from extreme relaxation. The patient finds himself suddenly incapable of entirely closing the mouth; some pain is felt, and the mouth is least closed on that side on which the pain is felt.

In order to remove these appearances force must be applied directly downwards, so as to separate the jaw from the temporal bone, and to give an opportunity for the cartilage to replace itself upon the rounded extremity of the condyloid process.

In extreme degrees of relaxation, a painful *snapping* is sometimes felt in the maxillary articulation just before the ear; this arises from the sudden relapse of the jaw into its socket, which the relaxation of the ligament had permitted it to quit, and to advance upon the zygomatic tubercle.

Young women are generally subject to this sensation, and the means which I have found most frequently and quickly tending to ensure their recovery have been ammonia and steel as medicine; with the shower-bath, and the application of a blister before the ear, when the complaint has continued for a length of time.

A lady whom I attended took bark and valerian twice per diem,* with subsequently a shower-bath; and when she has relapses she has recourse to the same means with excellent effect.

Dislocation of the os malæ.—The term dislocation can, perhaps, scarcely be applied with strict propriety to a disruption of the sutures of the facial or cranial bones; and, in fact, any displacement of those bones must almost of necessity be accompanied with more or less of fracture. But, be this as it may, the following case, with which the Editor was favoured by his friend Mr. Gossett, in the year 1824, will be found interesting.

Case CCIX. ——, who supported himself by supplying the anatomical schools with subjects, while sparring with one of his associates, received a blow on the outer part of the left

* ℞ P. Cinchonæ, ʒss; P. valerian, ℈i., fiat pulvis bis die sumendus.

cheek, which gave him considerable pain at the time, and rendered him incapable of separating the teeth, excepting to a very limited extent, which he attributed to the contused state of the face, and expected soon to recover; but finding his ability to separate the jaws gradually diminish, he applied, first, to Mr. Grainger, whom (to use his own phrase) he supplied with a few articles, and afterwards to myself. I found on examination a distinct depression of the zygomatic process of the os malæ, with a corresponding elevation of the inferior orbitar and maxillary processes, the zygoma obviously projecting over the depressed portion of the os malæ, which could be traced behind it, and the superior orbitar process was also partially displaced at the transverse suture, as was proved by the decided irregularity which could be felt at the outside of the orbit. At the time he consulted me it was with some difficulty that he could open his mouth sufficiently wide to admit my fore-finger; and I recommended him, if he should get worse, to allow me to cut down upon the part and endeavour to elevate it, or remove it with a trephine. After this I lost sight of him for some time, but feeling an interest in the case, I had preserved his address, and as he did not call on me I determined to visit him. Finding him much improved, he informed me, on inquiring into the history of his progress, that till within a very short period of my calling he gradually became worse, until his jaw was almost completely fixed, and he found so much difficulty in feeding himself that he was declining rapidly in strength and flesh, when, one morning, before he was out of bed, on yawning violently he felt something snap, and from that time he had gradually reacquired the power of opening his mouth. The explanation of this case appears, I think, sufficiently simple. In the first instance the depressed portion of the os malæ prevented the separation of the jaws, by its pressure against the coronoid process of the inferior maxilla, which effect was gradually increased by the inflammation and consequent thickening, of the surrounding structures following the injury, on the subsidence of which absorption commenced and again gradually liberated the parts.

CHAPTER X.

ON DISLOCATIONS OF THE CLAVICLE.

SECTION I.—ANATOMY OF THE ARTICULATION OF THE CLAVICLE WITH THE STERNUM.

As the clavicle is the only medium by which the arm is connected with the trunk, it might be expected that it would be very frequently dislocated; but it is so peculiarly and strongly articulated, both with the sternum and the scapula, as to render its dislocation comparatively rare.

The articulating surfaces, both of the sternum and clavicle, are in part convex, and in part concave; and both are covered by an articular cartilage similar to that of the other joints.

A capsular ligament proceeds from the end of the clavicle to the edge of the articulating surface of the sternum, and it is strengthened by short ligaments (sterno-clavicular), which pass directly from one bone to the other, on their anterior and posterior surfaces.

Within the capsular ligament is situated an interarticular cartilage, which is attached at the upper part of the joint to the clavicle, and to the capsular ligament; whilst at the lower part of the joint it is attached to the edge of the articular surface of the sternum, and to the cartilage of the first rib. It is placed obliquely, its upper end being inclined inwards, and its lower end outwards; so that the articular extremity of the clavicle rests upon its surface. Of that portion of this cartilage which is in contact with the clavicle, the lower half is smooth, and covered with synovial membrane, to allow of the motion of that bone; but the upper half of it has a flat, rough surface, and adheres to the clavicle. On the side towards the sternum the interarticular cartilage has a smooth and concave surface, which allows of its free motion on that bone. By this interarticular cartilage, the articulation of the clavicle with the sternum is divided into two joints, both of which are provided

with distinct synovial membranes; but there is sometimes a perforation in the centre of the cartilage, through which they communicate.

From the upper point of the clavicle proceeds an interclavicular ligament, which traverses the upper and back part of the sternum, and is fixed in the extremity of the opposite clavicle, so as to unite very strongly one clavicle to the other.

The clavicle is also joined to the first rib by a claviculo-costal, or, as it is called, rhomboid ligament, which proceeds from the inferior surface of the sternal end of the clavicle to the cartilage of the first rib.

The motion of the clavicle, as well as that of the sternum, forwards and backwards, is performed upon that surface of the interarticular cartilage which is applied to the sternum; whilst the motion of the clavicle, upwards and downwards, is produced upon that surface of the interarticular cartilage which is applied to the clavicle. One great advantage derived from this mode of articulation is, that it allows of the motion of the bone outwards and backwards to a considerable extent, without the necessity of having a long, loose ligament; for it may be considered that there are two ligaments, one from the clavicle to the cartilage, and one from the cartilage to the sternum; which arrangement allows of as much motion, and yet is much stronger than one loose, long ligament from bone to bone would be.

SECTION II.

DISLOCATIONS OF THE STERNAL EXTREMITY OF THE CLAVICLE.

These are of two kinds; viz. the dislocation *forwards*, in which the clavicle is thrown before the sternum; and the dislocation *backwards*, in which the end of the bone is thrown behind the sternum.

DISLOCATION FORWARDS.

SYMPTOMS. — The circumstances by which this injury is known are, that upon looking at the upper part of the sternum a rounded projection is seen, and when the fingers are carried upon the surface of the sternum upwards, this projection stops them. If the surgeon places himself behind the patient,

puts his knees between the scapulæ, grasps the shoulders, and draws them back, the projection on the sternum disappears; but directly when the shoulders advance, the projection upon the

*

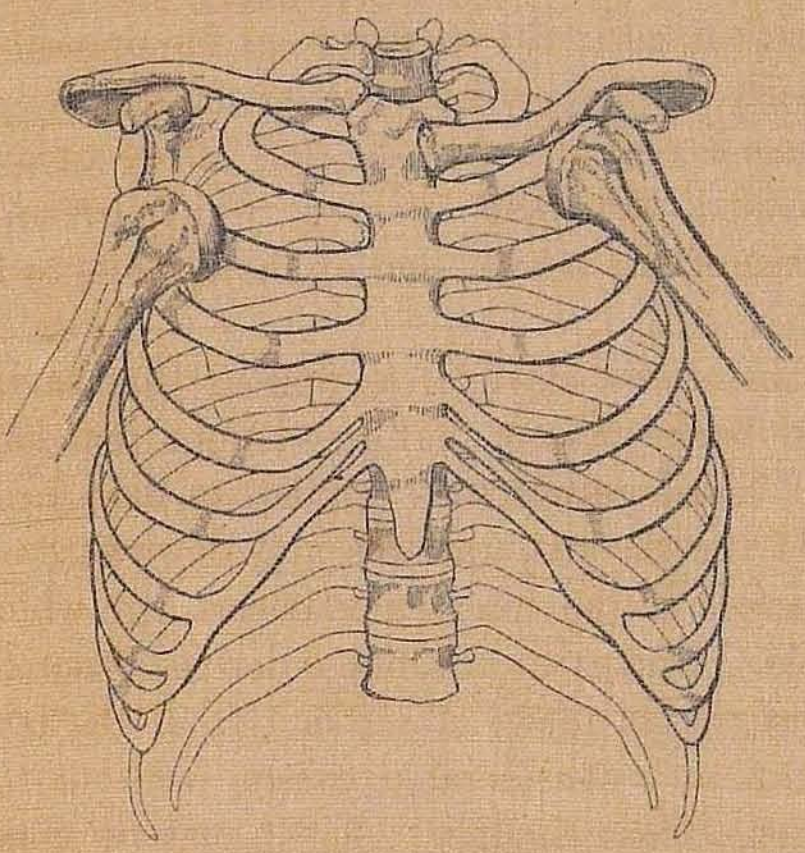

sternum is renewed. The clavicle may be readily traced with the finger into the projection on the sternum. If the shoulder be elevated the projection descends; if it be drawn downwards the dislocated extremity of the bone becomes elevated to the neck. The motions of the dislocated clavicle are painful, and the patient moves the shoulder with difficulty. The point of the injured shoulder is less distant from the central line of the sternum than usual. In a very thin person the nature of the accident can be at once ascertained, because the bone is but little covered; but in fat persons it is more difficult to detect. When the patient is at rest very little pain or tenderness is felt from the accident.

It sometimes happens that this dislocation is incomplete, the anterior portion of the capsular ligament only being torn, and the bone slightly projecting; but generally all the ligaments are

* This figure is intended to represent dislocation of the sternal extremity of the clavicle, and dislocation forwards of the shoulder-joint on its left side; and dislocation of the acromial end of the clavicle, and dislocation of the shoulder downwards on its right side.

lacerated, and the bone, with its interarticular cartilage, is thrown forwards.

Cause. — The cause of this injury is a fall upon the point of the shoulder, the force of which pushes the clavicle inwards and forwards, and projects it on the sternum; but it also frequently happens from a fall upon the elbow when separated from the side; by which the clavicle is forced violently inwards and forwards against the anterior part of the capsular ligament.

Case CCX. — "A baker's boy," says Boyer, "in order to repose himself, rested his basket full of bread on the parapet of a bridge; the basket lost its equilibrium, and was falling backwards; the boy endeavoured to oppose it, and, in the effort, the straps which passed under each arm-pit acted so powerfully on the points of his shoulders, that one of his clavicles was luxated forwards."*

Treatment.—With respect to the means of reduction, and the principle upon which the treatment is to be regulated, there is no difficulty in practising the one, or in understanding the other. The clavicle is easily returned to its place by pulling the shoulder backwards, because then it is drawn off the sternum, and its end falls upon the cavity which naturally received it; but if pressure in this position of the shoulder be not made upon the fore part of the bone, it will be found still liable to project in some degree.

The principle, therefore, upon which the extension is made, is to draw the scapula as far from the side as is practicable without inconvenience, and by supporting the arm, to prevent its weight from influencing the position of the bone.

The first of these objects is best effected by the use of the clavicle bandage, and by the application of two pads or cushions affixed to it, which are placed in the axillæ. These pads throw the head of the os humeri from the side, and carry the scapula, and the clavicle connected with it, outwards and backwards, and thus the clavicle is drawn into its natural articular cavity. The second intention is effected by putting the arm in a sling, which, through the medium of the os humeri and scapula, supports the clavicle and prevents it from being drawn down by the weight of the arm.

* Boyer on Diseases and Injuries of the Bones, translated by Farrell. Lond. 1807.

*

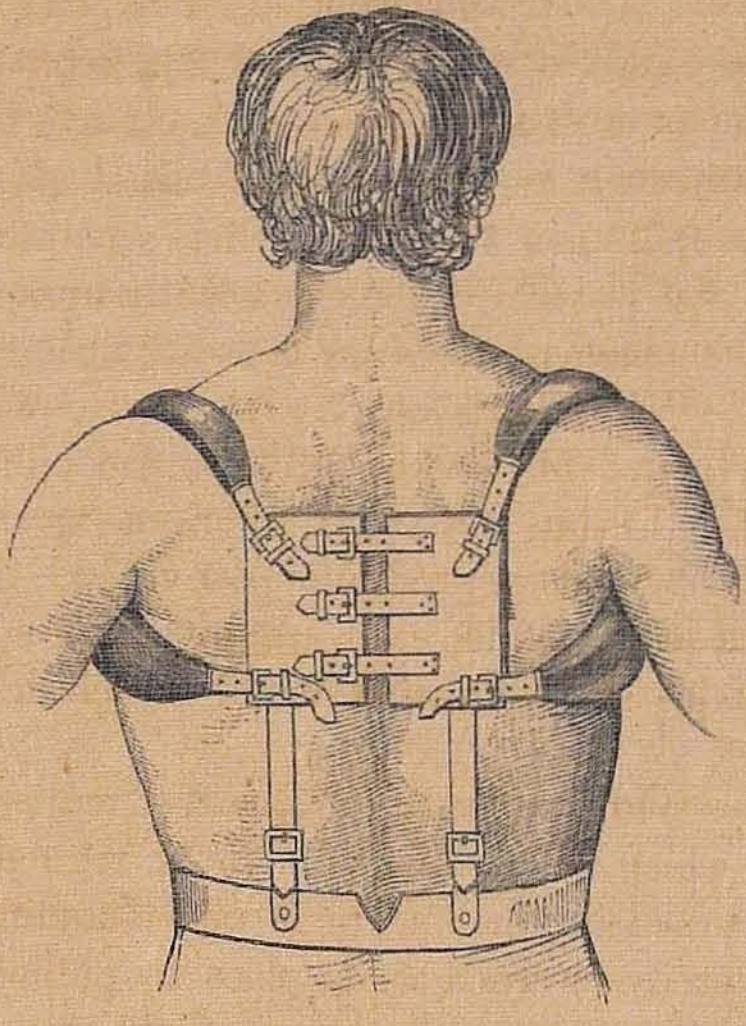

Dislocation backwards.—The dislocation of the sternal extremity of the clavicle backwards I have never known occur from violence, yet it might happen from excessive force; a blow, for instance, upon the fore part of the bone, might tear the capsular and rhomboid ligaments, and allow the bone to glide behind the sternum, where it would occasion compression of the œsophagus, and render deglutition difficult. The trachea would, from its elasticity, elude pressure, and escape to the opposite side of the space by which it enters the thorax.

The only cause of this dislocation that I have known, was great deformity of the spine, by which the scapula advanced, and sufficient space was not left for the clavicle between the scapula and sternum; in consequence of which, the bone gradually glided back behind the sternum, and produced so much inconvenience by its pressure on the œsophagus, as to lead to a necessity for the removal of its sternal extremity.

This case is extremely creditable to the knowledge, skill, and dexterity of Mr. Davie, surgeon at Bungay, in Suffolk; few would have thought of the mode of relief—very few would have

* This figure shows the bandage for fracture and dislocations of the clavicle.

dared to perform the operation—and a still smaller number would have had sufficient knowledge to accomplish it.

The following particulars I in part received in conversation with Mr. Davie, who fell a victim to his great professional zeal, and in part from Mr. Henchman Crowfoot, surgeon at Beccles. He had the kindness to go over to Dr. Camell, of Bungay, to learn from him some of the particulars, and there met with a person who gave him several others, and who knew the patient for some years after the operation.

Case CCXI.—Miss L., of Metfield, Suffolk, had a great deformity, arising from a distorted spine, increased by an accident which displaced the sternal extremity of the left clavicle, and threw it behind the sternum. The progressive distortion of the spine gradually advanced the scapula, and occasioned the sternal end of the clavicle to project inwards, behind the sternum, so as to press upon the œsophagus, and occasion extreme difficulty in deglutition. Her deformity had become excessive, and her emaciation extreme.

Mr. Davie conceived that he should be able to prevent the gradual destruction which the altered position of the clavicle threatened, by removing the sternal extremity of the bone; and the operation which he performed for this purpose was, according to all I can learn, as follows.

An incision was made of from two to three inches in extent on the sternal extremity of the clavicle, in a line with the axis of that bone; and its surrounding ligamentous connexions, as far as he could then reach them, were divided with the saw of Scultetus (often called Hey's); he then sawed through the end of the bone, one inch from its articular surface from the sternum, and fearful of doing unnecessary injury with the saw, he introduced a piece of well beaten sole leather under the bone whilst he divided it. When the sawing was completed he tried to detach the bone, but it still remained connected by its interclavicular ligament, and he was obliged to tear through that ligament by using the handle of the knife as an elevator, and after some time succeeded in removing the portion of bone which he had separated.

The wound healed without any untoward occurrence, and the patient was enabled to swallow, as the pressure of the clavicle upon the œsophagus was now removed.

She lived six years after the operation, and recovered considerably from her former emaciation. "Of what she ultimately died," says Mr. Crowfoot, "I have not learnt."

SECTION III.

ANATOMY OF THE ARTICULATION OF THE CLAVICLE WITH THE SCAPULA.

The clavicle is articulated with the spine of the scapula about three quarters of an inch behind the extremity of the acromion. The end of the clavicle is slightly convex, and covered by an articular cartilage; the scapula has a concave surface to receive it, and this surface is also covered by an articular cartilage. Strong ligamentous fibres pass directly from one bone to the other, and under these a capsular ligament is extended from the edge of the socket of the scapula, to the extremity of the clavicle. The surface of junction is very small, the end of the clavicle not being longer than the end of the little finger of an adult; and the cavity in the scapula which receives it is very superficial, being not larger than is required to receive upon its surface the end of the clavicle.

But the junction of the two bones is effected by much stronger means, through the medium of the coracoid process of the scapula, which sends forth two ligaments to the clavicle. The first proceeds from the root of the coracoid process, and is fixed in a small tubercle of the clavicle on its under side, at the end of the insertion of the subclavius muscle, and two inches from the extremity of the bone. This ligament has been called the conoid, from its form, but may be better named the internal coraco-clavicular. The use of this ligament is to bind down the clavicle to the scapula, and to confine the motion of the clavicle forwards and upwards.

The second ligament of this part is called trapezoid; it proceeds from the coracoid process, and passes on the under side of the clavicle to near its scapular end, into which it is fixed; I call it the external coraco-clavicular. This ligament is the chief

means of preventing dislocation of the scapular end of the clavicle, for when its capsular ligament is divided, the scapula cannot be forced under the clavicle without lacerating this ligament, so great is its resistance. It allows of very free motion of the scapula backwards and upwards, but confines its motions forwards.*

SECTION IV.

DISLOCATION OF THE SCAPULAR EXTREMITY OF THE CLAVICLE.

This accident is more frequent than the dislocation of the sternal extremity.†

When this extremity of the bone is luxated, the signs by which the surgeon ascertains the nature of the injury are as follow.

SYMPTOMS.—The shoulder on that side, when compared with the opposite, appears depressed, for the clavicle is formed to give support to the scapula, and that support is lost in consequence of the accident. The point of the shoulder approaches nearer to the sternum; and if the distance of the two shoulders from that bone be measured, this inequality is directly detected: the clavicle being naturally the means of preserving the distance of the scapula from the side, in order to throw out the shoulders, and to render the motions of the arm extensive. But the easiest mode of detecting this accident is, to place the finger upon the spine of the scapula, and to trace this portion of bone forward to the acromion in which it ends; the finger is stopped by the projection of the clavicle, and so soon as the shoulders are drawn back, the point of the clavicle sinks into its place, but it reappears when the shoulders are let go. The point of the clavicle projects against the skin upon the superior part of the shoulder, and much pain is felt when it is pressed.

* An interarticular fibro-cartilage is frequently, but not always, found in this articulation.—*Ed.*

† As a proof of the difficulty of estimating the comparative liability of these joints to dislocation, I may mention that Boyer describes the sternal end of the clavicle as being more frequently dislocated than the acromial; but I believe that Sir Astley Cooper is right.—*Ed.*

In this injury, the capsular ligament is necessarily torn through, as well as the external or trapezoid ligament, proceeding from the coracoid process to the clavicle, or no dislocation of

the sternal extremity could occur. The internal ligament, when the dislocation is complete, must be also lacerated; but I have seen the clavicle project but slightly on the acromion in some of these accidents, denoting that the latter ligament had not given way.

It must be very rare that the scapular end of the clavicle is dislocated in any other direction than upwards. At least, I have never seen an instance of the clavicle gliding under the acromion; but a case is recorded in the Archives Générales de Médecine for December 1837, and in the sixth volume of Dr. Forbes's Quarterly Review, in which it was driven under the acromion by a kick from a horse on the shoulder.

Cause.—This species of dislocation is caused by a fall upon the shoulders, through which the scapula is forced inwards towards the ribs, and the accident which produces it must be excessively violent. It has been said that the action of the trapezius muscle alone could produce this effect; but that is impossible, as this muscle would not influence both the ligaments of

* This figure displays an old dislocation of the acromial end of the clavicle, and the conoid ligament is converted into bone, so as to anchylose the clavicle to the scapula.

the coracoid process, which must be torn through to produce the dislocation.

Treatment.—In the treatment of this accident, I adopt the following plan:—The assistant, standing behind the patient, puts his knee between the shoulders, and draws them backwards and upwards, when the clavicle sinks into its socket. A thick cushion is then placed in each axilla, for three purposes:—first, to keep the scapula from the side; secondly, to raise the scapula; thirdly, to defend the axillæ from being hurt by the bandages; on which last account a cushion is employed on each side. Then the clavicle bandage is applied, and its straps should be sufficiently broad to press upon the clavicle, the scapula, and the upper part of the os humeri; so as to keep the clavicle down, the scapula inwards and backwards (which is the chief object), and the arm backwards and elevated. To secure these objects more effectually, the arm is to be suspended in a short sling, by which it is made to support the scapula in its proper situation.

At the conclusion of my lecture upon this subject I have always given this counsel to the pupils:—"You are not to expect that the parts, after the utmost care in the treatment, will, in dislocations of either end of the clavicle, be very exactly adjusted; some projection, some slight deformity will remain; and it is necessary, from the first moment of the treatment, that this should be stated to the patient, as he may otherwise suspect that the fault has arisen from your ignorance or negligence. You may at the same time inform him, that a very good use of the limb will be recovered, although some slight projection on the sternum, or some elevation of the sternal extremity of the clavicle may remain, and produce a slight deviation from the natural form of the part."

These observations are well exemplified by the following case.

Case CCXII.—Margaret Connor, æt. thirty-three, was admitted into Guy's Hospital on the 26th November 1836, under Mr. Key, with a dislocation of the acromial extremity of the clavicle, which had been caused by a fall on the shoulder. She was unable to raise the arm, and the clavicle could be felt riding over the acromion. The arm was kept up by a sling, and a figure-of-8 bandage was applied with compresses, so as to make pressure on the displaced bone. She was compelled by domestic

circumstances to leave the hospital on the 3rd of December, at which time the bone was still projecting from its place.

Dislocation of the Clavicle with Fracture of the Acromion.—We have a preparation of this injury in the Museum at St. Thomas's Hospital, and the following account of the case was given me by Mr. South.

Case CCXIII. — A man, aged sixty years, was admitted into St. Thomas's Hospital, Oct. 19th, 1814, having fallen from a tree two or three days before. The surgeon to whom he applied told him that nothing was injured; but he himself persisted in saying his shoulder was broken, and walked up from Maidstone to the hospital. On examination his shoulder appeared fallen as if displaced, but a little attention showed that this was not the case. What, however, the accident was determined to be, I do not recollect; but the following treatment was adopted Cushions were put in the axillæ, and a stellate bandage was applied; another bandage was passed round the arm just above the elbow to bind it to the side, and the arm was put in a sling, which seemed to keep the parts in their proper position; but the next morning the bandages were loose. Supposing that this effect was produced by restlessness, they were again applied, but continued slipping off, day after day, until a week from his admission, when a long splint, placed across the shoulders, was bound to them by rollers, and the parts resumed their natural situation; but after a short time, this was also obliged to be removed on account of the extreme irritability of the patient. He was then ordered to lie in bed upon his back without any bandage, but the parts became again displaced. No other attempt at relief was made, and he died on December the 7th following, of some pulmonary disease, after an illness of three weeks.

On examination of his body, the clavicle was found dislocated at its scapular extremity, and projected considerably over the spine of that bone. The acromion process, just where the clavicle is united with it, was broken off.

The splint across the shoulders seemed likely to succeed in keeping the parts in apposition, if the man's illness and impatience had permitted him to continue to wear it.

CHAPTER XI.

ON DISLOCATIONS OF THE SHOULDER-JOINT.

SECTION I.—ANATOMY OF THE SHOULDER-JOINT.

THE shoulder-joint is constituted by the glenoid cavity of the scapula, and the head of the os humeri.

The glenoid cavity is similar in form to a longitudinal section of an egg, with its larger extremity downwards and outwards, and its smaller upwards and inwards; the cavity is so superficial, that the head of the humerus rather rests upon its surface than is received into its hollow; it is, however, slightly concave, and is covered by an articular cartilage, which has a fibro-cartilaginous margin (sometimes called the glenoid ligament), whereby the cavity is somewhat deepened.

The coracoid process of the scapula is situated at the upper point of the glenoid cavity, and its basis extends from thence to the notch of the superior costa; it rises and inclines inwards and forwards, terminating in a point, which is situated under the clavicle, one-third the length of that bone from its junction with the spine of the scapula, and behind the pectoral muscle. It covers and protects the joint on its inner side.

The glenoid cavity and coracoid process are united to the body of the scapula by a narrow neck, which is called the cervix scapulæ; and its narrowest part is opposite to the notch of the superior costa of the scapula.

The head of the humerus is divided into three portions. The first is an articular surface forming a small part of a sphere, which rests upon the glenoid cavity of the scapula, and is covered with an articular cartilage. The second is a process called the larger tubercle, formed for the insertion of three muscles; it is situated on the outer side of the head of the bone, under the deltoid muscle. The third is a process called the lesser tubercle, which is situated on the inner side of the head of the bone towards the axilla; and in the usual position of the arm it is nearly in a line with the point of the coracoid process of the scapula.

Between these two tubercles is a groove, which lodges the tendon of the long head of the biceps muscle, and is termed the bicipital groove.

Immediately below the head and tubercles of the humerus the bone becomes contracted, and forms what is commonly called the neck of the humerus. More strictly speaking, it is called the *surgical neck*, because it is at this part that fracture of the upper extremity of the bone is liable to occur; whereas the real neck of the humerus (or anatomical neck, as it is called), that is to say, the part which is analogous to the neck of the femur, is a mere circular depression between the head of the bone and the tubercles.

The capsular ligament of this joint surrounds the head of the bone, and is attached to the whole circumference of the edge of the glenoid cavity, excepting where the tendon of the biceps muscle passes under it; and at that point it arises from a ligament which proceeds from the coracoid process to the edge of the glenoid cavity. The capsular ligament is also fixed to the circumference of the head of the humerus, just below its articular surface. This ligament is not of an uniform thickness; but at those parts where the joint is not defended from injury by the tendinous insertions of muscles, the capsular ligament itself is thickened, and is capable of sustaining great violence; and this difference is remarkably shown in that part of the ligament which is placed in the axilla, where it is of a strong tendinous nature.

There are four muscles closely connected with the shoulder-joint, which are destined to strengthen the capsular ligament, and maintain the head of the humerus in its socket, and hence have received the name of capsular muscles. The first, the supra-spinatus, which arises from the fossa supra-spinata, covers the head of the bone, blends its tendon with the capsular ligament, and is inserted into the larger tubercle; the second, the infra-spinatus muscle, which proceeds from the fossa infra-spinata, adheres to the back part of the capsular ligament, and is also fixed to the greater tubercle; the third, the teres minor, which arises from the lower edge of the scapula, adheres to the back part of the capsular ligament, and is likewise inserted into the greater tubercle, and into the cervix humeri. The fourth is the subscapularis muscle, which fills up the venter of the scapula: it passes over the inner side of the head of the bone, and is fixed

to the smaller tubercle, firmly adhering to the capsular ligament as it passes over its inferior and inner surface. It is between the subscapularis muscle and the teres minor that the capsular ligament is found of great strength, as there are no muscles inserted into that part to protect the joint from injury.

The deltoid muscle, the coraco-brachialis, and the teres major, which are also muscles of this joint, are not united with the capsular ligament as the other muscles, being only destined for the motion, and not particularly for the protection of the shoulder-joint.

The tendon of the long head of the biceps protects the upper part of the joint, where it otherwise would be weak; for this tendon is situated between that of the supra-spinatus and subscapularis.* It arises from the fibro cartilaginous brim of the upper point of the glenoid cavity of the scapula, and passes over the head of the bone into the groove between the two tubercles. It is contained within the capsular ligament, and is covered by a reflection of the synovial membrane.

The shoulder-joint has a greater extent and variety of motion than any other joint in the body; and its dislocations are, consequently, more frequent than those of all the other joints in the body collectively: those of the ankle-joint being next in frequency.

VARIETIES OF DISLOCATION. — The head of the humerus is liable to be thrown from the glenoid cavity of the scapula in four directions; three of these luxations are complete, and one is partial only.

DOWNWARDS AND INWARDS. — The *first* is downwards and inwards; it is usually called the dislocation into the axilla, and in this accident the bone rests upon the inner side of the inferior costa of the scapula.

FORWARDS. — The *second* is forwards under the pectoral muscle, when the head of the os humeri is placed below the middle of the clavicle, and on the sternal side of the coracoid process.

* The Editor has great pleasure in referring his readers to a paper by Mr. John Soden, jun. of Bath, on two cases of dislocation of the biceps tendon from its groove, in the twenty-fourth volume of the Medico-Chirurgical Transactions, for some ingenious observations on the functions of this tendon in preventing the head of the humerus from being dragged above its natural level by the capsular muscles. An abstract of this paper is given in a future page.

BACKWARDS. — The *third* is the dislocation backwards, when the head of the bone can be both felt and distinctly seen, forming a protuberance on the back and outer part of the inferior costa of the scapula, and situated upon its dorsum.

PARTIAL DISLOCATIONS.—The *fourth* is only partial, when the anterior portion of the capsular ligament is torn through, and the head of the bone is found resting against the coracoid process of the scapula, on its outer side.

It has been supposed that a dislocation of the os humeri upwards might occur, but it is obvious that this could only happen under fracture of the acromion. It is an accident which I have never seen.*

Of the dislocation into the axilla I have seen a multitude of instances; of that forwards on the inner side of the coracoid process, several, although these are much less frequent than that in the axilla; of the dislocation backwards I saw only two instances during thirty-eight years. I do not believe in any change of place after dislocation, when the muscles have once contracted, (except from subsequent violence, which is very uncommon,) beyond that slight change which pressure, by producing absorption, will sometimes occasion. The bone is generally at once thrown into the situation which it afterwards occupies; so that, excepting from circumstances of great violence, the nature and direction of the dislocation are not subsequently changed.

SECTION II.

DISLOCATION INTO THE AXILLA.

SYMPTOMS.—The usual signs of this dislocation are as follow: A hollow is produced below the acromion, by the displacement of the head of the humerus from the glenoid cavity, and the natural roundness of the shoulder is destroyed, because the deltoid muscle is flattened and dragged down with the depressed head of the bone. The arm is somewhat longer than the other,

* Of partial dislocation upwards, in connexion with displacement of the tendon of the biceps from its groove, Mr. Soden's case, at the end of this chapter, affords an example.—*Ed.*

as the situation of the bone upon the inferior costa of the scapula is below the level of its natural situation in the glenoid cavity. The elbow is with difficulty made to touch the patient's side, from the pain produced in this effort by pressure of the head of the bone upon the nerves in the axilla; and upon this account it usually happens, that the patient himself supports his arm at the wrist or fore-arm with the other hand, to prevent its weight pressing upon these nerves. The head of the os humeri can be felt in the axilla, but only if the elbow be considerably removed from the side. I have several times seen surgeons deceived in



these accidents, by thrusting the fingers into the axilla when the arm is close to the side, when they have directly said, "this is not a dislocation;" but upon raising the elbow, the head of the bone could be distinctly felt, for that movement throws the head of the bone downwards, and more into the axilla.

The motion of the shoulder is in a great degree lost, more especially in the direction upwards and outwards, for the patient can no longer raise his arm by muscular effort, and even the surgeon generally finds some difficulty in overcoming its fixed

position; it is usual, therefore, as a first question in detecting dislocation, to ask the patient if he can raise his arm to his head, and if there be dislocation, the answer is invariably that he cannot. The power of rotation of the arm is also lost; but the motion of the limb forwards and backwards, as it hangs by the side, is still preserved. There is, however, great difference in respect to the motion of the limb, and this depends upon the age of the patient and the tone of the muscles; because, if the muscles are relaxed and flabby, the surgeon may be able to move the arm freely, and to raise it up to the head, and even to press the elbow to the side. On moving the limb, a slight crepitus will sometimes be felt from effusion of serum, and from the escape of synovia into the cellular tissue; but by the continuance of the motion this soon ceases; the crepitus, however, in these cases, is never like the rough grating which fracture produces. The central axis of the arm is changed, for the central line runs into the axilla.

In this accident, numbness of the fingers frequently occurs, from the pressure of the head of the bone upon a nerve or the nerves of the axillary plexus.*

These are the circumstances of greatest moment; but it will be seen that the accident can be detected principally by the fall of the shoulder, by the presence of the head of the bone in the axilla, and by the loss of the natural motions of the joint. But a few hours make these appearances much less decisive, from the extravasation of blood, and from the excessive swelling which sometimes ensue; but when the effused blood has become absorbed, and the inflammation has subsided, the marks of the injury become again decisive. At this latter period it is that surgeons of the metropolis are usually consulted; and if we detect a dislocation which has been overlooked, it is our duty, in candour, to state to the patient, that the difficulty of detecting the nature of the accident is exceedingly diminished by the cessation of inflammation, and the absence of tumefaction.

It may be also observed, that there is great difference in the facility with which the accident is discovered in thin persons of advanced age, and in those who are loaded with fat, or who

* The circumflex nerve is more especially, as Boyer observed, liable to be overstretched, so as to paralyse the deltoid muscle.—*Ed.*

have, by constant exertion, rendered their muscles excessively large.

Dissection.—I have dissected two recent cases of this dislocation. A sailor fell from the yard-arm on the ship's deck, injured his skull, and dislocated the arm into the axilla. He was brought into St. Thomas's Hospital in a dying state, and expired immediately after he was put into his bed. On the following day I obtained permission to examine his shoulder, which I removed from the body for the purpose of obtaining a more minute examination, and the following were the appearances which I found. On removing the integuments, a quantity of extravasated blood presented itself in the cellular membrane, lying immediately under the skin, and in that which covers the axillary plexus of nerves, as well as in the interstices of the muscles, extending as far as the cervix of the humerus, below the insertion of the subscapularis muscle.

The axillary artery, and plexus of nerves, were thrown out of their course by the dislocated head of the bone, which was pushed backwards upon the subscapularis muscle. The deltoid muscle was sunken with the head of the bone. The supra and infra spinati were stretched over the glenoid cavity and inferior costa of the scapula. The teres major and minor had undergone but little change of position; but the latter, near its insertion, was surrounded by extravasated blood. The coraco-brachialis was uninjured. In a space between the axillary plexus and coraco-brachialis, the dislocated head of the bone, covered by its smooth articular cartilage and by a thin layer of cellular membrane, appeared. The capsular ligament was torn on the whole length of the inner side of the glenoid cavity, and would have admitted a much larger body than the head of the os humeri through the opening. The tendon of the subscapularis muscle, which covers the ligament, was also extensively torn. The opening of the ligament, through which the tendon of the long head of the biceps passed, was rendered larger by laceration, but the tendon itself was not torn. The head of the os humeri was thrown on the inferior costa of the scapula, between it and the ribs; and the axis of its new situation was about an inch and a half below that of the glenoid cavity, from which it had been thrown.

The second case which I had an opportunity of examining was

one in which the dislocation had existed five weeks, and in which very violent attempts had been made to reduce the dislocated bone, but without success. The subject of the accident was a woman fifty years of age. All the appearances were distinctly marked; the deltoid muscle being flattened, and the acromion pointed; the head of the bone could also be distinctly felt in the axilla; the skin had been abraded during the attempts at reduction, and the woman apparently died from the violence used in the extension. Upon exposing the muscles, the pectoralis major was found to have been slightly lacerated, and blood was effused amongst its fibres; the latissimus dorsi and teres major were not injured; the supra-spinatus was lacerated in several places; the infra-spinatus and teres minor were torn, but not to the same extent as the former muscle. Some of the fibres of the deltoid muscle and a few of those of the coraco-brachialis had been torn; but none of the muscles had suffered so much injury as the supra-spinatus. The biceps was not injured.

Having ascertained the injury which the muscles had sustained in the extension, and, in some degree, the resistance which they opposed to it, I proceeded to examine the joint.

The capsular ligament had given way in the axilla, between

the teres minor and subscapularis muscles; the tendon of the subscapularis was torn through at its insertion into the lesser

tubercle of the os humeri, and the head of the bone rested upon the axillary plexus of nerves and the artery. Having determined these points by dissection, I next endeavoured to reduce the bone, but finding the resistance too great to be overcome by my own efforts, I became very anxious to ascertain its origin. I therefore divided one muscle after another, cutting through the coraco-brachialis, teres major and minor, and infra-spinatus muscles; yet still the opposition to my efforts remained, and with but little apparent change. I then conceived that the deltoid must be the chief cause of my failure, and by elevating the arm, I relaxed this muscle; but still could not reduce the dislocation. I next divided the deltoid muscle, and then found the supra-spinatus muscle my great opponent, until I drew the arm directly upwards, when the head of the bone glided into the glenoid cavity. The deltoid and supra-spinatus muscles are those which most powerfully resist reduction in this accident.

Practical inferences.—It appears from these dissections, that the best direction in which the arm can be extended for reduction, is at a right angle with the body, or directly horizontally, rather than obliquely downwards; as the deltoid, and supra and infra spinati muscles, are, in this position of the limb, thrown into a relaxed state, and these muscles are, as I have explained, the principal sources of the resistance. The biceps is to be relaxed by slightly bending the elbow. The arm may be extended directly outwards, in the line between the pectoralis major on the outer side, and the latissimus dorsi and teres major on the inner; but if there be any deviation from this line, it will be better rather to advance the arm, to lessen the power of the pectoralis major.

This dissection explains the reason why the arm is sometimes easily reduced soon after the dislocation, by raising it suddenly above the horizontal line, and placing the fingers under the head of the bone, so as to lift it towards the glenoid cavity, which, as every tyro knows, will sometimes prove effectual, because, in this position, the muscles are relaxed so as no longer to offer any resistance to reduction.

Dissection of a Dislocation which had been long Unreduced.—The head of the bone is found altered in its form; the surface towards the scapula being flattened. A complete capsular ligament environs the head of the os humeri. The glenoid

cavity is entirely filled by ligamentous matter, in which are suspended small portions of bone, which are of new formation, as no portion of the scapula or humerus is broken. A new cavity is formed for the head of the os humeri on the inferior costa of the scapula; but this is shallow, like that from which the os humeri had escaped.

The common causes of dislocation of the os humeri into the axilla are, falls upon the hand while the arm is raised above an horizontal line, by which the head of the bone is thrown downwards; also, falls upon the elbow, when the arm is raised from the side; but the most frequent cause is a fall directly upon the shoulder on some uneven surface, by which the head of the bone is driven downwards, whilst the muscles are unprepared to resist the shock.

When the arm has been once dislocated, if great care be not taken of the limb after its reduction, it is extremely liable to a recurrence of the accident. I remember, particularly, a carpenter, who used to be a frequent visitor at Guy's Hospital for several years, for the purpose of having his shoulder reduced. Slighter causes than that which originally produced it, will renew the dislocation; I have known it to recur from the act of throwing up the sash of a window. During my apprenticeship at St. Thomas's Hospital, in going through the wards early one morning, I was directed to see a man who had just dislocated the shoulder, which he had frequently done before, as he was lying in bed; and upon inquiring how it had happened, the man replied, that it occurred merely in the effort of rubbing his eyes and stretching himself upon waking. This disposition to the recurrence of dislocation may be prevented, by directing that the arm be kept fixed close to the side, and the shoulder rather elevated by a pad in the axilla, for three weeks after its reduction; during which time the ruptured tendon of the subscapularis

and the capsular ligament will be united: a process which motion greatly impedes, if not wholly prevents.

The following case, which I received from Mr. Stedman, illustrates my remarks respecting the degree of mobility in this dislocation if the muscles are relaxed.

Case CCXIV.—John Mahony, æt. fifty-five, a thin, emaciated, debilitated man, three days before admission into the hospital had a fall, by which he injured his right shoulder. On examination, the right shoulder was observed hanging down, the elbow projected slightly from the side, and there was a hollow under the acromion, in which the finger could be placed; and there were the other usual signs of dislocation of the humerus into the axilla; but there was a very great degree of motion, and the *elbow could readily be pressed to the side*, without complaint on the part of the patient. The reduction was effected by the heel in the axilla with unusual ease; and he left the hospital at the end of the week with good use of the arm.

For the next case the Editor is indebted to Mr. Bedford.

Case CCXV.—A man, aged forty, was admitted into Guy's Hospital in July 1839, with dislocation of the humerus downwards and inwards into the axilla. The same accident had happened to him three times before. The trunk and scapula were fixed, and extension was made from above the elbow, with the heel in the axilla, for half an hour, with no effect. In two hours' time the same means were again tried without avail. He then took three doses of tartarized antimony, at half hour intervals; and again the same means were employed. On this occasion, after continuing extension for five minutes, the bone slipped into its place. The arm was then placed in a sling, some leeches were applied to the shoulder-joint, and in three days he left the hospital quite well.

Case CCXVI.—James Murry, about forty years of age, was brought into Guy's Hospital early on the morning of the 17th of July, with dislocation of the humerus into the axilla, which had happened two hours previously; he having, as he stated, suddenly waked by starting in his sleep, and found his arm put out. He has been constantly subject to this accident, which he has generally been able to reduce himself; once, however, he was obliged to have the assistance of eight men in St. Bartholomew's Hospital. Two grains of solid opium were

given upon his admission, which produced no narcotic effect within an hour and a half, but had created nausea and slight vomiting. An attempt was now made to reduce the dislocation, as the muscles seemed to relax, and allowed the bone to be moved, but not sufficiently for reduction. The man was placed on his back whilst further measures were being devised, and in attempting to raise himself, the reduction was spontaneously effected.

Case CCXVII.—A muscular gentleman, aged fifty-four, fell from his horse and dislocated his shoulder, which was not reduced. He consulted me five months afterwards; and I strongly advised him against any further attempt.

Case CCXVIII.—A man, fifty years of age, who had dislocated his shoulder into the axilla, two months before, was subjected to very violent and long continued efforts at reduction, which at last succeeded in returning the head of the bone to its cavity. The patient, however, was extremely exhausted by the operation, and a few hours afterwards died.

On dissection it was found that the head of the bone had been dislocated into the axilla, an inch and a half below the glenoid cavity, where it had formed for itself a white, ligamentous, cup-like socket in the subscapularis muscle. The axillary artery was completely adherent to this socket, and had been torn across during the efforts at reduction. The parts about the shoulder, and the arm as far as the elbow, were stuffed with extravasated blood.*

Case CCXIX. — An old woman, in carrying a load of water, fell and dislocated her shoulder. The head of the humerus (which lodged in the axilla) was with great facility replaced, and for many days she went on perfectly well; the sensation of the limb was however much impaired, and its motion, even that of the fingers, altogether destroyed. After a few days the limb enlarged, and exhibited exactly the appearance of phlegmasia dolens of the lower extremity. About the tenth or twelfth day, a small swelling was perceived in the axilla; this continued for some weeks to increase in size, but without pain, without discoloration of the integuments, and without pulsation. At the end of two months the skin became changed, and soon afterwards it ulcerated, and a small quantity of coagulated blood was from day

* Lancet, vol. iii. p. 92. The case was under the care of Dr. Gibson, of Pennsylvania.

to day discharged. One morning, when she was sitting in bed and about to get up, violent hæmorrhage suddenly came on, and in a few moments she expired. I did not see the patient during life, but learnt these particulars by calling accidentally on a medical man under whose care she had been. She was just then dead, and by his permission, and in his presence, I had an opportunity of examining the parts. I found a very large cavity extending from the axilla to the shoulder-joint, bounded by the pectoral muscle before and the latissimus dorsi behind; this was filled by blood, mixed with large quantities of coagulable lymph, and communicated with a rupture of the posterior part of the axillary artery.

This case was sent me, in the year 1813, by Mr. Bellingham, of Uckfield. The artery was no doubt previously diseased and rigid, and was ruptured by the dislocated bone. From the facility with which the displacement was reduced, it is very improbable that it was ruptured during the reduction; although, as we have before said, this accident has happened during injudicious and violent attempts to replace a dislocation of long standing.

Treatment.—Various have been the means suggested for the reduction of the head of the humerus, when dislocated downwards into the axilla. The first plan, and that which I usually adopt in my private practice in all recent cases, is

By the Heel in the Axilla: and the best mode of its application is as follows:—The patient should be placed in the recumbent posture, upon a table or a sofa, near to the edge of which he is to be brought; the surgeon then binds a wetted

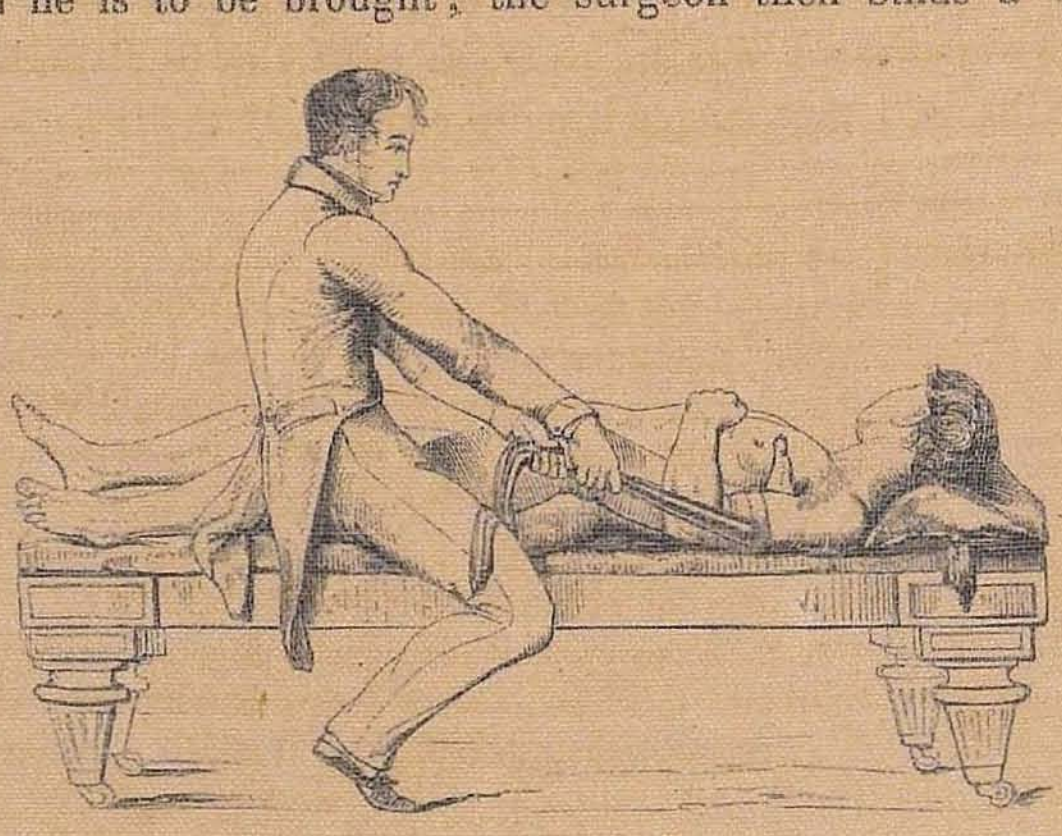

roller round the arm immediately above the elbow, upon which he ties a handkerchief;* then, with one foot resting upon the floor, he separates the patient's elbow from his side, and places the heel of his other foot in the axilla, receiving the head of the os humeri upon it, whilst he is himself in the sitting posture by the patient's side. He then draws the arm by means of the handkerchief, steadily for three or four minutes, when, under common circumstances, the head of the bone is easily replaced; but if more force be required, the handkerchief may be changed for a long towel, by which several persons may pull, the surgeon's heel still remaining in the axilla. I generally bend the fore arm nearly at right angles with the os humeri, because it relaxes the biceps, and consequently diminishes its resistance. I have, in many cases, extended from the wrist, by tying the handkerchief just above the hand, but more force is required in this than in the former mode, although it has this advantage, that the bandage is less liable to slip. In recent cases it very rarely happens that this mode of extension fails, and it is so easily applied in every situation, that I have recommended all our young men to employ it in the first instance, when called to this accident.†

By manual extension.—But in those cases in which the muscles are of very considerable strength, and the dislocation has existed for several days, so that they have become permanently contracted, and the limb is strongly fixed in its new situation, more force is required, and the following means should be employed. The patient must be placed upon a chair,‡ and the scapula be fixed by means of a bandage, which allows the arm to pass through it: that which we use at our hospital is a girt buckled on the top of the acromion, so as to raise the bandage high in the axilla, and thus enable it more completely to *fix the scapula*,

* It is better for the surgeon to make the extension from the patient's wrist, which he should grasp with one hand.—*Ed.*

† The great advantage of this mode of reduction is, that the surgeon, both at the long end of the lever, and at the fulcrum, has his sense of touch to appreciate the effect of the force upon the resistance, and, therefore, is able at once to modify its application as circumstances may require. Whilst extending the patient's wrist, and counter-extending by his heel, he immediately perceives the slightest change in the position of the head of the bone; and, therefore, as soon as the heel detects the slightest motion of the head of the bone, he can simultaneously, by the lever, direct it towards the glenoid cavity.

‡ In all cases, I believe it better to place the patient in the recumbent posture, as he is then deprived of every fixed point from which he may exert his own muscular power.—*Ed.*

which is the principal object to be attended to, as otherwise all efforts will be inefficient. When I first saw this mode of reduction adopted thirty-eight years ago, a round towel was used instead of this bandage, which was placed in the axilla, and crossed the chest; but it appeared to me that by this means the lower angle of the scapula alone was fixed, and that the glenoid cavity was drawn with the arm when extension was made; I directed, therefore, that the towel should be tied over the opposite shoulder with a handkerchief, so that it should be raised in the axilla on the injured side, and thus embrace a larger surface of the scapula; but still I found the scapula drawn from the side with the arm, and therefore had the bandage made as described. A wetted roller is next to be bound around the upper arm just above the elbow, from which situation it cannot slip, and upon this a very strong worsted tape is to be fastened, by the knot called the clove hitch, which is shown in the accompanying figure. The arm should then be raised at right angles with the body, and if there be much difficulty in the reduction, it should be elevated above the horizontal line, more completely to relax the deltoid and supra-spinatus muscles. Two persons should then draw from the bandage affixed to the arm, and two from the scapula bandage, with a steady, equal, and combined force; jerking should be entirely avoided, and every aim at quick reduction should be discountenanced: "*slowly and steadily*" should be the word of command from the surgeon; who, after the extension has been kept up for a few minutes, should place his knee in the axilla, resting his foot on the chair upon which the patient sits; he should then raise his knee by extending his foot, and placing his right hand upon the acromion, push it downwards and inwards, when the head of the bone will usually slip into its natural position. Whilst the extension is proceeding I have seen a gentle rotatory motion of the arm diminish opposition of the muscles, and the bone suddenly slip into its place.



But when a limb has remained a considerable length of time dislocated; when the muscles are so powerfully contracted that the force of men cannot be so steadily exerted as to reduce the limb; because, after several attempts, both the minds and bodies of the assistants become fatigued, and their efforts violent and unequal, then we employ the third mode of reduction.

By the Pulleys.—And here let it be understood that they are not adopted with a view of employing greater force, for that might be obtained by the aid of more persons; but they are introduced to enable the surgeon to employ the force gradually and equally; to avoid jerks and unequal extension, which, in protracted cases, the efforts of men are sure to produce. If, therefore, I saw a surgeon, as soon as the pulleys were fixed, draw them violently, and endeavour suddenly to reduce the limb,



I should not hesitate at once to say, "that gentleman is ignorant of the principle upon which this mechanical power is employed, and has still this part of his profession to learn." For the application of the pulley the patient sits between two staples, which are screwed into the wainscot on each side of him; the bandages are then applied, precisely as in the former mode, in which the extension is performed by men, and the force is applied in the same direction; the surgeon should first draw the pulley, as the class of people usually summoned to his assistance, being ignorant of the principle upon which it is employed, would use too

great violence; he should draw gently and steadily, until the patient begins to complain of pain, and then cease, keeping up the degree of extension, and conversing with the patient to direct his mind to other objects. In two or three minutes, more force should be applied, and be continued until pain be again complained of, when the surgeon should again cease to increase the force; and thus he should proceed for a quarter of an hour, at intervals slightly rotating the limb. He should, when he has applied all the extension he thinks right, give the string of the pulley to an assistant, desiring the existing degree of extension to be supported; then, putting his knee in the axilla, and resting his foot upon the chair, he should gently raise and push up the head of the bone towards the glenoid cavity, and it probably will pass into its socket; this takes place generally without the snap which is heard when other means are employed, yet both the surgeon and the patient are aware of some motion of the head of the bone at the time.* If the pulleys be employed as above, the extension will be conducted infinitely more steadily and effectually than when performed by men. In my hospital practice I order the patient to be bled, and to be put into a warm bath at the temperature of 100° to 110°; and I give him a grain of tartarized antimony every ten minutes until he becomes faint; then I order him to be removed from the bath, to be wrapped in a blanket, and immediately placed upon the chair for extension, before his muscles have had time to recover, which expedient lessens the necessity of employing very considerable force. Mr. Henry Cline, surgeon to St. Thomas's Hospital, who was son to my most excellent master, and who would have made an excellent practical surgeon if the hand of death had not prematurely deprived the world of his useful talents, was in the habit of directing his patients to support a weight for a length of time before the extension was begun, with a view of fatiguing the muscles, and lessening their power of resistance. In apartments where it is not convenient to place the pulleys in the walls, I have fixed them in the floor, on each side the patient, who must under these circumstances, sit upon the floor. When the reduction has been effected, a small cushion should be placed

* One of our pupils, Mr. Bartlett, of Ipswich, has invented a small spring, by means of which the strings are attached to the pulley, and which can suddenly detach them whilst the knee is in the axilla. This instrument may sometimes be useful.

in the axilla, and fixed there by a stellate, or figure-of-8 bandage, to prevent the head of the bone again slipping from its situation, which the excessive relaxation of the muscles would readily permit; but the cushion should not be so large as to separate the arm far from the side. A sling is to be also worn to support the arm.

There is still a fourth mode of reducing the dislocation into the axilla, which is applicable to recent dislocations, to delicate females, and to very old, relaxed, and emaciated persons, viz:

By the Knee in the Axilla.—The patient being seated upon a low chair, the surgeon places himself by him, and separates the

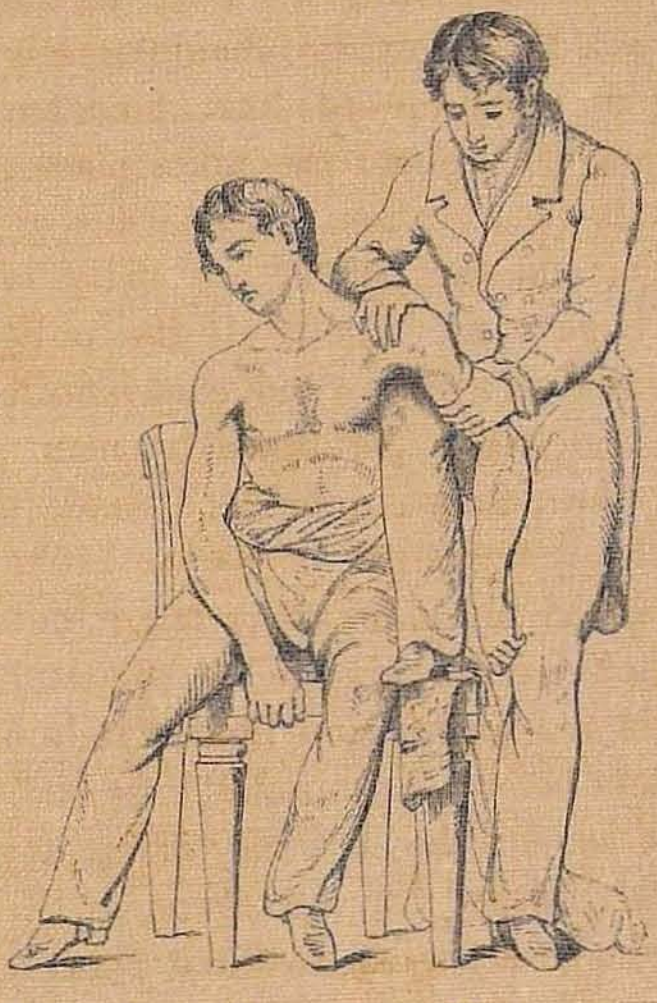

dislocated arm from the side sufficiently to admit his knee into the axilla; his foot being placed upon the side of the chair. He grasps the humerus, just above the elbow, with one hand, and presses upon the acromion scapulæ with the other; he then pulls down the arm over the knee, and in this manner reduces the dislocation. Even in persons of powerful muscles, I have known this mode succeed, when the patient remained in the state of intoxication, in which he was found when the accident happened.*

The Ambe.—The ambe has been recommended for the reduction of dislocations in the axilla, and this instrument was, in the

* This is not nearly so good a plan as the heel in the axilla, as the knee is too large a point to sufficiently concentrate the force towards the head of the bone.—*Ed.*

last century, improved by the addition of a screw for the purpose of rendering its extension more gradual. It may succeed very well in recent cases, and in those persons whose muscles are not very powerful; but when a continued extension must of necessity be used to reduce the bone, as its fixed point of action is upon the ribs of the patient, it produces too much injury to the side, is too painful to be borne long, and is, therefore, an instrument which cannot be recommended for general use.*

Mr. Kirby, surgeon in Dublin, has lately advised the following ingenious mode of applying force in dislocations of the shoulder. The scapula being fixed and the bandage applied to the arm, the patient sits upon a mattress which is laid upon the floor, and the assistants, to whose management the extension and counter-extension are consigned, place themselves at his sides, sitting opposite to each other, and disposing their legs so that the soles of their feet are opposed to each other, behind and before the patient. If occasion should require a greater force than the power of two men, the assistants may be increased by placing one or more at the backs of the other two, sitting close up to them with their faces turned towards the patient; the extension is now made, with the arm raised nearly to a right angle with the body, and in the direction forwards or backwards, as the circumstances of the case may require. The force should be maintained until it is perceived that the head of the bone (which can be easily felt, and should be pressed upon during the operation) has moved from its new situation; and when the head of the bone is found to change its position, the assistants should slowly diminish their force while the surgeon directs it towards the glenoid cavity, by pressing the elbow to the side of the patient and slightly raising it.

When a person has frequently dislocated his shoulder, a very slight effort is sufficient to restore the limb to its place.

Case CCXX. In 1810, whilst the Editor was living with Mr. Colman, of Norwich, a Mr. Clark, a farmer in the neighbourhood, was liable to the frequent recurrence of the dislocation of his humerus into the axilla, from very slight causes; it often happened on putting on his coat. Upon one occasion, plunging into the water for the sake of bathing, he dislocated his arm, and

* The most ingenious modification of this instrument is that made by Savigny, of St. James's Street, and delineated in Mr. Chapman's work on Bandages; but it is never used at the present day.—*Ed.*

had he not been an excellent swimmer, would probably have been drowned. Whenever this accident occurred, he used to order his gig, and drive to Mr. Colman's, six miles from his house, to have his dislocation reduced, for which we used to charge him two guineas. Mr. Clark got tired of this continued expence, and began to think if he could not save his money by officiating for himself; and it struck him that a five-barred gate would form an efficient apparatus for the purpose, and his conjecture proved perfectly correct; for ever after directly his arm was out, he used to run to the gate, and standing on the lower bar, leaned over the top, so as to lay hold of the third bar on the opposite side; then letting his feet slip from their support, the whole weight of his body became suddenly supported by the head of the humerus in the axilla, and thus forced it into the glenoid cavity. Mr. Clark used to laugh at Mr. Colman every time he met him, as having succeeded at last in what he designated "doing the doctor;" a joke Mr. Clarke enjoyed much more than Mr. Colman.

This mode of reduction is the same in principle as that of the heel in the axilla, which, as I have already mentioned, in three-fourths of recent dislocations, is the best for effecting the reduction.*

* There is yet another mode of effecting the reduction of these dislocations, which I will mention in order to render this part of the subject complete. It is a mode which was invented by Mr. White, of Manchester, about the middle of the last century, and which has been revived latterly by M. Malgaigne in

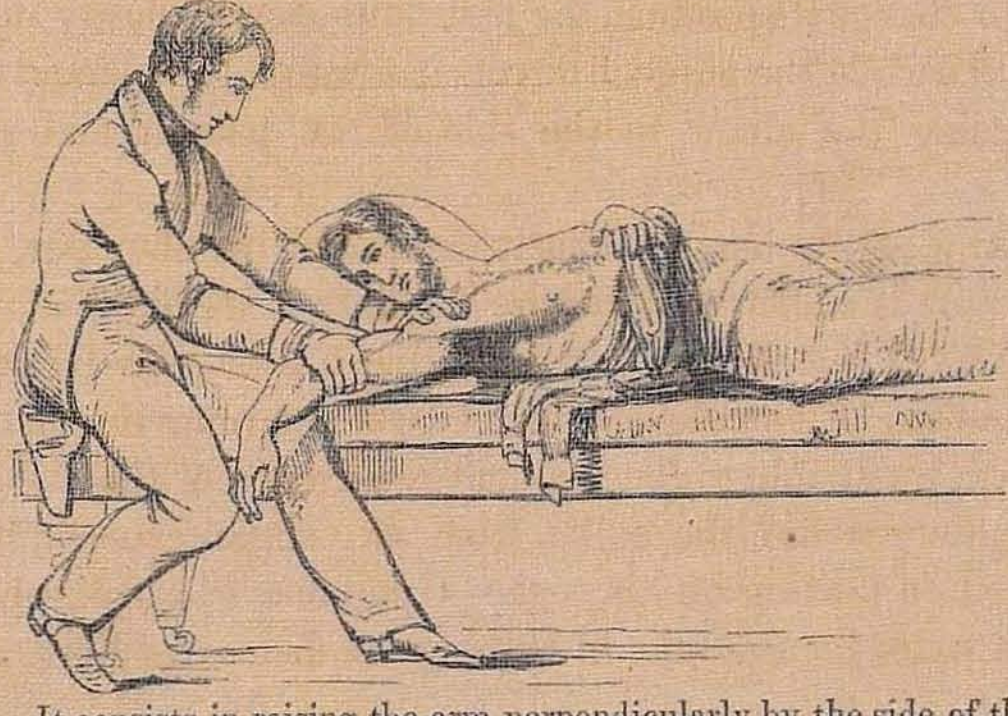

France. It consists in raising the arm perpendicularly by the side of the head; by which means the supra-spinatus muscle (which Sir Astley Cooper has shown to be the principal antagonist to the reduction,) is completely relaxed,

With regard to the time after which it would be unsafe to attempt reduction of this dislocation, I must refer the reader to the introductory chapter; where he will find it stated that as a *general rule* it ought not be thought of after twelve weeks. With respect also to the treatment of an irretrievably dislocated limb, I can only recapitulate what I said in the introduction; namely, that constant exercise of the part, with friction, and passive motion, are the measures most calculated to restore its proper functions.

Case CCXXI. — On the 26th of March, 1830, Mr. H. was thrown from his horse, upon his left shoulder and arm, and thereby dislocated the os humeri into the axilla. The surgeon who usually attended his family was immediately sent for, and came, with his son, who is also a surgeon, in about an hour after the accident occurred. To them Mr. H. expressed his apprehension that his shoulder was dislocated; but they, after a minute examination, declared that such was not the case, but that he had only received a violent bruise. They ordered leeches and poultices to prevent inflammation, and they were accordingly applied. Afterwards a cold lotion was applied for several days, which, with a liniment a few days afterwards, was the only application. They several times examined the shoulder and arm, and constantly asserted that the only injury received was a bruise of the large muscle on the shoulder. One, and sometimes both of them, visited him every day; the lotion and liniment being continued, and two or three bottles of medicine and powders administered. Having been previously assured that he might do so with safety (his arm being in a sling all this while), Mr. H. went into Cornwall on the 21st of April, whence he returned on the 9th of May. On the following day, being still in pain, and not having the free use of his arm, he obtained the advice of a physician, who immediately told him that his shoulder was dislocated, and

and the head of the humerus is drawn directly upwards into its cavity. This has sometimes been effected by means of a set of pulleys affixed to the ceiling, by which the arm is raised perpendicularly, whilst the scapula is fixed by a towel or girth properly applied to the shoulder, and secured to the floor. But a more simple method, and one that will answer every purpose if the muscles are tolerably relaxed, is that which is represented in the cut; the surgeon sitting behind the patient, elevating the arm with one hand, and with the other fixing the scapula, which is also to be further secured by a round towel passing from the shoulder to the foot of the bed. For cases, see the Gazette Médicale de Paris, for 1832, p. 744.—*Ed.*

suggested the propriety of calling in some other surgeon to examine it, who gave the same opinion. Two physicians and four surgeons afterwards examined it; and after a consultation together, they recommended his undergoing an operation with a view to the reduction of the dislocated bone. He submitted to their judgment; and on the Friday following, being seven weeks after the accident, three surgeons, assisted by three other gentlemen, attempted the reduction with the pulleys twice, but without effect, although the first extension was protracted for more than an hour, and the second, which was half an hour after, continued for two hours, and great force was used. Previously to the attempt he was bled, and an emetic was administered to him, but without effect. His arm was very much lacerated above the elbow by the bandages, and a surgeon attended to dress it twice every day for upwards of a fortnight: it is now healed over; but the arm just above and close to the elbow continues quite hard, and he cannot straighten it. He has lived very low ever since, his drink being only water. He is a man of a full habit, rather corpulent, very strong muscles, and forty-five years of age. Indeed there are very few men to be met with who possess such bodily strength.

Would Sir Astley Cooper, under these circumstances, advise him to submit to another attempt with a view to reduction, now at the distance of nearly *eleven weeks* from the time of his accident, and nearly four weeks from the former attempts at reduction?

If not, what course had he better adopt with the view of regaining as much as possible the use of his arm, and to remove the hardness above the elbow, which prevents his straightening his arm?

I advised against any further attempt at reduction.

The following is a description of the state of a limb which had been long dislocated, and respecting which I was consulted by Mr. Bontflower, of Colchester.

Measuring from the point of the acromion to the elbow, the dislocated arm is three-quarters of an inch shorter than the other. The arm is somewhat shrunk in size; but there seems to be as much strength in the muscles of the fore-arm as in the other. The hand cannot be lifted higher than just to touch the lower part of the cheek, but in all other respects the motion is

quite free. The hand, when the arm is hanging down, appears to be turned out of its natural position.

Case CCXXII. — A gentleman from Monmouth, a short and very stout man, consulted Mr. B. Cooper respecting an unreduced dislocation of the humerus, which had existed three months. All the usual signs of dislocation into the axilla were present, the strongest diagnostic mark, however, being the distance at which the elbow was thrown from the side. On examining the glenoid cavity, says Mr. Cooper,* by pressing my finger into the depression under the acromion, I could discover that little or no alteration had taken place in this articular surface, and considered, therefore, that if the reduction could be effected, the joint would be restored to its natural function.

The reduction was effected by means of twice bleeding, the exhibition of tartar emetic, and extension by the pulleys for an hour; after which the head of the bone became obedient to the power, and was restored to its cavity by placing the heel in the axilla, and extending the arm from the wrist. Frequently, during the extension, I addressed myself to the patient, and kept up a kind of conversation with him; and he afterwards told me that he could distinctly feel that he lost all voluntary power over his muscles whilst he was obliged to continue the dialogue; and that the necessity of conversation seemed to reduce him more than even the tartar emetic.

The following case, about which I was consulted by Mr. Peck, of Newmarket, was unfortunate; but the want of success was owing to the patient's obstinacy, and not to any fault of Mr. Peck.

Case CCXXIII.—A patient of mine met with a fall from a horse, dislocated his right shoulder, and at the same time fractured the os humeri. I waited six weeks for the union of the bone, and on Wednesday last attempted the reduction, with the assistance of an older practitioner, but unfortunately failed. He took ten grains of tartar emetic in divided doses, was put in a hot bath, and bled to syncope; the compound pulleys and jack towel were applied, very powerful extension was made, and at the moment when we flattered ourselves that the muscles were about to give way, the door-post came down to which the hook was screwed; and, as might be expected, our patient would not submit to another trial, nor will he ever be persuaded.

* Surgical Essays, p. 203.

SECTION III.

DISLOCATION FORWARDS, UNDER THE CLAVICLE.

SYMPTOMS.—This species of dislocation is much more distinctly marked than the former. The acromion is more pointed, and the hollow below it, from the depression of the deltoid muscle, is much more considerable. The head of the os humeri can



be readily and distinctly felt, and even seen, in thin persons, just below the clavicle; and when the arm is rotated from the elbow, the protuberance may be observed to be obedient to the motions of the arm.

The coracoid process of the scapula is placed on the outer side of the head of the bone, which is covered by the pectoralis major muscle. The arm is somewhat shortened, and the elbow is thrown more from the side, and further back, than in dislocation into the axilla. The axis of the limb is much altered, being thrown inward towards the middle of the clavicle.

The pain attending this accident is slighter than when the

head of the os humeri is thrown into the axilla, because the nerves of the axillary plexus are less compressed; but the motions of the joint are much more materially affected; the head of the bone being fixed by the coracoid process, and neck of the scapula, on the outside, and by the clavicle above; whilst the muscles of the scapula, as the supra and infra spinati, and teres minor, being put upon the stretch, confine all its motions inwards and backwards. If, therefore, the arm be attempted to be brought forwards, the head of the bone strikes against the clavicle; if outwards, from the side, the coracoid process stops it; but its motion backwards is confined, not by bone, but by the resistance of muscles. But the strongest diagnostic marks of this dislocation are these: the head of the bone is below the clavicle; the elbow is separated from the side, and thrown backwards; and the head of the bone can be felt to move under the clavicle, when the arm is rotated at the elbow.

Dissection of the dislocation forwards. — The head of the os humeri is, in this accident, thrown on the inner side of the neck of the scapula, between it and the second and third ribs. I have had no opportunity of dissecting a recent accident of this kind; but in the museum at St. Thomas's Hospital, we have a beautiful specimen of one in a limb which had been long dislocated, and which was removed from the shoulder of a patient by my colleague, Mr. Green, and dissected by Mr. Key, who gave me the following account of the appearances: — "The head of the bone was thrown on the neck and part of the venter of the scapula, near the edge of the glenoid cavity, and immediately under the notch of the superior costa; nothing intervened between the head of the humerus and scapula, the subscapularis being partly raised from its attachment to the venter. The head was situated on the inner side of the coracoid process, and immediately under the edge of the clavicle, without having the slightest connexion with the ribs; indeed, this must have been prevented by the situation of the subscapularis and serratus magnus muscles between the thorax and humerus. The tendons of all the muscles attached to the tubercles of the humerus were perfect, and are shown in the preparation. The tendon of the biceps was not torn; and it adhered to the capsular ligament. The glenoid cavity was completely filled up by ligamentous structure, still, however, preserving its general form and cha-

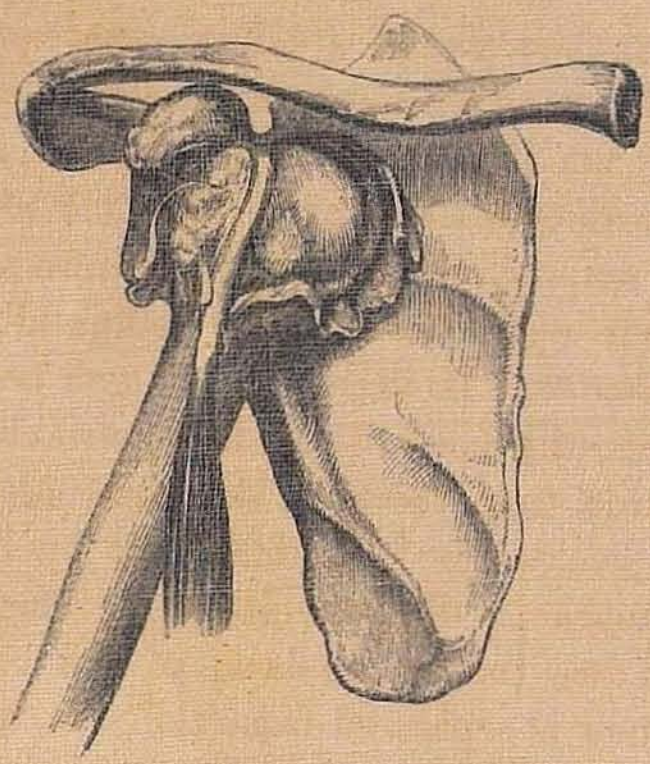

racter. The tendons of the supra and infra spinati, and teres minor muscles, adhered by means of bands to the ligamentous structure occupying the glenoid cavity; and to prevent the effects of friction between the tendons and the glenoid cavity in the motions of the arm, a sesamoid bone had been formed in the substance of the tendons. The newly formed socket reached from the edge of the glenoid cavity to about one-third across the venter. A complete lip was formed around the new cavity, and the surface was irregularly covered with cartilage. The head of the bone had undergone considerable change of form, the cartilage being in many places absorbed. A complete new capsular ligament had been formed."

The pectoralis minor is not mentioned in this dissection, but from the natural situation of the coracoid process, into which this muscle is inserted, it must have passed over the head of the os humeri, as did the pectoralis major.

The following account of the dissection of a shoulder-joint after a recent dislocation forwards of the head of the humerus, was drawn up by Mr. Curling, and sent to Mr. Bransby Cooper by Mr. Luke.

Case CCXXIV.—" A strong, muscular man, apparently about thirty-five years of age, being at work in the East-India Docks, was thrown down by a cask falling upon him, and so severely injured that he expired whilst being carried to the London Hospital.

"The body was examined twenty-four hours after death. Six of the lower ribs on the left side were found fractured; there was also extensive laceration of the diaphragm, and of the œsophageal portion of the stomach, which had allowed the escape of the contents of that organ into the cavity of the chest. The spleen was ruptured, and a large quantity of blood effused into the abdomen; there was also a fracture of the os pubis. The sternal extremity of the right clavicle was partially displaced upwards. The right humerus was dislocated forwards beneath the pectoral muscle. The usual signs of this form of dislocation were well marked. The fibres of the deltoid muscle were found to be tense. Upon reflecting it with the pectoral muscle, the head of the os humeri was seen situated on the inner side of the coracoid process, immediately below the clavicle, beneath the pectoralis minor, pushing this muscle forwards, and separated from the serratus magnus by the axillary plexus of nerves. Blood was extravasated under the deltoid muscle and in the loose cellular substance of the axilla. The nerves, with the artery and vein, were forced from their natural situation to the sternal side of the head of the humerus, which made considerable pressure upon them. The coraco-brachialis and short head of the biceps were upon the stretch. The supra-spinatus, infra-spinatus, and subscapularis were completely detached from the tubercles of the humerus, and the teres minor tightly girted the neck of the bone, a few only of its fibres having been lacerated. The capsular ligament was entirely torn away from the whole circumference of the neck of the humerus. In order to ascertain what impediment might exist to the replacement of the head of the humerus in its natural situation, powerful extension of the limb was made nearly at a right angle with the body; the dislocation, however, could not be reduced. The short head of the biceps and the coraco-brachialis were next divided, and forcible extension again made, so as to draw the humerus downwards; but it now became evident that the obstacle to reduction was the tendon of the long head of the biceps, which was so situated as to prevent the passage of the head of the bone to the glenoid cavity; and during extension this tendon was rendered more tense in proportion to the degree of force applied. The os humeri was afterwards readily replaced in the glenoid cavity, by turning the tendon with the handle of a scalpel over the head of the bone."

Causes. — The usual causes of this dislocation are, either a fall upon the elbow, or a violent blow upon the shoulder, as in the last described dislocation. If it be a blow upon the elbow which has produced the accident, it must have been inflicted at a time when the elbow was thrown behind the central line of the body; so that when the shoulder receives the blow, the head of the bone may be driven forwards and inwards.

Treatment. — In this, as in the former variety of dislocation, we can usually succeed in effecting reduction by placing the heel in the axilla, and by extending the arm in the same manner; excepting that in this dislocation the foot is required to be brought more forward to press on the head of the bone, and the arm should be drawn obliquely downwards, and a little backwards; but in those cases in which some days have elapsed before reduction has been attempted, continued extension will be necessary, and to employ it steadily and effectually, the pulleys should be used.

The same bandage is required as in the dislocation in the axilla, whether the power used be applied through the medium of pulleys, or directly by men. The arm should be bent, to relax the biceps muscle; but the principal circumstance to be considered is, the direction in which the bone is to be drawn; and the best direction is slightly downwards and backwards; for if it be drawn horizontally, the head of the os humeri is pulled against the coracoid process of the scapula, and a difficulty created which may be avoided. The principle upon which the pulley is employed, and the manner in which the extension is supported, are the same as described for the reduction of dislocation into the axilla. The extension must be kept up longer than in the dislocation downwards, as the resistance is greater; but as soon as the bone is felt to move from its situation, the surgeon should give the strings of the pulley to an assistant, and putting his knee or heel against the head of the bone at the fore part of the shoulder, should push it back towards the glenoid cavity; but this step is not of the smallest utility until the bone has been drawn below the level of the coracoid process; and whilst the surgeon is thus pressing the head of the bone backwards, he should pull the arm forwards from the elbow. This is the plan which I have found by far the most effectual in reducing the dislocation forwards.

Case CCXXV.—Samuel Ridge, æt. fifty-two, came to St. Thomas's Hospital, on the 30th August, 1823, with dislocation forward of the head of the right os humeri. The account his wife gave of the accident was this:—On the night before, he fell down and hurt his shoulder; she, on his arriving at home, thought it was only a bruise, and rubbed it with some oily embrocation; he did not sleep the whole night for pain. Next morning, about eleven o'clock, she discovered that the injured shoulder was not in shape similar to the opposite one, and therefore consulted Mr. Evans, surgeon, of Brixton, who informed them of the nature of the accident, attempted to reduce it in vain, and then advised him to go to the hospital directly. On his admission the patient complained of much pain; his arm could nearly be brought close to the side, the deltoid muscle had lost its rotundity, and the displacement of the head of the bone was evident by the projection, as it were, of the acromion; the head of the os humeri could be felt projecting forwards under the clavicle at the junction of the pectoralis major with the deltoid muscle, thereby preventing the coracoid process of the scapula from being felt. The man was laid on a bed, and extension made with the heel in the axilla, but without success; whereupon, he was taken into the theatre to undergo extension with pulleys by Mr. Hardy. Having fixed them, he bled him to ℥xx, then gave him a dose of solution of antim. tart., and repeated it twice at intervals during extension, which was made in a direction at a right angle with the body downwards. The patient was placed in a chair between two pillars; to the one was affixed the girth for securing the scapula, taking its line obliquely downwards to the body, and the pulley was fastened above the elbow of the affected arm, and the extension, as before said, made sideways, at a right angle downwards with the body. Whilst the extension was going on, Mr. Hardy put his knee under the shaft of the bone, and in ten minutes it snapped in its return into the glenoid cavity. The shoulder resumed its natural roundness, and he had no pain on moving the arm. Some deformity appeared from the scapular end of the clavicle riding on the acromion: this, however, he said, was an old accident. He went out of the hospital September 5th, and on the 12th his wife said he could not yet raise his arm very well to his head.

The following case of unreduced dislocation of the os humeri

forwards, under the clavicle, of fourteen weeks standing, was sent to me for my opinion by Mr. James Mash, house-surgeon to the Northampton Infirmary.

Case CCXXVI. — Barton Eete, a farmer, æt. fifty-six, living in a village in Northamptonshire, was thrown off his horse, and pitched on his shoulder, November 22nd, 1838, and was immediately seen by the surgeon of the village, and, after the lapse of five weeks, was visited by another, who discovered the nature of the accident, and had recourse to the pulleys, but failed in reducing it. He was afterwards seen by some empiric, or bone-setter, who told him it would cost him his life if he attempted to put it in; and, on the 26th of February, he was brought to this hospital. On examination, the head of the bone was distinctly felt under the clavicle, resting on the inner side of the coracoid process of the scapula. The arm was fixed and projecting from the side; there was a projection of the acromion, and the deltoid muscle was very much wasted.

He was placed in a hot bath and extension used by the pulleys for one hour and three quarters, giving him one grain of ant. tart. every ten minutes, until he had taken six grains, which did not produce either nausea or syncope, but the dislocation could not be reduced.

I was then consulted, and recommended that the man should be made to chew tobacco. This attempt failed; but he would not submit to any further measures.

The success which attended the treatment of the following case, in which a dislocated humerus was reduced after nine weeks and six days, must not be hoped for in every instance.

Case CCXXVII. — Thomas Fulham, aged forty-six, a stout muscular man, on the morning of the 5th of November 1812, fell, and dislocated his right shoulder, which, not being discovered by the practitioner who was immediately called in, was considered simply as a strain, and treated accordingly. The subsequent swelling of the hand and wrist, with the pain and numbness accompanying it, were regarded and treated as rheumatic gout arising from some other cause.

After going on with this treatment for nearly eight weeks without deriving any benefit, he applied at Guy's Hospital on the morning of the 30th December, when the nature of the injury was immediately perceived, insomuch as the depression in

the deltoid muscle under the acromion was very evident, and the head of the humerus was distinctly felt underneath the pectoralis muscle.

Without any preparation he was ordered by Mr. Lucas into the theatre; the pulleys were applied in the usual manner; extension was made and kept up for a considerable time; then intermitting for awhile, and again extending, the direction being varied in such a manner as would tend most to fatigue, and, consequently, to relax the opposing muscles; and all means were employed, which (as far as relates to the mechanical part of reduction,) either practical observation or anatomical knowledge could suggest, but to no purpose. The case was abandoned as almost hopeless. He was returned to his bed until he should recover from the violence done by these endeavours to reduce it, as preparatory to his being dismissed; much tension and tenderness of the parts ensued.

Notwithstanding these sufferings, the idea of being a cripple for life rendered the poor fellow very desirous that something further might be tried: he was therefore, after a lapse of fourteen days, (the tension and tenderness having completely subsided,) put into the warm bath, and bled *ad deliquium animi*. In this state he was conveyed to his bed, and several attempts were made to effect a reduction by placing the heel in the axilla, and using what Mr. Hey terms the vertical extension, but which attempts likewise proved ineffectual. He was then carried into the theatre for the convenience of the pulleys, and before any further efforts were made use of, was given a grain of the tartarized antimony in divided doses, which produced nausea and faintness to an extreme degree. During this state the pulleys were fixed, and a gradual extension was maintained in a direction nearly at a right angle with the body, but varying from this line by being diverted rather upwards and somewhat backwards; this extension was regularly increased and steadily preserved for some time. A long towel was carried under the arm, as near to the head of the humerus as was possible, and the two open ends thrown over the operator's neck, who, standing on a chair placed behind the patient, had, by raising himself, the power of exerting a very considerable elevating force, and, at the same time, of depressing the scapula.

Whilst the elevating force above alluded to was powerfully exerted, and the acromion was depressed as much as possible, so

as to approximate the glenoid cavity to the head of the humerus, as well as to prevent its lower margin from checking the bone, the extension by the pulleys was suddenly quitted, and the head of the humerus, under these circumstances, as suddenly slipped into its place. A cooling lotion was afterwards applied, and the other symptoms gradually disappeared. He left the hospital eleven days afterwards, with perfect motion, but tenderness of the parts.*

SECTION IV.

DISLOCATION OF THE OS HUMERI ON THE DORSUM SCAPULÆ.

Symptoms.—In this dislocation, the head of the bone is thrown upon the posterior surface of the inferior costa of the scapula. It is an accident which cannot be mistaken, as there is a protuberance formed by the bone upon the scapula, which immediately strikes the eye; and when the elbow is rotated, this protuberance rolls also. The dislocated head of the bone may

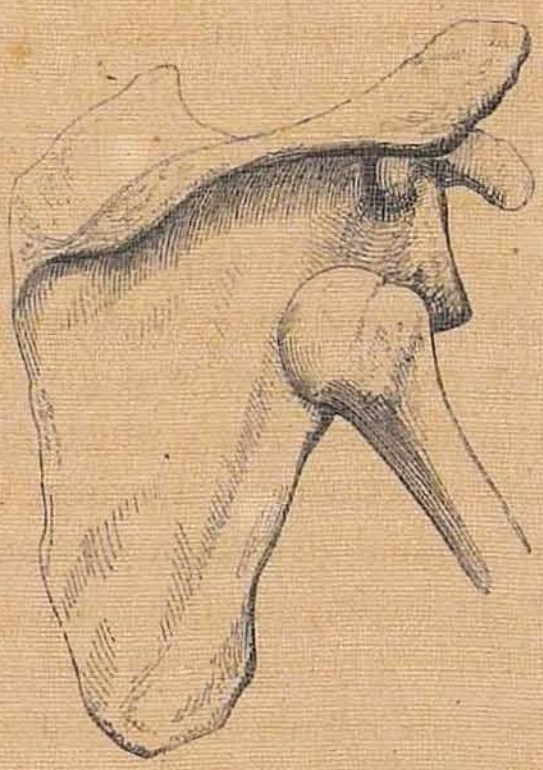

be easily grasped between the fingers, and be distinctly felt resting below the spine of the scapula; the motions of the arm are impaired, but not to the same extent as in either of the other states of luxation; and the direction of the limb is obviously behind the glenoid cavity.

* This case shows very strikingly the value of the preparatory constitutional remedies directed by Sir A. Cooper.—*Ed.*

Two cases only of this accident occurred in Guy's Hospital in thirty-eight years; the first was during my apprenticeship. It happened during the anatomical lecture at St. Thomas's Hospital. The surgery-man came to the theatre and announced that there was a dislocation of the shoulder at Guy's Hospital, when Mr. Cline went over with the students to see the accident, and met Mr. Forster, under whose care the patient was admitted. The nature of the accident was at once obvious, from the projection of the head of the bone on the dorsum scapulæ. The bandages were applied in the same manner as if the head of the humerus had been in the axilla, and the extension was made in the same direction as in that accident. During the progress of the adjustment of the apparatus, some conversation took place between Mr. Cline and Mr. Forster, as to what variation in direction there should be given to the bone, if the first attempt should not succeed; but in less than five minutes, the bone slipped into the glenoid cavity with a loud snap.

The second case, which occurred several years after, was easily reduced by the dressers, under the same treatment.

The following case occurred a few years ago.

Case CCXXVIII. — Mr. G. had his right shoulder dislocated backwards, through pushing a person violently with the arm elevated.

He applied to a surgeon the following morning, as he could not raise his upper arm at all, although he could use his fore arm. On the 17th day he applied to my nephew, Mr. Bransby Cooper, who said there was certainly no fracture, but did not discover the dislocation. On the 23rd day he applied to me, and I readily reduced the bone, *by raising the hand and arm, and by turning the hand backwards behind the head;* but I did not know the nature of the accident until I heard the bone slip into the glenoid cavity.

The appearance of the accident was a projection of the head of the humerus upon the neck of the scapula posteriorly, and not upon the inferior costa, as I have before seen it.

Case CCXXIX. — A few mornings after the last patient had called on me, another gentleman presented himself with a similar accident, and the following account of the appearances was written down at the time by Mr. B. Cooper.

The arm was directed inwards towards the side, giving it the

appearance of fracture, and looking as if so carried for support. The shoulder had lost its natural roundness, and the skin was gathered into folds in front of the acromion process, which was preternaturally prominent. On taking a posterior view of the shoulder, it was impossible to trace the spine of the scapula, in consequence of a fulness below and behind the acromion; and upon raising the arm, the tumor in the fossa infra-spinata moved obediently to the motions of the humerus, indicating the position of the head of the bone; in tracing the long axis of which, the eye was directed behind the glenoid cavity of the scapula. We then tried to reduce the dislocation by slight extension, drawing the arm outwards; but failing in this attempt, Sir A. Cooper raised the arm perpendicularly; and at the same time forced it backwards behind the patient's head; upon which the bone slipped into its place, being thus reduced, precisely as the former case had been.*

In the next case, for which I have to thank Mr. Key, the plan of raising the arm and carrying it behind the head, did not succeed as it did with me in Mr. G.'s case.

Case CCXXX. — A stout man, in a fracas, fell down upon his shoulder with some violence, and, when he arose, found his arm in great pain, and nearly useless. Mr. Whittaker, his surgeon, attended him immediately after the accident, and discovered, as it appeared to him, that the head of the os humeri was thrown backwards. The unusual nature of the accident induced him to send for me, to see the case with him. I found, says Mr. Key, a very stout man, sitting up in bed in great pain, and complaining more than patients commonly do under dislocation; and I concluded it to be some fracture about the cervix; especially as, at first view, nothing could be seen of a hollow under the deltoid muscle; the joint appearing round as usual. On passing to the man's side, to examine the limb, the deformity of the shoulder became visible. The fore part appeared flattened, and the back of the joint fuller than usual; the head of the bone could be seen, as well as felt, resting upon the posterior part of the cervix scapulæ. The elbow could be brought to the side, or raised on a level with the acromion. Rotation outwards was entirely impeded, in consequence of the subscapularis being stretched, all motion of the limb giving him extreme pain; which was referred to the

* Surgical Essays, p. 207.

lower part of the deltoid muscle, in the direction of the articular nerves, which were probably injured by the pressure of the head of the bone.

At first we placed our patient on a chair; and while Mr. Whittaker fixed the scapula, I carried the elbow upwards and backwards, in order to throw the head of the bone forwards into the glenoid cavity, but to no purpose. All that we gained by this measure was a slight advance of the bone, and reducing him to a state of syncope. In this state, we laid him upon his back; and fixing his scapula by the heel in the axilla, drew the arm downwards; and by extension, continued for a minute or two, succeeded in reducing it. Mr. Whittaker tells me he is going on well, although the shoulder has been highly inflamed and swelled.

Case CCXXXI.—Mr. Robert Dunn, of Clement's Inn, sent the Editor a case of this dislocation, in an old woman, which he tried to reduce by raising the arm perpendicularly, as above described. This plan, however, failed, probably because Mr. Dunn did not employ strength enough. He then reduced it by making extension from the wrist in the direction of the displaced bone, (but without placing his foot in the axilla, which would rather have impeded the return of the bone,) whilst an assistant directed the head of the bone towards its proper cavity.

The next case differs from the foregoing, in being the effect of muscular spasm solely; it is also the only case in which I have had an opportunity of making a post-mortem examination, and I have thought it worth while to give a plate of the appearances.

Case CCXXXII.—I was sent for by Mr. Complin, a gentleman residing in Bishopsgate-street, in the city of London, to examine his left shoulder; and I found a very obvious luxation of the os humeri upon the dorsum scapulæ, as was evinced by the depression below the acromion, by the absence of the head of the bone from its natural situation, by a depression by which the fingers could be admitted into the glenoid cavity between the head of the os humeri and coracoid process, but more especially by the projection of the head of the os humeri upon the back part of the glenoid cavity of the scapula, and upon its inferior costa, as well as by its filling the space between that costa and the spine of the scapula.

I advised an extension; but he had already suffered so much

from attempts at reduction, that he was full of apprehension at the least motion of his shoulder, so that I no longer urged it, and he retained the appearance of the displacement to his death. Dr. Cobb had seen him. Mr. Key had also examined his shoulder with care; and his son, who is a surgeon in Charter-house-square, has given me the particulars of the case, in a letter which I received from him.

"Mr. Complin was fifty-two years of age, and had been the subject of epileptic fits. One of these which was particularly severe, occurred one morning whilst he was in bed, and in his violent convulsive strugglings his shoulder became dislocated. Mrs. Complin, who was with him, is confident that he neither fell from his bed, nor struck his shoulder during the fit; and it was the firm belief of Dr. Cobb, Mr. Key, and myself, that the appearances which I have described, and which remained until his death, were the result of muscular efforts alone. Beside the unusual mode in which the accident happened, there were two other circumstances peculiar in the case. The one was, that the head of the bone could be by extension drawn into its natural situation in the glenoid cavity; but so soon as the force ceased to be applied, the head of the bone slipped again on the dorsum scapulæ, and all the appearances of dislocation were renewed. The second peculiarity consisted in a sensation of crepitus as the bone escaped from its socket, so as to lead to a belief that the edge of the glenoid cavity had been broken off, and this symptom led to a belief that the cause of the bone so readily slipping from its situation, when restored to its natural cavity, was the imperfection of the articular surface of the glenoid cavity."

The patient was unable to use or even to move the arm to any extent, nor could he by his own efforts elevate it from his side; and although he lived seven years after the occurrence of the epileptic fit, he never recovered the use of the limb.

From the peculiar circumstances and appearances of the case, I requested one of his medical assistants to make a post-mortem examination of his arm, if permission could be obtained; and at length that opportunity arrived, and was taken advantage of by Mr. Key, who removed the parts, and having examined them himself, sent them to me for further inspection, accompanied with the following note:—

"You will remember that the dislocation of Mr. Complin's shoulder arose from muscular action alone, in a paroxysm of epilepsy; and, during his life, it was thought probable that a portion of the glenoid cavity had been broken off, or a piece of the head of the os humeri, or perhaps the smaller tubercle; and that either of these injuries would account for the head of the bone not remaining in its natural cavity when reduced. But the inspection, post-mortem, proved that the cause of this symptom was the laceration of the tendon of the subscapularis muscle, which was found to adhere to the edge of the glenoid cavity, and was much thickened, and altered in its character, from its laceration, and from its very imperfect and irregular union.

The muscles of the dorsum scapulæ were diminished, by being thrown out of use; and the tendon of the long head of the biceps muscle was entire, but glued down by adhesion. However, I have sent you the parts for a more particular examination."

Upon examination of the scapula and os humeri sent to me by Mr. Key, I found the state of the muscles and the situation of the bones to be as follows:—

The head of the os humeri was placed behind the glenoid cavity of the scapula; and it rested upon the posterior edge of that articular surface, and upon the inferior costa of the scapula,

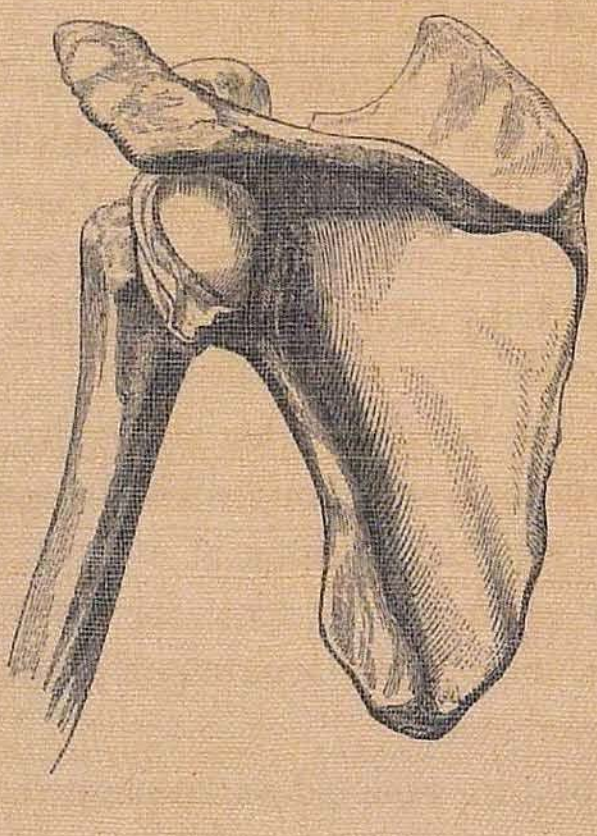

where it joins the articulation. When the scapula was viewed anteriorly, the head of the os humeri was placed in a line behind

the acromion, but below it; and a wide space intervened between the dislocated head of the bone and the coracoid process, in which the fingers sunk deeply towards the glenoid cavity of the scapula.

When viewed posteriorly the head of the os humeri was found to occupy the space between the inferior costa and spine of the scapula, which is usually covered by the infra-spinatus and teres minor muscles. The tendon of the subscapularis muscle and the internal portion of the capsular ligament, had been torn at the insertion of that muscle; but the greater part of the posterior portion of the capsular ligament remained, and had been thrust back with the head of the bone, the back part of which it enveloped. The supra-spinatus muscle was put upon the stretch; the subscapularis was diminished by want of action; and the infra-spinatus and teres minor muscles were shortened and relaxed, as the head of the bone carried their insertions backwards. The tendon of the long head of the biceps muscle was carried back with the head of the bone and elongated; but it was not torn. As to the changes in the bones, the head of the os humeri, and the outer edge of the glenoid cavity of the scapula were in direct contact, the one bone rubbing upon the other when the head of the os humeri was moved; and this accounted for the sensation of crepitus at the early period of the dislocation, as there was no fracture.

The glenoid cavity was slightly absorbed at its posterior edge, so as to form a cup, in which the head of the bone was received, and this latter bone and the articular cartilage had been in some degree absorbed where it was in direct contact with the scapula, as well as changed by attrition during the seven years the patient lived.

The surface of the original glenoid cavity, instead of being smooth and cartilaginous, was rough and irregular, having elevations at some parts and depressions at others. The extremity of the acromion was sawn off, to look for any little fragment of bone which might have been broken off; but not the smallest fracture could be perceived.

The dissection of this dislocation explained well the whole of the circumstances.

In the usual dislocation backwards, or on the dorsum scapulæ, the bone, when reduced to its proper situation, remains there;

and only requires a roller, and rest for a few hours, to prevent the future escape of the bone from the glenoid cavity. But in this case, as the tendon of the subscapularis and the capsular ligament had been torn from the smaller tubercle of the head of the os humeri, and the bone was consequently drawn back by the action of the infra-spinatus and teres minor muscles, there was no support given to the head of the bone, when returned into its cavity; but so soon as it was replaced, it was drawn back by the action of the two posterior muscles; and all the appearances of dislocation were reproduced.

The bandage required to keep the bone in its place should be placed on the fore part of the chest, and behind the shoulders, to keep the head of the bone forwards; and a pad ought to be placed behind the head of the bone, to prevent it from slipping from its cavity: so that the bandage would be the reverse of the common stellate, which crosses upon the back; but this should be made to cross upon the anterior part of the chest; and to this bandage a sling must be added, to support the elbow and keep it back.*

Mr. Toulmin, of Hackney, had the kindness to send me the following communication upon the subject of this species of dislocation.

Case CCXXXIII.—Mr. Collinson, about thirty-six years of age, six feet high, and unusually muscular, dislocated his os humeri on the dorsum scapulæ. The injury was sustained in the neighbourhood of Windsor, in consequence of his horse falling with him, by which he was thrown over the animal's head. He applied to a surgeon at Windsor, but the character of the accident was not detected. He returned in a post-chaise to his own house, when Mr. Hacon and myself saw him. The shoulder had lost its natural roundness; the arm could be moved considerably, either upwards or downwards; but the motion, either in the anterior or posterior direction, was very limited. On raising the arm to a right angle with the side, the direction of the limb was obviously behind the glenoid cavity; and by placing the hand over the dorsum scapulæ, and then rotating the arm, the head of the bone was felt to obey the rotating motion.

In order to reduce this dislocation, a large towel was applied to sustain the necessary force for the reduction, and to fix as much

* These cases were published in the Guy's Hospital Reports, No. ix.

as possible that part of the scapula unoccupied by the head of the bone. A gradual extension of the limb was made directly outwards, and then the arm being slowly moved forwards, the head of the bone was distinctly heard to snap into its socket. The extension was not continued for more than two or three minutes before the reduction was accomplished. To the best of my recollection, Mr. Collinson's arm was perfectly restored to all its functions within a month.

The following remarks on this dislocation were sent to me in the year 1822, by Mr. C. M. Coley, of Bridgeworth.

The external appearances of this accident are a hollow, and puckering of the parts just below the acromion; the arm lies close to the side; the fore arm is turned inwards, and passes obliquely forwards across the body; a protuberance as large as an orange is seen on the dorsum scapulæ, close to the spine of that bone. This dislocation is, I suppose, produced by the action of the teres major and latissimus dorsi upon the bone, while its head is forced over the margin of the glenoid cavity.

Case CCXXXIV. — June 17th, 1820. Thomas Alding was pulled down by a calf, which he was driving, a cord having been tied to one of the calf's legs, and held fast by the man's hand. The appearances corresponded with the above-described general marks of the accident.

I rotated the fore arm as much as possible outward, carrying the whole arm upwards at the same time, so that the hand was brought nearly in a line with the vertebræ, and as high as it could be extended above the head. By this expedient I succeeded in rolling the head of the humerus downwards and inwards, until it rested on the inferior costa of the scapula, and was in part to be felt in the axilla. Having thus reduced it as far as possible into the situation resembling the dislocation downwards, I brought the arm and fore arm carefully downwards and backwards into the horizontal line, keeping the head of the humerus in the same situation all the time. Extension being now made, and my hand being placed firmly on the acromion, the bone was easily replaced. The rotatory motion produced considerable pain; and just as the head of the bone crossed the edge of the glenoid cavity, severe pain was felt, and a noise was heard.

SECTION V.

PARTIAL DISLOCATION OF THE OS HUMERI.

I believe this is not a very rare accident, and it shows itself by the following marks.

Symptoms. — The head of the bone is drawn forwards against the coracoid process; there is a depression opposite the back of the shoulder-joint, and the posterior half of the glenoid cavity is perceptible, from the advance of the head of the bone; the axis of the arm is thrown inwards and forwards; the inferior motions of the limb are still capable of being performed; but its elevation is prevented by the head of the humerus striking against the coracoid process; there is an evident protuberance formed by the head of the bone in its new situation, which is felt readily to roll when the arm is rotated.

Case CCXXXV. — Mr. Brown, aged fifty, was thrown from his chaise on his shoulder, and, upon examination after the accident, the roundness of the shoulder was lost, and there was a hollow under the acromion; the head of the bone projected forwards and inwards against the coracoid process; the arm could be raised from the side if brought forwards, but could with difficulty be raised directly upwards. By extension of the shoulders backwards, I at last brought the head of the bone to the glenoid cavity, but it directly again slipped forwards as the extension ceased. This dislocation differs from that forwards under the pectoral muscle, in the head of the os humeri being still on the scapular side of the coracoid process, while in the complete dislocation forwards it is thrown on its sternal side.

Case CCXXXVI.—Mr. Bachelor, aged thirty-six, fell from a chaise on the 12th of November, and, as he supposes, pitched on his shoulder. On rising, he could not move his right arm for ten minutes, when some sudden spasm gave him the power of moving it underhand. Inflammation succeeded; the shoulder became much swollen, with pain down the arm to the fingers, and particularly in the direction of the cubital nerve. On looking at the arm the same evening, he found that the os humeri appeared to be advanced.

It is two months since the injury, and the hand is now be-

numbed. There is much pain at the insertion of the biceps into the fore arm, so that he has been often obliged to rise twice during the night to put his hand in warm water.

The appearances are, a projection of the acromion, and a hollow beneath it; the head of the os humeri rests against and under the coracoid process, and the scapular end of the clavicle is opposite to the middle of the head of the bone. The biceps muscle was relaxed and lessened; the coracoid process of the scapula was with difficulty felt above, and to the inner side of the head of the os humeri.

The principle of treatment in these cases is, to oppose the pectoralis major by a clavicle bandage, with a broad strap over the head of the os humeri, and to bring the elbow forward to keep the head of the os humeri back.

Dissection. — The only case of dissection of this accident which I have had an opportunity of seeing was the following, for which I am indebted to Mr. Patey, surgeon, in Dorset-street, who had the subject brought to him for dissection at the anatomical room, St. Thomas's Hospital.

Case CCXXXVII.—Partial dislocation of the head of the os humeri, found in a subject brought for dissection to St. Thomas's Hospital, during the latter part of the year 1819.

The appearances were as follow:—The head of the os humeri, on the left side, was placed more forward than is natural, and the arm could be drawn no farther from the side than half way to the horizontal position.

The tendons of those muscles which are connected with the

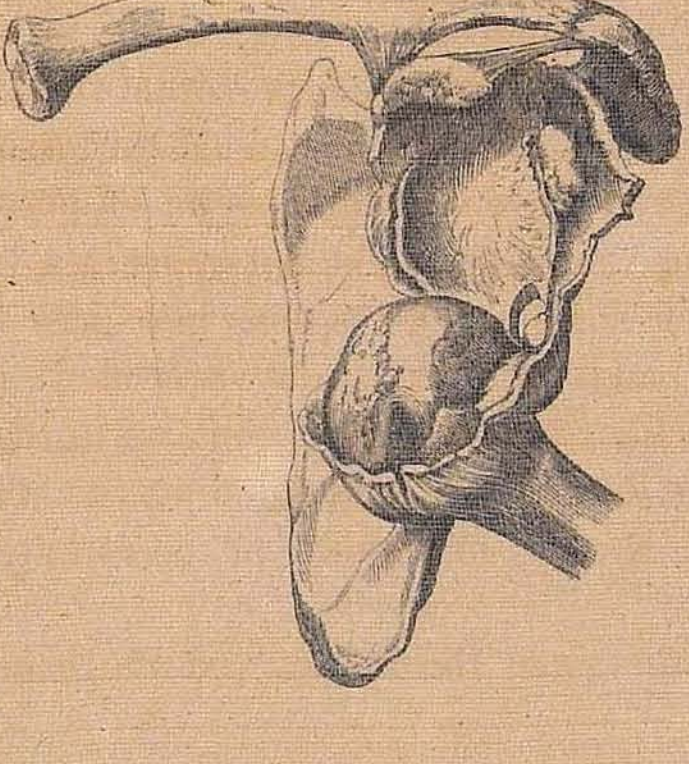

joint were not torn, and the capsular ligament was found attached to the coracoid process of the scapula. When this ligament was opened, it was found that the head of the os humeri was situated under the coracoid process, which formed the upper part of the new glenoid cavity; the head of the bone appeared to be thrown upon the anterior part of the neck of the scapula, which was hollowed, and formed the lower portion of the glenoid cavity. The natural rounded form of the head of the humerus was much altered, it having become irregularly oviform, with its long axis, from above downwards; a small portion of the original glenoid cavity remained, but this was rendered irregular on its surface by the deposition of cartilage; there were also many particles of cartilaginous matter upon the head of the os humeri, and upon the hollow of the new cavity in the cervix scapulæ, which received the head of the bone. At the upper and back part of the joint there was a large piece of the cartilage which hung loosely into the cavity, being connected with the synovial membrane, at the upper part only, by two or three small membranous bands. The long head of the biceps muscle seemed to have been ruptured near to its origin at the upper part of the glenoid cavity, for at this part the tendon was very small, and had the appearance of being a new formation.

The following description of a shoulder-joint, to which this accident had occurred, was sent to the Editor in the present year (1841), by Mr. Douglas, of Glasgow. It closely corresponds to the description of the preceding case.

Case CCXXXVIII.—The scapula and humerus were sent to me without any history: they obviously belong to a female, and are of small size, the scapula measuring five inches from its upper costa to its inferior angle, and being narrow in proportion.

The humerus has been thrown in front of the neck of the scapula, but not so far inwards as the notch. It must have remained there for years, for the neck is absorbed so as to remove about one-fourth of the breadth of the glenoid cavity; and new bone has been deposited so as to elevate the edges of the new cavity. This new surface, slightly hollowed in both directions, measures an inch and five-eighths in the long diameter, and an inch transversely. Its surface is mostly porous, and in the middle is covered with porcelain deposit. The glenoid cavity is very slightly filled up. The head of the humerus is altered in

its shape, elongated, roughened, and surrounded with an irregular border. The surface in contact with the new scapular cavity is slightly flattened, and is covered with porcelain deposit.

The motion enjoyed by the humerus in its new situation must have been very limited, from the adaptation of the surfaces to each other.

CAUSE. — This accident happens from the same causes which produce the dislocation forwards. The anterior part of the ligament is torn, and the head of the bone has an opportunity of escaping forwards to the coracoid process.

TREATMENT.— The mode for its reduction will be the same as that for the dislocation forwards; but it is necessary to draw the shoulders backwards to bring the head of the bone to the glenoid cavity; and immediately when the reduction is completed, the shoulders should be bound back by a clavicle bandage, or the bone will immediately again slip forward against the coracoid process.

PARTIAL DISLOCATION UPWARDS.

The following account of this rare accident was drawn up by Mr. John Soden, jun. of Bath, and was read before the Royal Medical and Chirurgical Society of London, and published in their Transactions for the year 1841. The Editor cannot omit this opportunity of thanking Mr. Soden, as well as Mr. Partridge, the secretary to that society, for their liberality in enabling him to make use of the same engraving which illustrates the paper in the Medico-Chirurgical Transactions.

CASE CCXXXIX.—Joseph Cooper, aged fifty-nine, was admitted into the Bath United Hospital, November 9th, 1839, on account of a compound fracture of the skull, received through a fall down a trap-door, from the effects of which he died in a few hours. His death afforded an opportunity for examining an old injury of the right shoulder, the symptoms of which had always been involved in great obscurity, and which occurred in the following manner.

In the month of May 1839, the deceased was engaged in nailing down a carpet, when, on rising hastily from his occupation, his feet slipped, and he fell backwards on the floor. In order to break the force of his fall, he involuntarily placed his arm

behind him, and by so doing, received the whole weight of his body upon the right elbow; that joint, however, though the only part struck, received no injury, for the shock was instantly transmitted to the shoulder, and there the whole effects of the accident were sustained.

Acute pain was immediately experienced, and the man supposed that he had suffered either a fracture or dislocation; but finding that he could raise the arm over his head, he felt reassured, and endeavoured to resume his work. The pain, however, compelled him to desist, and he went home.

When I saw him on the following morning, the joint was greatly swollen, tender to the touch, and painful on very slight motion: there was then no possibility of his placing his arm over his head, as he said he had done immediately after the accident. I satisfied myself that there was neither fracture nor dislocation of the bones, and not suspecting the existence of a more specific injury than a "severe sprain," I set down the case as such, and avoided the unnecessary pain of further examination. Unusually active means were required to subdue the inflammation; and at the end of three weeks, though the swelling was much reduced, the tenderness in front of the joint, and pain on certain movements of the limb, were scarcely less than on the day after the occurrence of the accident.

On comparing the joint with its fellow, now that the swelling had subsided, a marked difference was observable between their respective outlines; the injured shoulder was evidently out of drawing, but without presenting any glaring deformity. When the man stood erect, with his arms dependent, the distinction was very manifest, but difficult to define; there was a slight flattening on the outer and posterior parts of the joint, and the head of the bone looked as though it were drawn up higher in the glenoid cavity than it should be. Examination verified this appearance in two ways; first, on moving the limb, with one hand placed on the shoulder, a crepitating sensation was experienced under the fingers, simulating a fracture, but in reality caused by the friction of the head of the humerus against the under surface of the acromion; secondly, on attempting abduction, it was found that the arm could not be raised beyond a very acute angle with the body, from the upper edge of the greater tubercle coming in contact with that of the acromion, and thus

forming an obstacle to all further progress. The head of the bone was also unduly prominent in front, almost to the amount of a partial dislocation.

For all useful purposes the arm was powerless; the man was unable to raise the smallest weights from the ground, on account of the severe pain induced by any exercise of the biceps muscle; otherwise the underhand motions were not limited: the arm could be readily swung backwards and forwards, and the patient could grasp an object firmly and without pain, so long as he made no attempt to raise it. The locking of the humerus and acromion on abduction in the manner before alluded to, of course, formed an insuperable obstacle to all the overhand motions.

The pain caused by the action of the biceps was described as very acute, and extending through the whole course of the muscle, but felt chiefly at its extremities, the lower equally with the upper; when not excited by muscular action, it was referred to the front of the joint, and confined to the space between the coracoid process and the head of the humerus, which spot was marked by extreme tenderness, and some puffy swelling.

The patient being of a rheumatic habit, inflammatory action of that character was soon established in the joint, so that the peculiar symptoms of the injury were masked by those of general articular inflammation, which added greatly to the man's sufferings, and to the difficulty of the diagnosis. It is unnecessary to dwell upon the treatment, and I shall only mention that the patient found most relief from the elbow being well supported, and placed close to the side, with pressure by a soft pad firmly applied against the deltoid muscle. This plan of perfect rest was persevered in for some time, under the impression that the glenoid cavity was the seat of injury, and that probably its upper portion, including the origin of the biceps tendon, was detached.

On examining the joint, the accident was found to be a dislocation of the long head of the biceps from its groove, unaccompanied by any other injury. The tendon was entire, and lay enclosed in its sheath on the lesser tubercle of the humerus; the capsule was but slightly ruptured; the joint exhibited extensive traces of inflammation; the synovial membrane was vascular, and coated with lymph; recent adhesions were stretched between different parts of its surface, and ulceration had commenced on the cartilage covering the humerus, where it came in contact

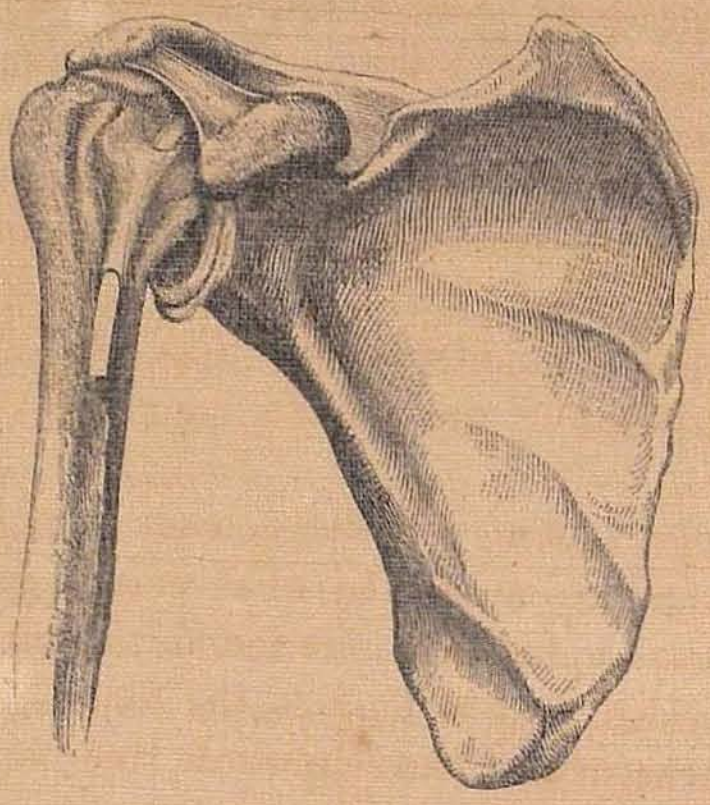

with the under surface of the acromion; the capsule was thickened and adherent, and in time, probably, anchylosis of the joint would have taken place. *

If the altered position of the bone, says Mr. Soden, be dependent on the displacement of the tendon, (and of this there can be no doubt from the injury being uncomplicated,) the biceps muscle must exercise a more extended influence than is usually attributed to it; and I think a consideration of the structure of the joint, independently of the evidence afforded by this case, will show that the long head is designed not merely to act as a ligament, but also to serve as a capsular muscle.

The head of the humerus is said to owe the security of its position rather to the combined influence of the capsular muscles, than to the ligamentous attachments of the humerus to the scapula; and the tendon is vaguely described as strengthening the joint, and in that respect, as bearing an analogy to the ligamentum teres of the femur. The capsular muscles may be considered as having their origin from the upper three-fourths of the circumference of a circle; they then converge towards its centre, represented by the head of the humerus, into the upper, anterior, and posterior parts of which they are inserted. In the lower segment of this circle, there is a gap (the axilla), not

* The injured joint has been deposited in the museum of King's College by Mr. Soden.

occupied by muscles. As the head of the bone rolls on an almost flat surface, its position is entirely under the control of the capsular muscles; it follows, therefore, that to enable the bone to maintain its equilibrium, these muscles should exactly antagonize each other; or, like the face in paralysis of the portio dura, the head of the humerus would be drawn to the side of the preponderating muscle. The necessity of a muscle from the ribs to the humerus, to counteract the upper capsular muscles, is probably superseded by the singular course of the long head of the biceps.

Mr. Partridge, of King's College, made some experiments to ascertain to what extent, and by what means, partial dislocation could be artificially produced. He found, though the capsule was completely divided, that so long as the tendon was undisturbed, no displacement of the bone upwards and forwards could be effected; and that division of the tendon alone was insufficient: but when the incision through the tendon included a small portion of the capsule, all impediment to the dislocation was removed.

The next case, which I give in the patient's own words, is an example of the troublesome consequences which sometimes follow dislocations of the shoulder.

Case CCXL.—"On the 19th of May I was overturned in a low four-wheeled vehicle, and pitched with so much violence on my left side on a flat stone, that I heard a crash, and on examination found the left shoulder not only dislocated, but dreadfully bruised. The arm was set by Dr. Wesstring, and leeches and bleeding were ordered, to prevent inflammation; all with success. But now my arm continues lame, and the upper arm and axilla hard and swollen, like a stuffed cushion; the hand is œdematous, the nails blue, and the ring and little fingers weak. Behind the axilla, near the lower part of the scapula, a tumor formed some weeks ago, hard and elastic, precisely like caoutchouc: it is the size of a small billiard ball; unchanged in colour, and not inflamed nor red. Warm poultices, bandages, liniments, and at my own request mercurial ointment, have been applied without success. Every twelve or fourteen days I am subject to spasms in my arm and limbs, which last from half an hour to three quarters; sleep I have none except by opium, and my nerves are so affected in general, that

I both lose courage and hope at times. My arm is perhaps a little softer, but every spasmodic attack hardens it again. In this manner I have continued till the present time."

I recommended aperients to keep the stomach and bowels in order, and a belladonna plaster.

Rupture of the Tendon of the Biceps.—This is an accident which I allude to in order that the surgeon may have more perfect materials for forming his diagnosis in cases of obscure injuries to the shoulder-joint. The symptoms and treatment are well exemplified by the following case, which I quote from Mr. Stanley's paper on the subject, in the third volume of the London Medical Gazette.

Case CCXLI.—" A gentleman, slipping from the footpath into the carriage-way, struck his shoulder against the curbstone, and at the same time twisted his arm inwards and backwards. Severe pain in the joint, and inability to put the biceps into action, were the immediate consequences of the accident; and in a few hours there was an effusion of blood into the subcutaneous cellular tissue, but confined to the track of the biceps muscle. Further, the slightest movement of the arm backwards was followed by acute pain, precisely in the situation where the tendon of the biceps turns over the head of the humerus. A rupture of this tendon was supposed to have taken place, and the arm was accordingly confined to the chest in a position fit to secure the quietude and relaxation of the biceps; but it was not until many weeks had elapsed that the least remission of the confinement of the arm was permitted without the recurrence of acute pain in the joint in the situation of the tendon. Eventually the recovery of the arm was complete."

Respecting another case, which occurred in the practice of Mr. Wormald, and which is quoted in Mr. Stanley's paper, it is observed, that " the effort of bending the fore arm was attended with a peculiar spasmodic and vibrating movement of that part of the biceps from which the long head is continued, and which was distinctly felt by the hand placed against the arm."

SECTION VI.

COMPOUND DISLOCATION OF THE OS HUMERI.

An injury of excessive violence will sometimes occasion the head of the bone to be forced through the integuments in the dislocation forwards. It happened in the practice of Mr. Saumarez, and of Mr. Dixon, of Newington; and for the following detail of its circumstances I am indebted to Mr. Dixon.

Case CCXLII.—Robert Price, fifty-five years of age, whilst in a state of intoxication, fell down upon his right shoulder. Upon examination, I found that the head of the bone had passed through the integuments in the axilla, and lay exposed upon the anterior part of the chest, on the pectoral muscle. The reduction of the dislocation was easy, and was performed by the ordinary methods without raising him from the state of stupor and insensibility in which he was lying; he was then put to bed, and an evaporating lotion applied. On the following morning considerable pain and tension had come on; for which he was bled, and purged freely; a large poultice was applied over the joint, and anodynes were given to lessen pain and procure sleep; leeches were frequently applied in the neighbourhood of the joint for the first ten days or fortnight, after which a copious discharge of pus issued from the wound in the axilla. The constitution now felt the effects of so important an injury; he became irritable and restless, and lost flesh: healthy pus was discharged freely from the joint for ten or twelve weeks, when it somewhat abated. A succession of small abscesses formed in the cellular membrane, surrounding the joint, and were exceedingly troublesome for several months, some forming extensive sinuses, and requiring to be freely dilated. The discharge from the joint was kept up nearly twelve months, when it finally ceased, leaving the joint anchylosed, and the wound closed. He was quite recovered in fourteen months from the accident, at which time he called on me, and felt gratified by showing how freely he could make use of the fore arm, and handle his pen for all the purposes of business.

Treatment.—Such a case will require an immediate reduction, by the means which I have described for the dislocation of

the os humeri forwards; and, in general, the greater the violence done to the injured limb, the more easy is the reduction, from the diminution of the constitutional powers which so great a shock produces. When the bone is replaced, lint dipped in blood is to be applied to the wound, or if the wound be large, a suture should be employed, and then the lint applied; adhesive plaster should be used to support approximation, and the limb should be kept close to the side by means of a roller passed round the body, including the arm, and thus preventing the least motion of the head of the bone; by these means the suppurative inflammation may be prevented, and the cure may proceed without protracted suffering, or any danger to the patient's life.

CHAPTER XII.

ON FRACTURES NEAR THE SHOULDER-JOINT, LIABLE TO BE MISTAKEN FOR DISLOCATIONS.

SECTION I.—FRACTURE OF THE ACROMION.

SYMPTOMS.—This point of bone is sometimes broken; and in this accident, when the shoulders are compared, the roundness of the injured side is seen to be lost, and since part of the attachment of the deltoid muscle is broken off, the head of the os humeri sinks towards the axilla as far as the capsular ligament will permit. On tracing the acromion from the spine of the scapula to the clavicle, just at their junction, a depression is felt, from the fall of the fractured portion. If the distance be measured from the sternal end of the clavicle to the extremity of the shoulder, it will be found lessened on the injured side. If the surgeon raises

the arm from the elbow, so as to put the deltoid muscle in motion, the natural form of the shoulder is directly restored, but the deformity returns immediately when the arm is again suffered to fall.

This accident is best detected and distinguished from dislocation by raising the arm at the elbow: having restored the figure of the part, the surgeon places his hand upon the acromion and rotates the arm, when a crepitus can be distinctly perceived at the point of the shoulder, and along the superior portion of the spine of the scapula. The patient, as soon as the accident has happened, feels as if his arm were falling off, the shoulder dropping with a great sense of weight, and there being but little power to raise the limb.

This figure shows a fractured acromion; the edges of the fractured surfaces are united by ligament, part of which has been turned aside to show ligamentous granulations upon the fractured surface.

Treatment.—Fracture of the acromion may unite by bone; but it generally unites by ligament, in consequence of the difficulty which exists in producing adaptation, and in preserving the limb perfectly at rest during the period required for union. In the treatment of this accident, the head of the os humeri is the splint which is employed to keep the acromion in its natural situation; and with this view the elbow is raised, and the arm is fixed; thus the bone will be elevated to the inferior surface of the acromion, and if it be kept steadily in that position, it will support and keep in its place the broken process. The deltoid muscle should be also relaxed, and this is best effected by a cushion placed between the elbow and the side; for if the elbow be brought close to the side, the broken acromion is further separated. The arm should be raised as much as is possible, and the elbow be carried a little backwards, and then bound to the chest by a roller; in this position it should be kept firmly fixed for three weeks, everything being done to prevent any motion of the bone. Very little inflammation succeeds this accident, and the disposition to ossific union is very feeble in the separated portions of bone.

If a pad be placed in the axilla, the broken portion becomes widely separated from the spine of the scapula, because it throws out the head of the os humeri.

SECTION II.

FRACTURE OF THE NECK OF THE SCAPULA.

SYMPTOMS.—This accident is much more liable to be mistaken for dislocation than the preceding. When I speak of fracture of the cervix scapulæ, I mean a fracture through the narrow part of the bone, immediately opposite the notch of the superior costa; by which the glenoid cavity becomes detached from the scapula, and the head of the bone falls with it into the axilla. The shoulder also falls; there is a hollow below the acromion from the sinking of the deltoid muscle; and the head of the os humeri can be felt in the axilla.

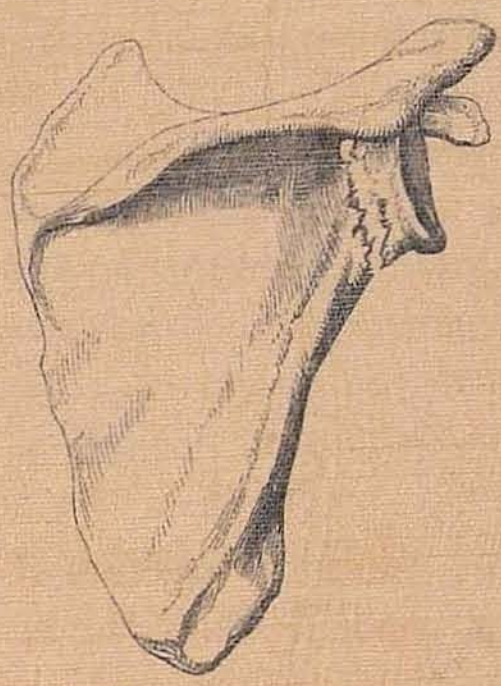

CASE CCXLIII.—Mrs. R., in February, 1834, was thrown from a gig by the wheel running upon a bank. She was stunned by the fall, and remained insensible some little time; she then found that her head, shoulder, hip, and ankle, on the right side, were much bruised, so much so that she was unable to move either of them, from pain and swelling; the chief bruise on the shoulder was at the upper and back part. Thinking that the stiffness of the shoulder, as well as of the hip and ankle, arose merely from the bruise, no surgeon saw her until ten days after the accident, when she found that, notwithstanding the swelling had subsided, she was unable to move her arm. The surgeon, mistaking the case for dislocation, placed his knee in the axilla, and made violent extension; finding, however, that upon removing the knee, the shoulder again assumed its original flattened appearance, he said that there was a fracture somewhere, but could not say exactly at what part; he then placed a pad in the axilla, and put on a figure of 8 bandage, confining the arm to the side by another bandage. Swelling and inflammation about the shoulder-joint followed the use of the extending force, to such an

extent as to render the removal of the bandage immediately necessary. Leeches, cold lotions, and strict antiphlogistic regimen reduced this, and in a week or ten days the bandages were again applied, and continued for six weeks, being renewed several times during that period. At the end of this time all the bandages were removed, and the patient desired gradually to use the arm as much as she was able; she could not, however, use it in the slightest degree, and even the passive motion made use of greatly increased her suffering, and produced several attacks of inflammation of the part. These were reduced as before, and she continued the passive motion, under the direction of her surgeon, (notwithstanding that it much increased her suffering,) until July, when the pain which the slightest motion gave her had increased to such an extent that she could bear it no longer. In the commencement of August, at the request of her brother, she came to town for further advice, when the state of the case was as follows.

The right shoulder was flattened, the arm dropped, the coracoid process of the affected side was on a plane nearly an inch lower than the opposite, the head of the bone and edge of the glenoid cavity might be felt in the axilla, and by placing the finger upon the under edge of that cavity, and raising it, the whole arm was reduced to its natural appearance, and at the same time a distinct crepitus was felt. There was some deformity at the top of the shoulder, however, still remaining, from the clavicle having been fractured close to its acromial extremity and from its having united without being reduced; it was the acromial portion which in this case rode over the end of the sternal. A crepitus was also distinctly felt, by placing the fore and middle finger upon the coracoid process, and the thumb on the back part of the shoulder, and thus moving the glenoid cavity from side to side, marking the case clearly to be one of non-united fracture of the cervix of the scapula.

A thick cushion was therefore placed in the axilla, and the shoulder being raised to its natural position, a bandage was passed under the arm and over the shoulder, being at the same time passed once or twice around the chest to prevent its slipping off the shoulder.

The arm was confined to the side, and the elbow supported by a pasteboard sling. In this way was the patient made compara-

tively easy, the natural roundness of the shoulder restored, and she was enabled to turn and move in bed, which, before the shoulder was fixed, she was unable to do, from the great pain it occasioned.

Case CCXLIV.—In the year 1829, I was consulted by Mr. Alderman Partridge, of Colchester, respecting a case of this accident, which he described in the following words:—

" Mr. P., of Colchester, met with an accident about five months since, by a fall from his chaise. I was requested to meet Dr. Nunn, who had been in attendance for two or three days; and it then appeared to have been a dislocation of the humerus into the axilla, and I could see no reason to doubt but that Dr. Nunn had reduced it; but I must confess that the tumefaction and tension were so considerable that it became a difficult matter to decide: however, both from what he himself stated at the time, as well as from Dr. Nunn's and my own personal observation, I gave it as my opinion that it was reduced, although that shoulder appeared rather lower than the other. This I had observed in other cases, but in this instance it struck me to be rather more than common, and led me to conclude (which I stated at the time), that a considerable portion of the glenoid cavity had been fractured off. I saw him several times afterwards; and although the swelling continued for several weeks, still it became more and more observable that some very serious injury had been done to the glenoid cavity; and when I saw him at about a month or six weeks from the accident, I could, by placing my hand in the axilla, and pushing at the elbow, bring the head of the humerus up and rotate it in the glenoid cavity; and still persisted in my former opinion. I was again requested to see him about a week since, when I found the head of the bone resting, where you will I doubt not find it; and conveying to the feel a certain crepitus, which still leads me to suppose that the glenoid cavity has received the injury I have described, and how far the chances go for any benefit by an effort to replace it after such a lapse of time I must leave to you."

The degree of deformity produced by this accident depends upon the extent of laceration of a ligament which passes from the under part of the spine of the scapula to the glenoid cavity, and which is not generally described in anatomical books. If this be torn, the glenoid cavity and the head of the os humeri

fall deeply into the axilla; but the displacement is much less if this remain whole.

Diagnosis.—The diagnostic marks of this accident are three: first, the facility with which the parts are replaced; secondly, the immediate fall of the head of the bone into the axilla, when the extension is removed; and thirdly, the crepitus which is felt at the extremity of the coracoid process of the scapula, when the arm is rotated. The best method of discovering the crepitus is, for the surgeon's hand to be placed over the top of the shoulder, and the point of the fore-finger to be rested on the coracoid process; the arm being then rotated, the crepitus is directly perceived, because the coracoid process being attached to the glenoid cavity, and being broken off with it, although itself uninjured, the crepitus is communicated through the medium of that process.

Case CCXLV.—A young lady was thrown from a gig, by the fall of the horse, in the Strand; and being carried to her house, a surgeon in the neighbourhood was sent for, who told her the shoulder was dislocated; by extension all the appearances of dislocation were removed, and he bound up the arm. On the following morning he requested me to see the case, as the arm, he said, was again dislocated. On examination I found the head of the bone in the axilla, and the shoulder so fallen and flattened, as to give to the accident many of the characters of dislocation; however, by elevating the shoulder, and by raising the arm at the elbow, and the head of the bone from the axilla, it was immediately replaced; but when I gave up this support the limb instantly sunk again. I then rotated the elbow, and pressing the coracoid process of the scapula with my fingers, by grasping the top of the shoulder, directly felt a crepitus. Having satisfactorily ascertained the nature of the accident, I placed a thick cushion in the axilla, and drawing the shoulder into its natural position, secured it by the application of a clavicle bandage, and in seven weeks the part united without deformity.

Treatment.—The treatment of this fracture consists in attention to two principles. The first is to carry the head of the os humeri outwards; and the second, to raise the glenoid cavity and arm. The former is effected by a thick cushion placed in the axilla, which presses the head of the bone and glenoid cavity outwards, and this may be confined by the clavicle bandage; and the latter is produced by placing the arm in a short sling, and thus

the head of the os humeri being raised supports the glenoid cavity and cervix scapulæ, and keeps it steadily in its place until union is produced. The time required for recovery from these accidents in the adult, is from ten to twelve weeks; in the very young, all the motions of the limb are restored in a shorter period, but it is a long time before the limb recovers its strength.

SECTION III.

FRACTURES OF THE HEAD AND NECK OF THE OS HUMERI.

These accidents are of three kinds:—

First. Dislocations of the os humeri into the axilla, with fracture, and detachment of the head of the bone, which is thrown on the inner side of the inferior costa of the scapula.

Secondly. Fractures through the neck of the bone at the tubercles; in which the head of the humerus is broken off, but remains in the glenoid cavity. This fracture occurs at the epiphysis, or *anatomical neck* of the bone.

Thirdly. Fractures below the articulation, between it and the insertions of the pectoralis major, latissimus dorsi, teres major, coraco-brachialis, and deltoid muscles. This part has been called the surgical neck of the bone.

DISLOCATION AND FRACTURE.

This accident generally occurs in the following way. A person falls and pitches with violence on his shoulder, or a heavily laden carriage passes over it. By the first impression of the accident, the os humeri is dislocated; and by a second the neck of the bone is broken, and the head is detached, and lodges in the axilla.

The symptoms of this injury are those which usually accompany dislocation of the os humeri into the axilla, the head of the bone being there felt; but there is somewhat less hollow below the acromion and behind the deltoid muscle, because the broken extremity of the shaft of the bone quits the head, and lodges in the glenoid cavity of the scapula. Upon rolling the arm, the broken shaft of the bone can be perceived to move under the

acromion. There is but little power of motion, and considerable pain, not only in the shoulder, but in the arm and hand.

The head of the os humeri can be felt when the arm is raised, and the surgeon's fingers are thrust into the axilla; but when the arm is rolled at the elbow, the head of the bone remains entirely unmoved, or very little obedient to the motions of the elbow.

There is in some cases, but not always, a distinct crepitus; but more frequently a gristly feeling, from friction of the broken neck of the bone against the glenoid cavity and its cartilaginous covering.

The broken end of the os humeri is drawn somewhat forwards; but is easily pushed into the glenoid cavity, from which, unless it be supported, it is again drawn by the pectoralis and coraco-brachialis muscles.

The arm, measured from the acromion to the elbow, is shorter than the other.

As this accident is occasioned by great violence, the parts are much obscured by the effusion of blood, and by the inflammation which speedily follows; but for the first three hours the muscles are so lax, that, but for the pain it occasions, considerable motion of the limb might be produced.

FRACTURE OF THE NECK OF THE OS HUMERI, WITH THE DISLOCATION FORWARDS, UNDER THE PECTORAL MUSCLE.

Case CCXLVI.—Mr. John Blackburn fell from his horse, many years ago, at Enfield, and dislocated his shoulder forwards. Mr. Lucas, sen., surgeon of Guy's Hospital, was sent for; who said, after he had made considerable extension, that the bone was reduced. Five weeks afterwards, Mr. B. came to London, and showed me his shoulder, when, the appearances of dislocation still remaining, I advised a further extension, to which he would not consent. I had frequent opportunities of seeing him afterwards, but the shoulder exhibited the same appearances of dislocation. He had, however, the power of using the hand and arm in all directions excepting upwards, but could not raise his arm parallel with his body; and he suffered but little pain or inconvenience.

In June 1824, he died; and as he had always promised me the dissection of his shoulder if I survived him, I removed it

in the presence of Mr. Arnott, Surgeon of Greenwich Hospital, examined it with great care, and have the bones preserved.

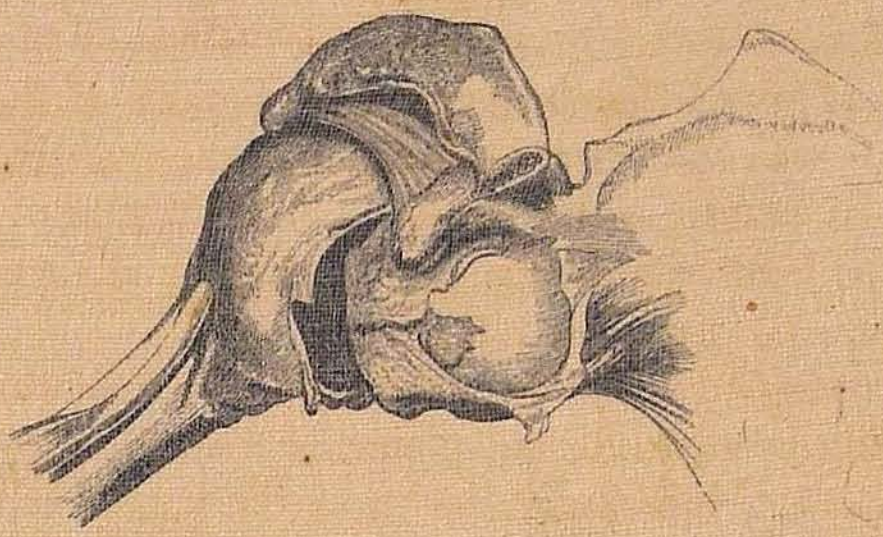

The deltoid, teres major, and coraco-brachialis muscles did not appear to me to be altered; the supra-spinatus was lessened, as was the teres minor, which had lost much of its natural colour: the infra-spinatus was stretched; the subscapularis, diminished and rounded by the projection of the head of the os humeri, adhered to its cartilaginous surface. The capsular ligament was torn under the subscapularis muscle, but every other part was entire. The head of the os humeri had been thrown forwards on the inner side of the coracoid process, and had united by bone to the scapula; but its cartilage remained under the tendon of the subscapularis. The neck of the os humeri was broken through, and had been covered by a granular ligamentous substance; but the parts were kept together only by the ligament of the joint, and a new and very useful joint had been formed. The outer edge of the glenoid cavity remained; the surface of the glenoid cavity was granulated and ligamentous. The greater tubercle of the os humeri was exceedingly increased, and the tendon of the biceps passed through the bone. The tubercles were separated with the body of the bone, and not with its head.

This, then, was a case of fracture of the cervix humeri within the capsular ligament, terminating in a ligamentous union.

Case CCXLVII.—I examined the body of Mr. Hollingsworth, who died of stricture of the urethra, and diseased bladder and kidneys. When these parts had been traced, to see the changes

which they had undergone, I said to the surgeon who attended him with me, "Had he any accident, or other disease, to your knowledge?" and he answered, "Why, he once broke the neck of his scapula, for which I attended him; and he never recovered the use of his arm." Upon looking at his shoulder, I found it sunken, and altered in shape; and I observed that I thought I had seen the accident in living patients, but I never had an opportunity of observing the morbid appearances in the dead; and therefore, I said, "We must not neglect to look into this accident, and to add the fractured parts, as a preparation, to my collection."

Upon inspecting the shoulder-joint, I found the neck of the scapula uninjured; but the head of the os humeri was dislocated into the axilla, and broken from the shaft; and it remained upon the inner side of the inferior costa of the scapula, to which it was firmly united.

The tubercles of the neck of the os humeri were broken off with the head of the bone; and the fractured extremity of the neck of the os humeri was placed in the glenoid cavity of the scapula. The underhand motions of the shoulder were restored; but the elevation of the bone, beyond a right angle, was strongly resisted, and could be accomplished with difficulty even in the dead body.

For the next case I have to thank Mr. James Newton Heale, who sent me the injured parts for my inspection.

Case CCXLVIII.—A respectable farmer, æt. about sixty, in crossing his field in the evening after dark, during the severe frost of Dec. 1835, missed the pathway and slipped into a deep dry ditch, and fell heavily on the opposite side. In my absence, my assistant went to him, and, as he supposed, reduced a dislocation of the shoulder; but on my return he requested me to see the patient, which I did, and found a considerable depression beneath the acromion, exactly resembling an ordinary dislocation; there also appeared a prominence in front and rather below the coracoid process, beneath the pectoral muscle, as in the anterior dislocation of the humerus; but I found on handling the arm that it admitted of free motion. I therefore concluded that the case was a fracture; but finding that I could not by any movement of the arm remove the depression beneath the acromion, I searched carefully for the head of the bone, and, the

muscles being then exceedingly flaccid, I found I could grasp it in the situation I have named as where the tumour was perceptible. My assistant assured me that he felt distinctly the shaft of the bone pass into the glenoid cavity in the supposed reduction, as in an ordinary dislocation, and the patient also declared that he both felt and heard it do so, and that his pain was immediately relieved. The following morning, the muscles having contracted, and considerable swelling having taken place, the exact nature of the accident appeared by no means so distinct, nor did it during the lifetime of the patient again become otherwise than extremely obscure. I had the pleasure of twice showing the patient to Sir Astley Cooper. The case was treated exactly as one would a common fracture of the humerus near the shoulder; a large round pad was put into the axilla, which was kept in its place by means of a short splint well padded, thrust well up into the axilla, and secured there by means of a bandage passing round the arm. The elbow was elevated by a sling, and the arm secured to the side. After a few weeks the bandages were removed and passive motion adopted, and in the course of a few months our patient recovered all the under motions of the arm, but could not raise it to an horizontal position. The natural roundness of the shoulder did not return.

In Feb. 1837, about fifteen months after the accident, he died of diseased liver, and I obtained permission to make a post-mortem examination. I found the humerus fractured at its anatomical cervix, and the head of the bone resting on the outside of the tendon of the subscapularis muscle; the fractured end of the shaft of the bone had become rounded, forming a new head; the capsular ligament was ruptured, but not sufficiently to allow the original head of the humerus to pass through; the long head of the biceps had been ruptured, but had become adherent to the new head of the humerus, which rested in the glenoid cavity.

A further dissection of the parts was subsequently made by Sir A. Cooper, who found that the dislocated head was united to the side of the shaft of the humerus by a small process of bone, whereby it partook in every movement of the humerus.

The next case was published by Mr. Hingestone, in the 11th Number of the Guy's Hospital Reports.

Case CCXLIX.—Mr. P., aged sixty-three, of a spare habit, and in declining health, the muscular structure being slender and

feeble, on the 20th of October, 1839, was going down the cellar stairs with some heavy ledgers in both arms, when his foot caught against a projection on the edge of the steps, and he tripped and pitched down head-foremost. He fell with the left arm stretched out, and at the same time received a blow on the back of the humerus; by which violence, it would seem, the arm was knocked forward, while the head of the bone was pulled backwards by the scapular muscles, the scapula itself being the fulcrum. The head of the humerus was in this manner at once both fractured and dislocated, the fracture traversing the anatomical neck of the humerus.

SIGNS.—A falling down of the left shoulder; empty glenoid cavity; arm close to the side; the patient supporting the elbow of the injured arm in the opposite hand; the palm of the hand of the injured limb lying flat against the stomach; that is, half supine.

On looking at the patient a short distance off, there was a visible protuberance under the clavicle, elevating the pectoral muscles; the axis of the limb, however, not being that of a dislocated shoulder. On examining the shoulder by touch, the head of the humerus was easily perceptible to the fingers of the operator, both under the clavicle and in the axilla. By placing the knee under the axilla, and making the usual extension for reducing dislocation, the operator, while in the act of pressing down the elbow, felt the grating of a fracture under the hand that grasped the shoulder-joint. Then, by grasping the shoulder and dislocated head of the humerus with the fingers of the one hand, and at the same time (the knee being still in the axilla) grasping the elbow with the other hand, and jerking the shaft of the humerus upwards and outwards, the grating of the fracture became perceptible, frequent, and unequivocal. On the operator removing his hands, and not interfering in the least with the injured limb, but steadily looking at it in front, he could observe (as the patient was very thin) a manifest incongruity between the site of the dislocated head and the axis of the pendulous shaft of the bone. On searching at the top of the bone close to the dislocation and fracture, the fingers of the operator could be slipped into the fissure caused by the fracture between the separated ends of the bone.

The treatment was simply that of supporting the limb in a

sling, and the application of poultices, fomentations, &c. to assuage pain. The constitutional symptoms set in reluctantly and mildly. The pain was not so great as is usual in cases of fracture through a joint, and sleep was easily obtained by the syrup of poppies. Œdema slowly arose along the whole of the limb; and the back of the arm and parts about the elbow became greatly distended, as well as discoloured from ecchymosed blood. The position which the patient found he could assume the most easily to himself was that of sitting up in a chair with the left foot raised on a stool, and the elbow of the injured limb supported on the left knee, with the fore-arm held half supine by the sound hand against the stomach. The sling round the neck could not be borne while it supported the elbow, but only when suspending the wrist alone.

As the case proceeded, there was to be remarked a difficulty of supination and extension of the fore-arm, an inability to raise the elbow from the side, and a partial filling up of the glenoid cavity. At this period (December 16th) there were all the signs of simple dislocation, with the remarkable fixture of the fore-arm at a right angle across the body. Indeed, if this case, as it then was, had been seen for the first time, the surgeon would, on a *primâ facie* view of it, have had no hesitation in pronouncing it to be an unreduced dislocation; and on this account the subsidence of the swelling was awaited with some impatience, in order to make a more accurate examination of the condition of the joint.

By the 21st of December (exactly two months after the accident) the shoulder was carefully examined, and a drawing made of it. The condition of the limb was as follows:—

First. The head of the humerus was broken off, and lying under the outer end of the clavicle in front of the coracoid process of the scapula.

Secondly. The glenoid cavity was empty, but somewhat filled up anteriorly by the head of the humerus resting on the anterior edge of the articulating cup.

Thirdly. The fractured end of the shaft of the humerus was touching the under edge of the articulating cup, and lying in juxta-position to the head of the humerus, but at an obtuse angle with it.

Fourthly. A line was running visibly between the top of the

shaft of the bone and its head, with a perceptible depression between the two separated portions of bone, showing the nature of the injury unequivocally.

Fifthly. Coagulable lymph had been thrown out around the injury, but was in progress of absorption.

Sixthly. The belly of the biceps muscle was attenuated, the muscle itself being disabled. It was this disability of the biceps muscle which was the cause of the embarrassment in the movements of the fore-arm; for the following reasons :—

1. The long head of the biceps was interfered with in some manner at its origin in the edge of the glenoid cavity, and probably also the short head at the coracoid process, the tendon having been injured, lacerated, entangled, or thrown out of its groove, so as to render it unserviceable.

2. The belly of the muscle was wasting, upon the common principle of absorption, in parts which have become useless.

3. The disability of the muscle prevented the flexion of the fore-arm.

4. The tonic contraction of the muscle prevented extension of the fore-arm.

5. The same tonic contraction kept the fascia of the fore-arm tight, by means of the fascial process extending from the biceps tendon, just before its insertion into the tubercle of the radius; by being kept thus on the stretch, the fascia effectually restrained supination. Of the motions of the limb, there were, 1st, rotation outwards; 2ndly, extension of the fore-arm; 3rdly, supination; and, 4thly, elevation of the humerus from the side, all existing clearly in an absolute though limited degree. There was no union between the fractured head and shaft of the bone; there was an easy though very limited play of the fractured end of the humerus at the lower end of the glenoid cavity, and a false joint was probably in a state of formation. The mobility of the broken end of the bone, as well as the existence of the four elementary movements above stated, was quite sufficient to warrant the opinion, that, by the practice of passive motion daily all the under movements of the shoulder-joint would be recovered.

Before the recovery was accomplished the patient died, January 23rd, 1840, three months from the time of his receiving the injury. He sank, worn out by constitutional irritation. All the omens of death settled upon him. Extreme nervous exhaustion,

insomnolence, very irregular and difficult respiration (orthopnoea), a pulse becoming progressively more and more accelerated, tumultuous and remote action of the heart, thirst, loss of appetite, wasting, delirium, œdema, petechiæ, anasarca, and ascites, foretold and brought on the inevitable event.

Before this event arrived he was able to raise his fingers to his lips, and to rest upon the elbow of the injured arm.

Permission was obtained to remove the limb, and the dissection of the parts about the joint presented the following appearances:—

The muscles were shrivelled, but free from effusion. Beneath the deltoid, the humerus close to the neck was found to have been broken into six pieces, and united by new bone. The glenoid cavity was seen empty, and covered with its cartilage, the axis of the limb being directed towards it. The head of the humerus was felt beneath the glenoid cavity, resting on the inferior costa, just below the cervix scapulæ, with its articulating surface directed downwards. It was clearly invested by its capsular ligament, which was entire, the breach caused by its dislocation having been repaired. On opening it, the head of the bone presented its usual appearance, retaining its cartilage, and being smooth and polished. The tendons of the spinati and subscapularis appeared thickened, but were entire, as if they had been torn and repaired. The long tendon of the biceps was torn from its origin, and entangled among the fragments of the fracture, above which it could not be traced. The motion enjoyed by the articulation was very limited, being restrained by a process of union going on between the glenoid cavity and a fragment of the humerus lying in contact with it. This union was chiefly by means of an imperfectly ossified matter, and therefore allowing a slight degree of motion. This union might probably have been prevented by a continuance of passive motion.

Case CCL.—A woman, about sixty years of age, came to Guy's Hospital for advice in the end of August 1834, complaining of her shoulder being out of joint in consequence of a fall down stairs six weeks before; and the attempt at reduction having failed at the period of the accident, I was of opinion with Mr. Key, that further attempts should be made. Upon examination of the limb there were all the appearances of a dislocation into the axilla, the head of the bone being thrown, how-

ever, rather further back than usual, being perceptible on a plane posterior to the inferior costa of the scapula; and on moving the limb a crepitus could be felt as if the head of the bone moved on the scapula. The woman being muscular, and the accident having occurred at a distant period, Mr. Key applied the pulleys, and upon rather a new plan, adapting their application in a similar manner to their employment in dislocation of the femur into the foramen ovale; viz., the counter-extension was made as usual, but the extending medium was placed high up the arm, as near the head of the bone as possible; and the force was employed at a right angle with the body, the woman being placed in the sitting posture, while Mr. Key directed the elbow inwards towards the middle line; but during the application of this extension, crepitus was rendered so distinct as to convince us all, that fracture was concomitant with the dislocation, and therefore all further attempts at the reduction were stopped. The fracture appeared to be through the humerus just below its tubercles.

Diagnosis.—With regard to the marks of distinction between this accident and the dislocation into the axilla, I would observe that the fall and depression of the shoulder is less striking than in the latter accident, as the shaft of the bone fills up the glenoid cavity.

That the head of the humerus can still be distinctly felt in the axilla; and that, as it does not roll when the os humeri is rotated from the elbow, this becomes the principal diagnostic mark.

That a grating sensation can generally be felt, and sometimes a very distinct crepitus, especially if the elbow be raised outwards during the rotation of the arm.

That the upper extremity of the shaft of the humerus can be felt advancing to the coracoid process; but that it is easily returned into the glenoid cavity, and that it there rotates with the arm, but easily again slips forward.

That the accident which produces it is much more severe than that by which simple dislocation into the axilla is produced; and there is, therefore, more contusion, more swelling, and more pain.

Treatment.—Extension is of no further use, than to bring the broken shaft of the os humeri into the glenoid cavity, where

it forms a useful articulation; but no extension, however violent, disturbs the broken head of the bone, for no proper force could bring it into the glenoid cavity of the scapula. If reduction be ever effected, it will probably be by an extension with the heel or knee in the axilla.

To keep the broken end of the shaft of the bone in the glenoid cavity, a pad must be put into the axilla to thrust it outwards, a clavicular bandage must be used, and the arm be supported in a sling.

But let the surgeon do what he will, the head of the bone will probably remain in the axilla, and the upper motions of the arm will be in a considerable degree lost.

These cases should teach the members of our profession to be kind, generous, and liberal towards each other; and not to impute to ignorance or inattention that which is the result of a generally incurable accident. It too often happens, that when every trial has been made to restore the parts, and without success, the patient goes to some other surgeon, to whom he shows the arm, and points out its uselessness and want of motion. A jealous and illiberal medical man might say, "Yes, this is a dislocation which has not been reduced: I wish I had seen it at first; but now it is too late for a successful attempt to reduce it." However, every well-informed surgeon will now confess, that no knowledge or exertion of skill could have prevented the deformity and loss of the natural motions which result from this formidable accident.

FRACTURE THROUGH THE TUBERCLES, OR AT THE ANATOMICAL NECK.

This is a very frequent occurrence in young people; it sometimes, though more rarely, happens in the old; in middle age it seldom occurs.

In children it is the result of falls upon the shoulder; or it happens from a sudden or unexpected push of the arm which it is unprepared to resist.

I have seen it complicated with fracture of the clavicle; but this makes no difference in the treatment. The signs of this accident are as follow:—

The head of the bone remains in the glenoid cavity of the scapula; so that the shoulder is not sunken, as in dislocation.

When the shoulder is examined, a projection of bone is perceived upon the point of the coracoid process; and when the elbow is raised and brought forwards, this projection is rendered particularly conspicuous.

By drawing down the arm the projection is removed; but it immediately reappears upon giving up the extension, and the natural contour of the shoulder is lost.

The motion of the shoulder is painful; and the patient cannot raise the arm but with his other hand; the elbow is with difficulty removed from the side; and the arm is obliged to be supported, either by the patient himself, or by aid of another.

Diagnosis.—The diagnosis of this injury is not difficult; yet I have known the accident mistaken for dislocation. The point of the broken bone is felt at the coracoid process, and this is supposed to be the head of the os humeri; but, with care, the head of the bone can be felt still filling the glenoid cavity. When the elbow is rolled, the head of the bone does not obey its motion.

A slight extension draws the broken point of the bone into the natural position, beneath the head, from which it has been separated; but it always immediately projects forwards again when the extension is lessened or removed.

Upon the dissection of these cases in the young, the head of the os humeri is found broken off at the tubercles, but it remains in the glenoid cavity.

A great quantity of ossific matter is thrown out from the periosteum and fractured neck of the shaft of the bone, but very little from the broken head. A cup of bone is formed upon the fractured neck of the shaft, in one of my preparations, which supports the head of the bone, so as to prevent the neck separating from it. A slight union is produced by the cancellated structure; the principal callus being formed on the outer surface, and it encases the bone.

In old persons this accident is comparatively rare, but the following is a case which illustrates it; and I am indebted to Mr. Webster, surgeon, in the Edgeware-road, for seeing the patient and for giving me an opportunity of a post-mortem examination of the shoulder.

Case CCLI.—A commander in the royal navy, æt. seventy-seven, a strong and muscular man, was violently thrown out of

a street cab on the 31st December, 1835. He could give no description of the accident; but it appeared that he fell upon the left shoulder and side of the forehead, the latter being much cut, and the shoulder seriously injured. On examination, the power of the arm was found to be lost. The shoulder was enormously swollen, and its rotundity diminished; there was a depression in the situation of the belly of the deltoid muscle; and a hard tumor, which appeared to be the head of the humerus, was felt under the clavicle, and just on the edge of the glenoid cavity, close under the coracoid process.

An obscure crepitus was perceived, which was supposed to arise from a fracture of the coracoid process; the arm was about an inch shorter than the opposite. Extension was made, and the bone returned to its situation without much difficulty, after which, bandages were applied, and the arm was placed in a sling.

Enormous swelling and ecchymosis of the whole limb took place, accompanied with acute febrile symptoms, so that the bandages were obliged to be removed, and 16 oz. of blood taken in the evening, and cold lotions were applied to the head. The violence of the symptoms gradually subsided, and in sixteen days the arm had resumed almost its natural size, but the swelling of the shoulder still remained; and the pain on motion was so great, that the patient would not suffer any examination to be made which caused the slightest disturbance of the limb.

There appeared a flatness on the upper part of the shoulder, and a large hard tumor, supposed to be the head of the bone, under the situation of the coracoid process. The patient positively refused to have anything more done for him, as his pain was decreasing, and the use of the hand returning.

In the beginning of February passive motion was carefully employed, with friction, and, in three weeks more, considerable use of the limb had been regained. The arm, however, could not be raised to a level with the shoulder, nor could it be brought forward over the chest. Every day seemed to improve the condition of the limb, when, on the 2nd of March, eight weeks after the accident, whilst taking a walk, he was seized with apoplexy, and died in a few minutes.

The dissection took place on the 5th of March, in the pre-

sence of Sir A. Cooper, Mr. Girdwood, and Mr. Balderson; and a large coagulum was discovered in the left ventricle of the brain.

It is worthy of remark, that the bones of the cranium and shins had been, in early life, much injured by syphilitic disease.

Mr. Webster had the kindness to give me the parts of the injured shoulder, for particular inspection; and I have prepared a wet and a dried section of the injured articulation.

The accident must have been of a most violent description, as the parts of the joint were absolutely comminuted.

1st. The acromion was broken off; and had formed a ligamentous union with the spine of the scapula, from which it had been separated.

2dly. The coracoid process had been broken at its root; but was becoming again united, by ligament, to the scapula.

3dly. The head of the os humeri was broken through at the tubercles, or, as it is called, the anatomical neck. The periosteum of the neck of the bone, below the tubercles, had thrown out a considerable quantity of ossific matter, and had united the broken shaft or neck to the head of the bone.

The cancellated structure of the neck of the bone was beginning to unite the fractured head of the os humeri to the shaft of the bone.

This was a very formidable accident; and a person less ably instructed in his profession than Mr. Webster, might have employed painful, useless, and hopeless extension.

Treatment.—The best mode of treating these accidents consists, in the young, in applying a splint on the fore and back part of the arm, binding it on by a roller; placing a pad in the axilla, and using a clavicular bandage; supporting the hand, but not the elbow, in a sling; as, if the elbow be raised, the broken end of the bone projects forwards.

In old persons the injury is more severe, and the force producing it is violent: it therefore becomes necessary to reduce inflammation, and to apply leeches and evaporating lotions; to observe perfect rest at first; and, after some time, the same treatment, as to bandages, may be pursued as in the young.

In both the old and the young, passive motion is to be employed so soon as the union is effected, which, in youth, is in a

month; but it requires from two months to twenty weeks in old age.

A child was brought to Guy's Hospital some years ago with this accident, and I made the following notes of the case.

Case CCLII.—Its age was ten years. The symptoms of the injury were inability of moving the elbow from the side, or of supporting the arm, unless by the aid of the other hand, without great pain. The tension which succeeded filled up the hollow which was at first produced by the fall of the deltoid muscle. When the head of the bone was fixed, the fractured extremity of the body of the humerus could be tilted under the deltoid muscle, so as to be felt, and even shown, by raising the arm at the elbow. Crepitus could be perceived, not by rotating the arm, but by raising the bone and pushing it outwards. The cause of the fracture was a fall upon the shoulder into a saw-pit of the depth of eight feet.

Case CCLIII. — Mr. Tyrrell informs me, that in a case of fracture at the tubercles, he found that the bone best maintained its natural position, by its being raised and supported at a right angle with the side, by a rectangular splint, a part of which rested against the side, whilst the arm reposed upon the other part; and until he had made use of this plan, he could not succeed in removing the deformity, or in keeping the bone in its place.

Mr. Guthrie has given an interesting account of a curious case of fracture at the neck of the bone in the Medico-Chirurgical Transactions, vol. viii. p. 289:—

Case CCLIV. — A man fell from a ladder, and received a severe injury on the shoulder. Mr. Guthrie saw him about three hours after the accident; and the most remarkable and striking appearance was a fold or pucker of the skin, the size of half a crown, situated over the pectoral muscle. A hard substance could be felt below, and extending above it to the coracoid process. He says, "I decided that it was a fracture; not a dislocation. The arm was movable in every direction, and the elbow could be brought close to the side." After the swelling had subsided, he says, "I decided that the bone had been broken in its anatomical neck, and forced through the pectoral muscle."

He found that he could bring the bone down to its natural

situation, as to length; but it would not remain exactly in its proper place.

The man recovered, with a good use of the arm, so that the case terminated very favourably.

FRACTURE THROUGH THE SURGICAL NECK, OR BELOW THE TUBERCLES.

CASE CCLV.—In this case there is great deformity of the bone: the head, neck, and tubercles remain in the glenoid cavity, with part of the shaft of the bone connected with them, but the broken end of the shaft is drawn forward and upward under the pectoralis major muscle.

When the elbow is thrust upwards the broken extremity of the bone projects on the inner side of the coracoid process of the scapula, and it sinks when the support of the elbow is removed.

When the arm is rotated at the elbow, the broken end of the lower part of the bone is felt to roll.

There is no marked depression under the acromion, or but very little, if any; and then it happens from the deltoid muscle being dragged down.

The motion of the shoulder is extremely painful, and the patient has generally one or more fingers affected; sometimes contracted, at others painful only, and this depends upon one or other of the nerves of the axillary plexus being irritated by a part of the bone.

The elbow admits of being moved in all directions, for there is much less confinement in the arm at the shoulder than in the other accidents of that part; however the movements are very painful.

The diagnostic signs of this accident are found in the head of the bone being in its cavity, in its being unaffected by the rotation of the elbow, in the point of the fractured neck being felt under the pectoral muscle, and in the surgeon being able to move the arm much more freely than in the other fractures of the neck of the bone.

The adjoining figure represents a double fracture of this kind well united. The next case is one of fracture of the surgical neck of the bone nearer to its head than usual, which I received from Mr. Blenkarne, surgeon, of Dowgate-hill, and in which the symptoms are well marked.

CASE CCLV.—Samuel Shenstone, aged seventy-one, (a patient of Mr. Blenkarne's,) residing at Valentine-place, Bermondsey, returning home on the evening of the 25th of March, 1836, was knocked down, and fell against the edge of the curb-stone. On being picked up, his right arm was found to be totally useless, and very painful. On the following morning I was sent for, says Mr. Blenkarne, to attend him. On examination, I found he had entirely lost the power of raising the arm from the side, and required it to be supported; the elbow could not be straightened, the little finger was quite drawn to the palm of the hand; and the next three fingers were more or less contracted: the thumb did not appear affected; there was numbness of the little finger and of the two next, but not of the thumb and fore-finger. The roundness of the shoulder was lost, but, by lifting the shaft of the bone, it was restored. The hand could be raised to the head by assistance, but this was attended with excruciating pain. On rotating the limb at the elbow, a distinct crepitus could be felt. From the above symptoms, I was fully satisfied that it was a case of fracture of the neck of the os humeri. On the 28th instant, I requested my friend Mr. Hilton to see him with me; when he made a minute examination, and came to the same conclusion as myself. The following treatment was agreed on:—A small pad was placed in the axilla, and the arm somewhat kept from the side by a bolster-pad placed between the middle part of the

humerus and the side of the chest, acting as a fulcrum; then the arm was confined to the side, by a roller passed round the body and limb, and the fore-arm slightly supported by a sling, which was continued only for two or three weeks. During the whole time of treatment he was confined to his bed. At the expiration of two months the bandages were removed. Being a man of feeble power, he then was directed to use the arm as much as possible, and employ friction. Ultimately he recovered a tolerable use of the limb, so as to raise it to his head, and feed himself, to move it backwards and forwards, and to tie his drawers; although the little finger, and the next to it, continued contracted. He survived the accident two years.

*

The bone taken from this man, Mr. Blenkarne presented to the museum at Guy's Hospital.

In the treatment of these cases, the splints, the clavicular bandage, and the pad in the axilla, are required; but above all it is necessary to permit the arm to hang by the side, unsupported at the elbow, so as to let the weight of the arm be a constant source of extension upon the broken end of the bone.

Case CCLVI.—William Mills, aged seventy-two, fell down upon his shoulder during the severe frost of January, 1823, and three days after was admitted into Guy's Hospital. The arm and shoulder were much swollen; there was also acute pain and discoloration of the integuments. Crepitus could not be felt; and, from the degree of swelling, it was impossible to ascertain the precise nature of the accident. Leeches and evaporating lotions were applied. The shoulder was again examined on the second day, after the swelling had somewhat subsided, and a fracture of the neck of the humerus was discovered. The pain and swelling again became greater, and gradually increased; the integuments inflamed, having the appearance of erysipelas;

* This cut represents a fracture of this kind, united.

the skin became discoloured and gangrenous. He was feverish and irritable, then delirious, and gradually sunk on the tenth day from the accident.

Dissection.—The integuments and cellular membrane, on the inner part of the shoulder over the clavicle, were considerably thickened, having a sloughy appearance; and on cutting through the deltoid muscle, a large quantity of bloody matter, mixed with serum, was effused. The capsular ligament was extensively lacerated; the humerus was fractured through the cervix, also obliquely through the head; and a small spicula of bone was separated from the cervix.

Case CCLVII.—Mr. Morley, of Uttoxeter, has transmitted to me a case of compound fracture of the head of the os humeri; the end of the bone was sawn off, the bone reduced, and the patient did well: the length of the limb differed but little from that of the other. Such cases are not uncommon in military surgery.

The following case of fracture of the greater tubercle of the humerus was communicated to the Editor by Mr. Herbert Mayo.

Case CCLVIII.—A gentleman, aged sixty, in going up a flight of stairs fell, and in the attempt to recover himself, fell again. When he was lifted up the left arm was useless, and the shoulder in pain. On examining it within an hour after the accident, my first impression was that it was a dislocation of the shoulder. The acromion projected, as in dislocation of the shoulder, and the deltoid was flat below it. However, the elbow did not project from the side; and though motion of the shoulder was painful, yet it could be moved more easily than is usually the case in dislocation. The neck of the humerus was certainly not broken. When the arm was raised to a right angle with the scapula, and pulled outwards from the elbow, the head of the bone seemed to be restored to its place. On lowering the elbow again, the appearance of the shoulder was the same as at first. On carefully examining the outside of the head of the humerus, I found the injury to consist in fracture and separation of the greater tubercle. A figure-of-8-bandage was applied to fix the scapula and steady the shoulder, and a sling to support the arm; with a lath splint on the outside of the humerus, the upper part of which was made to bear

upon the separated bone by uniting the top of a circular roller to the figure-of-8-bandage; the fore-arm was supported in a sling.

The fracture, says Mr. Mayo, united favourably; but for a long time the patient had some difficulty in carrying the arm backwards.

CHAPTER XIII.

ON DISLOCATIONS OF THE ELBOW-JOINT.

SECTION I.—ANATOMY OF THE JOINT.

THREE bones enter into the formation of this joint; namely, the lower extremity of the humerus, the upper part of the ulna, and the head of the radius.

The extremity of the os humeri is expanded, and presents two lateral eminences, which are called its condyles, the internal of which is the most prominent; and between these condyles the articular surfaces for the ulna and radius are situated. That for the ulna is in the form of a pulley, and above it, both anteriorly and posteriorly, is situated a deep cavity with a very thin partition of bone intervening. The articular surface on which the head of the radius is received is situated on the inferior extremity of the external condyle.

The upper extremity of the ulna forms two processes, with an articular surface between them (the sigmoid notch), which is adapted to the pulley-like articular surface of the os humeri.

The superior and posterior process of the ulna is called the olecranon, which forms the point of the elbow, and into which the triceps muscle is inserted; the anterior and smaller process is called the coronoid, and gives insertion to the brachialis internus. When the arm is extended, the point of the olecranon is received into the posterior cavity, between the condyles of the humerus; and when it is bent, the coronoid process is received into the anterior hollow; so that these cavities are formed for the purpose of admitting of free extension and flexion of the arm.

The head of the radius is rounded, and rests upon the broad articular surface of the humerus, upon which it moves, both in the motions of the elbow, and in its own rotation. On its inner side it is received into the lesser sigmoid notch, an articular cavity on the radial side of the coronoid process of the ulna, upon which the radius rolls. Immediately below its head the radius becomes smaller, and this part is called its neck; at

the distance of an inch below its head is seated a process which is called its tubercle, into which the tendon of the biceps is inserted.

The ligaments which bind these bones together are the coronary, lateral, capsular, and oblique.

The coronary ligament surrounds the head of the radius; it is connected above with the capsular ligament, while below it winds around the neck of the radius, without adhering to it, so as to allow of rotation of the head of the bone; it is also attached to the anterior and posterior edges of the lesser sigmoid cavity, and thus firmly unites the radius with the ulna, yet allows of the rotation of the former.

The internal lateral ligament arises by a point from the internal condyle of the os humeri, and expands to be inserted into the whole inner edge of the sigmoid cavity of the ulna.

The external lateral ligament arises from the external condyle of the humerus, and is inserted into the coronary ligament of the radius.

The capsular ligament consists of two thin sheets of ligamentous fibres which are situated in front of the joint, both anteriorly and posteriorly, between the lateral ligaments. Both of these portions are very thin and loose: they arise from the humerus above the cavities, and are inserted in the olecranon posteriorly, and into the coronoid process, and coronary ligament of the radius anteriorly.

The oblique ligament passes downwards and outwards from the coronoid process of the ulna to the radius, just below its tubercle; and it is this ligament which limits the rotation of the radius.

A ligament also reaches from the inner side of the coronoid process to the olecranon; and when this latter process is broken off, it is this ligament, in some instances, which prevents its extensive separation.

The muscles connected with the joint are, first, the brachialis internus, which passes over the anterior part of the condyles and capsular ligament to which it is attached; it is inserted in an oblique direction into the coronoid process, and into the body of the ulna just below it. The use of this muscle is to bend the fore-arm, and give support to the elbow-joint, by strengthening the capsular ligament. The next muscle is the triceps, which

arises by one of its heads from the inferior costa of the scapula, and by its two others from the os humeri; it descends to the capsular ligament, to the loose portion of which it adheres, and is inserted into the point of the olecranon. Thirdly, the anconeus, which arises from the back part of the external condyle of the humerus, adheres to the capsular ligament, and is inserted for the extent of an inch and a half into the body of the ulna, directly below the olecranon; the course of this muscle is obliquely downwards and inwards. The two last-named muscles extend the arm and support the capsular ligament, preventing it from being pinched in between the olecranon and humerus, when the elbow is straightened. The biceps muscle is not connected with the capsular ligament, as the other muscles are; but arising from the glenoid cavity and coracoid process of the scapula, it forms a tendon at the elbow-joint, which is fixed into the tubercle of the radius. This muscle bends the fore-arm, rotates the radius outwards, that is, supinates the hand, and compresses the capsular ligament opposite the head of the radius.

Varieties of Dislocation of the Elbow-joint.—There are five species of dislocation of this joint:—

First. Both bones may be dislocated backwards.

Secondly. Both may be dislocated laterally.

Thirdly. The ulna may be dislocated backwards separately from the radius.

Fourthly. The radius alone may be dislocated forwards: and

Fifthly. The radius may be dislocated backwards.*

* The dislocations of the radius alone, forwards and backwards, should not, in my opinion, be considered as dislocations of the *elbow-joint*, but of the *superior radio-ulnar articulation*; and for this distinction many reasons, both physiological and practical, may be assigned. Physiologically speaking, the radius has very little to do with the motions of the elbow-joint, properly so called; that is to say, with the motions of the fore-arm on the humerus; whilst the humerus has no share whatever in the functions of the superior radio-ulnar articulation; that is to say, in the pronation and supination of the fore-arm. And, as a question of practice, it must be recollected, that it is through the inordinate performance of these latter motions that these two dislocations occur; the radius being thrown backwards by excessive pronation, and forwards by excessive supination; and the reduction being aided by reversing the motion that caused the displacement. Moreover, under either of these accidents, the motions of the elbow-joint are but slightly interfered with, although those of the radio-ulnar articulation are entirely lost, and the possibility of pronation and supination consequently precluded.—*Ed.*

SECTION II.

DISLOCATION OF BOTH BONES BACKWARDS.

SYMPTOMS.—This dislocation is strongly marked by the great change which is produced in the form of the joint, and by its partial loss of motion. The shape of the elbow is altered, as there is considerable projection posteriorly, formed by the ulna and radius.* On each side of the olecranon appears a hollow. A considerable hard swelling is felt at the fore part of the joint, immediately behind the tendon of the biceps muscle, formed by

the lower extremity of the humerus; the hand and fore-arm are supine, and cannot be rendered entirely prone. The flexion of the joint is also in a great degree lost.

DISSECTION.—I have had an opportunity of dissecting a compound dislocation of this joint, in which both the radius and ulna were thrown backwards, and the parts are preserved in the museum at St. Thomas's Hospital. The coronoid process of the

ulna was thrown into the posterior fossa of the os humeri, and the olecranon projected at the back part of the elbow, an inch and a

* "The olecranon," says Boyer, "is in this dislocation placed higher than the external condyle, instead of being on a level with it, as it naturally is."

half above its usual situation; the radius was placed behind the external condyle of the os humeri, and the humerus was thrown forwards on the anterior part of the fore-arm, where it formed a large projection. The capsular ligament was torn through, anteriorly, to a great extent. The coronary ligament remained entire. The biceps muscle was slightly put upon the stretch, by the radius receding; but the brachialis internus was excessively stretched by the altered position of the coronoid process of the ulna.

In another case which was dissected, neither the muscles about the joint, nor the coronary ligament were torn; but the anterior portion of the capsular ligament was extensively lacerated.

CAUSES.—This accident usually happens in a fall when a person puts out his hand to save himself, the arm not being perfectly extended, so that the bones are forced back behind the axis of the os humeri, by the pressure of the whole weight of the body upon them.

TREATMENT.—This dislocation is easily reduced by the following means. The patient is made to sit down upon a chair, and the surgeon, placing his knee on the inner side of the elbow-joint, in the bend of the arm, takes hold of the patient's wrist, and bends the arm. At the same time he presses on the radius and ulna with his knee, so as to separate them from the os humeri, and thus the coronoid process is thrown from the posterior fossa of the humerus; and whilst this pressure is supported by the knee, the arm is to be forcibly but slowly bent, and the reduction is soon effected. It may be also accomplished by placing the arm around the post of a bed, and by forcibly bending it while it is thus confined. I have also reduced the limb by making the patient, whilst sitting on an elbow-chair, put his arm through the opening in its back, and then, having bent the arm, the body and limb being thus well fixed, the reduction was easily effected.

This dislocation is sometimes undiscovered at first, in consequence of the great tumefaction which immediately succeeds the injury; but this circumstance does not prevent the reduction, even at the period of several weeks after the accident; for I have known it then effected by bending the limb over the knee, even without the application of very great force.*

As soon as the reduction has been accomplished, the arm should be bandaged in the bent position; evaporating lotions should be

* In October, 1830, I saw Sir Astley reduce this dislocation three months after the accident.—*Ed.*

applied, and the limb be supported in a sling; the fore-arm should be bent at rather less than a right angle with the upper arm. A splint may be placed in the sling, for the better support of the limb.

The following case was drawn up by Mr. Stedman.

Case CCLIX.—James Whitcombe, a small delicate child, eight years old, was admitted into Guy's Hospital, under Mr. Cooper, with an injury to his arm occasioned by a fall on his hand.

On examination the arm was found fixed at an obtuse angle; and the fore-arm was in a position between supination and pronation. On the anterior and inner part of the arm, immediately above the elbow, was a rounded projection, formed by the condyles of the humerus, and the distance between the bend of the elbow and the wrist appeared to be shortened.

On the outer side of the elbow was a sharp projection extending backwards, and formed by the olecranon and head of the radius, above which there appeared a hollow. The patient complained much of pain in the fingers, particularly in the ring and little finger, from pressure on the ulnar nerve.

Reduction was effected by placing the knee in the bend of the elbow, so as chiefly to exert pressure on the condyles of the humerus, and extending the fore-arm in a direct line, till the muscles were fatigued, and the coronoid process separated from the condyles. Then, by bending the elbow, the reduction was easily completed, the action of the biceps mainly contributing to its accomplishment.

The arm was put in a sling, with the elbow bent, and pasteboard splints were applied.

I saw him about three weeks after the accident, and he had good and perfect use of his arm.

The following case of compound dislocation, I give in the words of Mr. Samuel White, who was dresser at the time, and whose care of the case I often witnessed with the greatest pleasure.

Case CCLX.—William Dowson, thirteen years of age, was admitted into the accident ward of Guy's Hospital on the evening of the 5th of November, 1822, with compound dislocation of the elbow-joint, occasioned by the overturning of a cart in which he was riding, and which fell with great violence upon the elbow of the left arm.

The appearances were as follow:—The condyles of the humerus were thrown inwards through the skin; the articulating surface

receiving the sigmoid cavity of the ulna being completely exposed to view; the ulna was dislocated backwards, and the radius outwards; the lateral and capsular ligaments were torn asunder, with extensive laceration of the parts about the joint, but the artery and nerve remained perfectly free from injury.

By the kind assistance of Mr. Key, the reduction was easily effected in the following manner:—The humerus being firmly grasped above its condyles, making that part a fixed point, we gradually extended the fore-arm at right angles, and the parts returned to their relative situation; but upon slightly moving the fore-arm, they became displaced as before. Then the reduction was effected a second time as above described, and in the semi-flexed position the arm was dressed with adhesive plaster, and a splint of pasteboard softened in warm water was put on. A roller was then applied, and a sling was attached to the wrist and conveyed round the neck, by which means the patient was prevented from moving the arm. He was then made to lie down with the elbow resting on a pillow; and an evaporating lotion was employed, to keep the parts constantly moist and cool. I saw him during the night, and found that he was generally composed, and had slept.

Early the next morning he was free from pain, his pulse 112; he experienced much thirst during the day, without any other unpleasant symptoms, except some tension of the parts, by no means considerable.

On the following morning, there being some symptoms of inflammation, accompanied with pain in the head, I drew from the right arm ten ounces of blood, which appeared to relieve him; in the evening of the same day he was restless, and complained of great thirst; small quantities of barley water were given to him, and in the evening three grains of calomel. He slept during the night, and on the following morning the pulse had risen to 120; febrile action appearing, a draught containing liquor ammoniæ acetatis was given to him every three or four hours, and in the evening his pulse had fallen to 109; he complained of darting pains in the shoulder, and his bowels being constipated, I gave him a dose of castor oil, and two hours afterwards he had a copious evacuation, from which he felt easier and much relieved, and he passed a good night.

On the following day I found him free from pain, and much better.

The next day (Sunday) he complained of slight pains in the upper arm, accompanied with a small discharge of the wound. On Monday he was better; pulse 105. On Tuesday the discharge had increased, but on the three following days it decreased, and then I ventured to dress the wound. I found the granulations extremely healthy; and the parts appeared to be well adjusted, leaving only a small sinus, by which the discharge escaped. It was again dressed as at first, with the exception of the splint: the lotion was discontinued, the parts being perfectly cool, and the tension much reduced. The bowels being confined, the castor oil was repeated, which procured him two stools. On the following day he complained of pains in the shoulder; the discharge was again increasing; but on the four following days he proceeded well, the pulse varying from 98 to 109. On the sixth day from the first dressing I proceeded to repeat that operation; the granulations were rather prominent, but healthy; and the wound was dressed with straps of soap cerate. During the six following days the patient continued to get better; but on the seventh day from the second dressing of the wound some inflammation appeared, and the lotion was renewed; the discharge at this time was very slight. On examining the part, an abscess had formed upon the external condyle, which I relieved in a day or two after by the lancet: the quantity of matter discharged was about two ounces, but quite healthy. The next day he was much better; and from this time he continued improving until the 24th of December, when he left his bed, and walked about the ward. By great attention to the use of passive motion, he is now enabled to move the joint to a considerable extent.

Case CCLXI.—Stephen Palmer, æt. fifty-four, was admitted into Guy's Hospital, in 1838, under Mr. Key, in consequence of a dislocation of both bones backwards at the elbow, caused by a fall from a cart; together with a wound in front of the arm near the inner condyle. The dislocation was reduced by bending the elbow over the knee. A poultice and twenty leeches were applied, and the arm was placed on a pillow. Inflammation supervened, and four days afterwards the integuments from the shoulder to the wrist were gangrenous, and the patient died the same evening.

In the following case, which was under the Editor's care in Guy's Hospital, the dislocation of both bones backwards was

complicated with fracture of the external condyle of the humerus.

CASE CCLXII.—J. Chandler, æt. twenty-seven, a labourer, met with an injury to his arm in slipping off the wheel of his van; the limb was, as he states, doubled under his side, but he could not exactly describe how. He walked home, and did not perceive any particular injury to his arm, till he attempted to undress himself, when from the alteration in its form, he became alarmed, and applied at Guy's Hospital for relief.

Upon his admission, the arm was found permanently semi-flexed, and fixed in a position between supination and pronation; some slight degree of rotatory motion outwards could still be produced, but not to the full extent; the tumefaction was so great as to prevent a very minute examination: but on placing the thumb on the head of the radius, it was distinctly felt to rotate, and its cup-like cavity could be distinguished above the external condyle, in its natural position with respect to the lesser sigmoid cavity of the ulna. Thirty leeches were applied, and afterwards the spirit lotion.

The next day the swelling was still very great; twenty leeches were ordered; purgative medicine was administered, and the lotion continued.

On the next day (January 14th) the swelling was very much reduced, and the nature of the injury became apparent. It appeared to be dislocation of both bones backwards, with a fracture through the external condyle. This was indicated by the elevation of the olecranon above the condyles of the humerus, and an impossibility of flexing the elbow, together with an unnatural mobility of the external condyle.

15th. The swelling being much diminished, I made an attempt at reduction, but unsuccesfully, in consequence of the great pain it occasioned. Sir A. Cooper corroborated my opinion as to the nature of the accident.

A day or two after, I succeeded in reducing the dislocation, by placing the elbow on a table, and forcibly flexing the forearm, whilst the humerus was pushed downwards and backwards.

The patient was discharged from the hospital for ill-conduct on the 30th of March; by which time he had recovered a great degree of useful motion in the joint.*

* Surgical Essays, p. 212.

The next case is one of dislocation, with fracture of the internal condyle. It occurred in the practice of Mr. James, of Exeter, who drew up the following most minute and accurate description of it for Sir A. Cooper's opinion.

Case CCLXIII.—Master R. Garratt, æt. fifteen, on the 12th of August, was thrown from his pony, with great violence, against a gate; and dislocated his left elbow.

I saw him shortly afterwards. Both bones of the fore-arm were dislocated. The ulna was thrown backwards; and the radius also, lying towards the outer condyle, completely separated from the ulna.

The ulna was easily reduced by extension over a bed-post; the radius, however, did not return to its place. I then accomplished its reduction by an extension of the hand, pressing the head of the radius forcibly downwards with my thumbs at the same time.

The symmetry of the joint was now restored, and I was able to extend the fore-arm to a right line with the upper arm, and to bend it completely; and pronation and supination were perfect.

He was kept in bed for a few days, and splints were applied, and other means used to subdue inflammation. A good deal of inflammatory action however ensued, and the joint long remained hot and painful. Leeches were applied twice, and evaporating lotions and poultices.

In about a fortnight I began very slight motions of the joint, but they were attended with much pain. I have since continued them as far as I could, and have for some time desired him to use the pulleys; he has also used a kind of douche, and frictions with camphorated oil and ung. hydrargyri.

The limb at this time, about ten weeks from the accident, is in the following state:—It cannot be extended beyond an angle of about 120 degrees. It cannot be perfectly bent. The supination and pronation *can* be accomplished through a *perfect semicircle;* but there is a little inclination of the hand inwards. I think all the motions have lately improved considerably. The parts are no longer hot, but forcible extension, flexion, or pressure give pain.

I have this day made as accurate a measurement of the join as I possibly could do, placing dots on the outer and inner cor dyle and olecranon of both arms; and the results are these:—

	SOUND ARM.		INJURED ARM.	
	Inches.	Lines.	Inches.	Lines.
Circumference of the limb measured at the bend of the elbow over the point of the olecranon.	8	1 to 2	8	4
From olecranon to inner condyle.	1	5 to 6	1	6 and a little more.
From olecranon to outer condyle.	1	7	1	7
From bend of the arm (on the inside of the elbow) to the tip of the middle finger.	15		15	

The radius is perfectly and correctly applied to the external condyle.

Between the olecranon and inner condyle there appears to be a bony projection.

From the foregoing statement I think it appears that the reduction of the ulna and radius had been completely effected on the evening of the accident, or the perfect motions of the limb could not have been accomplished; and there is no probability that the bones can have since escaped from their situation. Furthermore, the measurements stated will not, I think, justify the supposition of any existing displacement laterally or posteriorly, the only difference of any consequence being that between the olecranon and inner condyle, and that certainly does not amount to two lines;* whereas, if there were any displacement outwards, it is impossible, I conceive, that the distance between these points should not be *much* greater, the inner condyle be strongly prominent, and the radius be carried far beyond the outer condyle.

It appears to me probable, either that the swelling, which seems to be partly of a bony nature, may have been produced by inflammatory action consequent on the injury, or from that portion of the trochlea of the humerus which forms the inner ridge supporting the ulna having been broken off at the time, (though from the swelling it could not then be ascertained, and if ascertained, hardly remedied,) from which callus has been subsequently thrown out.

These details, though long, it is necessary to state, that the

* I am inclined to think this difference is caused by the swelling next stated.

present condition of the limb may be at all understood: the important question as regards the patient, is, what further can be done for his recovery? The plan I am at present pursuing, as before stated, is the use of the pulleys, and a discutient liniment. I should think, when the joint is a little less painful, the employment of the machine for permanent extension would be advisable. At the hospital, also, we have a good douche-bath, and if you thought that might also serve, he might go in and employ it. My own impression is that he will recover a very valuable limb, though somewhat imperfect.

SECTION III.

LATERAL DISLOCATION OF THE ELBOW.

Symptoms.—When the bones of the fore-arm are dislocated backwards and outwards, the coronoid process of the ulna, instead of being thrown into the posterior fossa of the os humeri, is situated on the back part of the external condyle of the humerus. The projection of the ulna backwards is, in this case, greater than in the last described dislocation, and the radius forms a protuberance behind and on the outer side of the elbow, so as to produce a hollow above it; the rotation of the head of the radius is distinctly felt by rolling the hand.

Sometimes the ulna is thrown behind the internal condyle of the os humeri, when it still projects posteriorly, as in the external dislocation; and the head of the radius is placed in the posterior fossa of the humerus, and the external condyle of the os humeri projects very much outwardly. I have never had an opportunity of dissecting this injury.

Causes.—The manner in which the lateral dislocation is produced is the same as in that directly backwards, but the direction of the fall is varied; it may also be caused by the wheel of a carriage passing over the arm whilst it is placed upon uneven ground. The reduction of each may be effected as in the former dislocation, by bending the arm over the knee, even without particularly attending to the direction of it inwards or outwards; for as

soon as the radius and ulna are separated from the os humeri by the pressure of the knee, the muscles give them the proper direction for reduction. But the bones may be more easily reduced in a recent injury in the following manner.

Case CCLXIV.—A lady consulted me respecting a fracture of the patella, which had united by a long ligament; and I told her to be careful to wear a bandage, as she was very liable to fall and to break the other patella, which I have frequently known to happen. This was at ten o'clock in the morning; at two o'clock she came to me at Guy's Hospital, having her elbow dislocated backwards, and also laterally inwards. Finding that the tendon of the biceps, and (as I knew) of the brachialis internus, were put upon the stretch, I thought I might make use of them to draw the os humeri backwards, as by the string of a pulley, and I forcibly extended the arm, when the dislocation was immediately reduced.

The plate of the dislocation backwards will explain the mode in which the reduction was effected. It will be there seen that the tendon of the brachialis internus is stretched over the condyles of the humerus, and the biceps is also stretched over that bone; so that if the fore-arm be forcibly extended, these muscles force back the condyles of the humerus into their natural situation.

SECTION IV.

DISLOCATION OF THE ULNA BACKWARDS.

Symptoms.—The ulna is sometimes thrown back upon the os humeri without being followed by the radius. The appearance of the limb is then much deformed by the contortion inwards of the fore-arm and hand. The olecranon projects, and can be felt behind the os humeri. Extension of the arm is impracticable, but by a force which will reduce the dislocation, and it cannot be bent to more than a right angle. It is an accident somewhat difficult to detect; but its distinguishing marks are the projection of the ulna, and the twist of the fore-arm inwards.

Cause.—The accident arises from a severe blow on the lower

extremity of the ulna, by which it is pushed suddenly upwards and backwards.

DISSECTION.—We have an excellent specimen of this accident

in the museum at St. Thomas's Hospital. It had existed a great length of time without reduction; the coronoid process of the ulna was thrown into the posterior fossa of the humerus; the olecranon is seen projecting behind the os humeri; the radius rests upon the external condyle, and has formed a small socket for its head, in which it was able to roll. The coronary and ob-

*

lique ligaments had been torn through, and also a small part of the interosseous ligament; the lower extremity of the internal condyle of the humerus seems to have had an oblique fracture in it; but I doubt whether it had been broken, or only altered in form, on account of the unnatural position of the ulna; if it had

* This is an opposite view of the preceding figure.

been broken, it was re-united. The triceps was thrown backwards, and the brachialis internus muscle was stretched under the extremity of the humerus.

Treatment.—This dislocation is more easily reduced than that of both bones; and the best method is to bend the arm over the knee, and to draw the fore-arm downwards; the reduction will then be easy, as not only the brachialis muscle will act in resistance, but the radius, resting against the external condyle, will push the os humeri backwards upon the ulna when the arm is bent.

The next case, of dislocation of the ulna backwards and inwards, was sent to the Editor by his friend Mr. M. Gosset.

Case CCLXV.—Feb. 20, 1827.—John Draper, aged forty, called on me with a dislocation of the ulna inwards and backwards.

He entered my room supporting the left arm, which was very much distorted, with the opposite hand, keeping it in a state of semiflexion and pronation, which he did in order to relieve the distressing sense of weight and numbness he felt from the elbow downwards. The olecranon was elongated, and obviously projecting on the inner side of the arm. Examination of the part, in whatever direction the arm was moved, gave him excessive pain, at the same time inducing a sense of faintness; this was also occasioned whenever pressure was made on either side of the projecting portion of the ulna. By extension the arm could be easily straightened and rendered supine, but it was quite impossible, previously to complete reduction, to bend the fore-arm, even to a right angle with the upper, and all attempts of the kind caused almost insupportable pain, which was apparently owing to the pressure upon the ulnar nerve. The coronoid process of the ulna could be felt resting upon the inner condyle, and the finger could be thrust into the hollow of the sigmoid cavity. The accident appeared to have been produced by a fall on the outer side of the olecranon, when the arm was bent; and it was ultimately reduced, after several unsuccessful attempts, in the following way.

Extension was made by two persons pulling in opposite directions for a few minutes. I then fixed the olecranon, pressing it outwards and downwards while the arm was suddenly flexed, and in this way it was tilted into its place. Previously to this,

various other methods had been tried, such as bending the arm round the knee, extension being first made; fixing the olecranon against the edge of a table and endeavouring at the same time to straighten the arm; but without the slightest advantage.

SECTION V.

DISLOCATION OF THE RADIUS FORWARDS.

This bone is sometimes separated from the ulna, and its head is thrown into the hollow above the external condyle of the os humeri, and upon the coronoid process of the ulna.

SYMPTOMS.—I have seen six examples of this accident; its symptoms are as follow:—The fore-arm is slightly bent, but cannot be brought to a right angle with the upper, nor can it be completely extended. When it is suddenly bent, the head of the radius strikes against the fore part of the os humeri, and produces so sudden a stop to its motion, as at once to convince the surgeon that one bone strikes against the other. The hand is placed in a prone position, but neither its pronation nor supination can be completely performed, although its pronation be nearly complete. If the thumb be carried into the fore and upper part of the elbow-joint, the head of the radius may be there felt; and if rotation of the hand be attempted, the bone will be perceived to roll; this last circumstance, and the sudden stop to the bending of the arm, are the best diagnostic marks of the injury.

In the dissection of this case, the head of the radius is found resting in the hollow above the external condyle of the os humeri; the ulna is in its natural situation. The coronary ligament of the radius, the oblique ligament, and the fore part of the capsular, as well as a portion of the interosseous ligament, are torn through: the laceration of the latter ligament allows the separa-

tion of the two bones. The biceps muscle is shortened; and those who have not seen an example of this injury will do well to consult the preparation from which the above plate is taken.

Cause.—The cause of this accident is a fall upon the hand when the arm is extended; the radius receiving the weight of the body, is forced up by the side of the ulna, and thrown over the condyle, and upon the coronoid process of the ulna.

Case CCLXVI.—The first case I saw of this accident was in a woman, who was a patient of Mr. Cline's, in Saint Thomas's Hospital, whilst I was an apprentice to him. The most varied attempts which his strong judgment could direct were made to reduce the bone, but without avail; and the woman was discharged from the hospital with the dislocation unreduced.

Case CCLXVII.—The second case was in a lad to whom I was called by Mr. Balmanno, of Bishopsgate-street; and although I made attempts, by continuing and varying the extension in every direction for an hour and a quarter, I could not succeed in effecting the reduction.

Case CCLXVIII.—The third case was that of a hair-dresser, who, having been intoxicated in the evening, came to my house on the following morning with his radius dislocated. During the time of examination the patient became faint, and at last fell upon the floor in a state of syncope; this I thought afforded me a most favourable opportunity for replacing the bone, and whilst he was still upon the floor I rested his olecranon upon my foot, so as to prevent the ulna from receding, and then extended the forearm; and under these favourable circumstances the radius returned to its natural situation.

Case CCLXIX.—The fourth case was that of a gentleman in Old Broad street, to whom I was called by Mr. Gordon, of Oxford-court, in the city; and the manner in which we succeeded in the reduction was as follows:—We placed our patient upon a sofa and bent his arm over the back of it, and then making extension from the hand without including the ulna, the os humeri being fixed by the sofa, the radius in a few minutes slipped into its place.

Case CCLXX.—The fifth case was that from which was made the preparation preserved in our collection at St. Thomas's, and of which I have given a plate: that preparation was one morning lying on my chimney-piece, when a gentleman of high charac-

ter at the bar called upon me; he said, "What have you here?" and when I mentioned the nature of the injury, "Well, that is very curious," said he, "for I have myself been the subject of this accident." He then exposed his arm, and showed me a dislocation of the radius; it had happened many years before, and he told me that numerous and most violent attempts had been made to reduce it, without success.

The observations here stated upon this subject I usually gave in my lectures, carefully explaining the difficulty in restoring the bone to its situation. Once, on an occasion of this kind, Mr. Williams, one of the most intelligent of my pupils, said to me, "I have known the radius reduced in these accidents by extending from the hand only." From a consideration of what he said, and from an experiment on the dead body, placing the radius in the situation in which it is thrown by this accident, I was convinced that the mode of extension mentioned by Mr. Williams was the best; as, from the connexion of the hand with the radius, that bone alone is acted upon; and the ulna being excluded from the force applied, the radius sustains the whole extension. It is also right in making the extension to render the hand supine, as this position draws the head of the radius from the upper part of the coronoid process of the ulna, upon which it would otherwise be directed; and then to draw the fore-arm, by pulling the hand, and by fixing the os humeri.

Case CCLXXI.—Mr. Tyrrel informed me that a sailor, about thirty years of age, came to Saint Thomas's Hospital, as an out-patient, with a dislocation of the radius forwards, which had happened between six and seven months before. The head of the radius could be distinctly felt upon the anterior part of the humerus, especially when the arm was bent as much as the nature of the accident would allow, and when the hand was bent as much as it could be towards the fore-arm. The position of the limb was half supine; and when the humerus was fixed, the hand could be rendered neither perfectly supine nor prone. On the attempt to flex the fore-arm, a sudden check to its motion was produced by the head of the radius striking against the humerus. From constant use of the arm after the accident, considerable motion had been re-acquired, for he could, although with great difficulty, touch the lips with his hand, yet the man was anxious that an attempt should be made to reduce it. From this, however, he

was dissuaded; and he went to Guy's Hospital, where the same advice was given to him.

CASE CCLXXII.—Mr. Adams, of Dublin, in one of the articles on Dislocation, which he has contributed to Dr. Todd's valuable Cyclopædia of Anatomy, gives the case of a young gentleman, whose left radius became gradually dislocated, by the action of the flexor muscles, upon the external condyle, where a new socket was formed for it; from which new socket, however, it was occasionally dislocated in a direction farther outwards. This displacement was the consequence of a violent blow, which had rendered the limb weak and wasted.

The next case was sent to Sir A. Cooper, in 1826, by Dr. Rumsey, of Beaconsfield. The Editor will not deny the gratification with which he regards the well merited eulogy in the last paragraph of Dr. Rumsey's letter.

CASE CCLXXIII.—"A boy, about seven years old, was running down a hill, and fell, pitching on his hand; which a companion said was, with the arm, bent under him. I saw him in four hours. The deformity of the elbow was great to the eye; the radius was drawn up, and lay on the external condyle of the os humeri. The next striking circumstance was a great tenderness at the distance of one third down the arm upon the ulna, and here was also some tumor. The tenderness was so remarkable, that at first I thought this part was the seat of a fracture. Yet this was not the case. I believe that every other circumstance corresponded exactly with the symptoms given in your valuable work on dislocations and fractures of the joints, which I referred to on my return home. The reduction was effected by taking the hand, as in shaking hands, and extending it, while the humerus was held firmly by an attendant. Finding a minute or thereabouts elapse without any change, I added some force in the same direction, by applying the thumb of my disengaged hand to the head of the radius, and pushing downwards. Within two minutes the bone was in its place.

"Upon comparing this case with your description and plate, I am inclined to believe the great tenderness to have been connected with the lacerated part of the interosseous ligament; and, as such laceration happens of necessity, I think it probable that the said tenderness may generally occur, and add one diagnostic symptom to the already clear and strong ones pointed out in your book.

"Two days after the accident a slight eruption appeared on that part of the arm which had been so tender, as if the skin had been stretched, or otherwise injured from within. The tenderness remained some days. Leeches, however, were applied about the joint, and the case did well.

"I cannot conclude this letter, Sir Astley, without expressing the obligation which your invaluable book on dislocations has conferred on me, as a member of the profession. While it promises a security to the sufferer from accident, that his injury shall be understood, it equally promises peace to the mind of the surgeon, and credit to the art."

The next case, in which a dislocation forwards of the radius was accompanied with a fracture through the sigmoid cavity of the ulna, so that the latter bone, with half of its sigmoid cavity, was also thrown forwards, is worthy of attention.*

Case CCLXXIV.—A man was brought into the Hôpital St. Louis, with an injury to the elbow-joint, and with other injuries, of which he died in three hours.

On examination of the elbow, a hard oblong tumor was found, a finger's breadth above the condyles of the humerus, elevating the biceps and brachialis internus muscles, and rendering the artery comparatively superficial. The radial side of this tumor rolled under the finger during supination and extension. The olecranon was prominent, and movable transversely, but maintained its natural position. A wound was found two fingers' breadth below the olecranon, through which the bone protruded. The condyles of the humerus preserved their natural relations with the posterior part of the ulna, but projected considerably, so as to stretch the skin.

On examination after death, it was found that the ulna was divided by an oblique longitudinal fracture, which ran from above downwards, and from before backwards; extending from the middle of the sigmoid cavity to the external border of the ulna, and thence backwards and inwards to a finger's breadth below the olecranon. The triceps, the extensor carpi ulnaris, and the anconeus muscles were attached to the upper fragment.

The ulna was thus divided into two fragments; one formed by its body, surmounted by the coronoid process; the other by the

* It is recorded in the Archives Générales de Médecine for Dec. 1839, and quoted in Forbes's Review, vol. ix.

olecranon, with an inch and a half of the ulna below ending in a point. The former portion protruded forwards with the radius. The capsular ligament was torn throughout.

The two ensuing cases, the first of which was complicated with fracture of the internal condyle, and the other with fracture of the upper extremity of the radius, were treated by the Editor in Guy's Hospital.

Case CCLXXV.—James Brown, æt. forty, a stout muscular blacksmith, was admitted in May, 1833, having an hour before fallen down a flight of brick steps, and pitched on his right elbow. On examination, the limb was found flexed, and could only be extended with considerable difficulty, whilst the hand was fixed in a state of moderate supination. On tracing the line of the radius in front of the arm, instead of its leading the eye to the external condyle of the humerus, it led to a prominence in the middle of the front of the elbow-joint, and in the situation of the coronoid process of the ulna.

On viewing the posterior region of the elbow-joint, the olecranon was found in its relative position with respect to the outer condyle; whilst on the inner side a projection was seen, which upon minute inspection, was found to be a portion of the internal condyle of the humerus, separated from the shaft of the bone, and drawn up by the biceps muscle.

The case was therefore shown to be dislocation of the radius forwards, with fracture of the internal condyle of the humerus.

An attempt was then made to return the head of the radius into its natural situation, which was at last accomplished, by forcibly pronating the hand, the elbow being semiflexed, whilst an assistant pressed the head of the radius backwards and outwards into the lesser sigmoid cavity of the ulna. The internal condyle was then brought into its proper situation, and the displaced bones retained there, by means of a screw splint, with a compress applied immediately over the head of the radius.

Considerable swelling occurred after the reduction, requiring the application of leeches and cold lotions to subdue it; and then a large pasteboard splint was applied wet upon the fore and back part of the arm, with a roller firmly bound over it. In a month the splints were removed, passive motion employed, and the patient recovered the perfect use of the elbow-joint.

Case CCLXXVI.—Mary Powell, æt. fifty-six, was admitted

into Guy's Hospital, in October, 1828, in consequence of an injury which she had sustained from falling down stairs on her elbow.

On examination, the fore-arm presented considerable distortion; a distinct depression was seen immediately below the external condyle, and a hard tumor was obvious in front of the ulna, and opposite to its coronoid process. Upon rotating the hand, there was no motion of the tumor to be perceived; from which circumstance some doubt arose as to whether or not the projection was formed by the head of the radius; but upon more minute examination, a fracture of the radius was also discovered about an inch and a half below its head, which accounted for the whole of the radius not obeying the same motion.

By the application of very slight force immediately upon the dislocated head of the radius, it was readily pushed back into its place, thus portraying the perfect laceration of the coronary ligament. The arm was then kept in a state between supination and pronation, and splints were applied in the usual manner for fractures of the fore-arm, excepting that a compress was particularly placed upon the head of the radius to retain it in its natural position, which proved not difficult to be accomplished. At the end of the month the splints were removed, passive motion commenced, and the patient left the hospital in six weeks.

The Editor has received also a note of two cases of this accident from Mr. M. Gosset. Both of them were reduced; and one of them, which did not come under treatment till three weeks after the accident, was reduced in the following way. Extension being made by two assistants in opposite directions, Mr. Gosset grasped the lower part of the fore-arm firmly with his left hand, so as to fix the head of the radius; and then taking hold of the wrist with his right hand, he suddenly and forcibly bent the fore-arm upon the upper; and in this way, making the thumb of his left hand act as a fulcrum, he pressed the head of the bone back into its place.

SECTION VI.

DISLOCATION OF THE RADIUS BACKWARDS.

This is an accident which I have never seen in the living person; but in the winter of 1821, a man was brought for dissection into the theatre of St. Thomas's Hospital, in whom was found this dislocation, which had never been reduced. The head of the radius was thrown behind the external condyle of the os humeri, and rather to the outer side of the lower extremity of that bone. Mr. Sylvester, of Gloucester, who was at that time a very intelligent student, had the kindness to make me a drawing of the parts as they were dissected, and the appearances are seen in the accompanying figure. When the arm was extended, the head of the radius could be seen, as well as felt, behind the external condyle of the os humeri. On dissecting the ligaments, the coronary ligament was found to be torn through at its fore part, and the oblique had given way. The capsular ligament was partially torn, and the head of the radius would have receded much more, had it not been supported by the fascia which extends over the muscles of the fore-arm.

Of the causes of this accident I know nothing, never having seen it in the living subject.

As to its reduction, it will be easily effected by bending the arm; but to secure the bone from subsequent displacement, the arm must be kept steadily bent at a right angle, and secured by splints and a circular bandage in that situation, until the union

of the coronary ligament has been effected, which will require the lapse of three or four weeks from the accident.

For the following brief note of a case of this accident I am obliged to my friend and old pupil, Mr. May, of Reading.

CASE CCLXXVII.—The patient's arm was straight, and could not be flexed; it was reduced without much difficulty by extending the radius, an assistant at the same time pressing his thumb firmly against its head and making counter-extension on the upper arm.

Professor Langenbeck, of Göttingen, has published two cases of this accident, with the following remarks.*

CASES CCLXXVIII and CCLXXIX.—"Dislocation of the radius backwards must be an extremely rare occurrence, since Sir Astley Cooper never met with this accident in the living, and only once in the dead subject. With the exception of the two cases which I am about to relate, I never met, during the whole course of my professional career, with a dislocation of the radius in any direction. Last winter, however, two persons were brought into the hospital with luxation of the radius; in one case, the man was twenty years old, and the accident of six weeks' standing; in the other, the injury occurred in a child five years of age, the day before its admission into the house. In both the symptoms were so distinctly marked, that on the first inspection of the part, I recognized the nature of the injury before me. On an examination of the joints, the head of the radius was found thrown a little backwards and outwards from the external condyle of the humerus, and could not be immediately detected. The peculiar form of the radial side of the fore-arm, without displacement of the ulna, chiefly indicated the nature of the mischief. At the origin of the supinator radii longus, and of the extensor muscles from the external condyle and the upper portion of the radius, there was a marked prominence; the form was somewhat similar to what we meet with in rickety persons, in whom the radius is generally bent. The hand was prone, and could not be brought into a state of supination; the fore-arm was moderately bent, in which position it was fixed, for the arm admitted of neither flexion or extension. On the inner side of the internal condyle the skin was lax, and presented a depression in which the internal articulatory surface of the humerus could be felt. On trac-

* Quoted from the "Lancet," New Series, vol. i. p. 248.

ing the radius from below upwards, the finger came against the external condyle, behind which, in the adult, the articular circumference only of the head of the radius could be felt, and next to it the olecranon. On placing the fingers on the radius in this spot, and moving the bone as far as it admitted, the motion was also communicated to the finger. Behind and below the external condyle in the child the glenoid cavity of the head of the radius could be felt.

"Although the first dislocation was of old standing, attempts at reduction were made. The principal measure to be adopted, appeared to me a powerful but gradual extension of the fore-arm, in order, by this plan, to draw the head of the radius towards the articulating surface of the humerus; at the same time making counter-extension of the upper arm, I passed the dislocated head inwards. As in this case very strong and long-continued extension was absolutely necessary, I could now completely stretch out the fore-arm, which before was not practicable, and thus push the head of the radius inwards. The limb was kept in this situation by splints and bandages, and the patient was soon able to move the fore-arm in the four directions, to a very considerable extent, and then left the hospital. In the child moderate extension only, with pressure, was quite sufficient to reduce the dislocation.

"Dislocation of the radius in any direction so seldom occurs, that it may be interesting for a moment to inquire into the nature of the force necessary for the production of this accident, and the anatomical effects which result from the injury. The head of the radius is so completely covered with muscle and concealed on its outer and fore-part, that the chance of displacement from force applied in these directions is considerably diminished. The only situation then, where the application of force is likely to effect displacement of the head of the radius, is in the palm of the hand, opposite to the muscles of the thumb; but, in falling, the whole palm of the hand generally receives the shock of the fall, which will be communicated to the ulna, as well as to the radius; and the former bone being more easily dislocated is that which commonly suffers.

"When displacement of the radius occurs, the orbicular, as well as the capsular ligament, will be lacerated, and very probably some of the superior fibres of the interosseous ligament.

The latter may, perhaps, be stretched sufficiently to allow of the displacement, but the orbicular ligament will be invariably ruptured, of course assuming that the ulna remains in its situation."

The following is the only case of this dislocation which the Editor has seen.

Case CCLXXX.—John Bede, æt. twenty-five, was admitted into Guy's Hospital in January 1833, for an injury to the elbow-joint, which had happened fifteen weeks previously, from the kick of a horse. He stated that the limb was first put up by a surgeon in the bent, and afterwards in the straight position; but at the end of thirteen weeks, finding that he had not regained either the strength or motion of the arm, he applied for assistance at Guy's Hospital.

On examination, Mr. B. Cooper discovered that there had been a fracture through the coronoid process of the ulna, entirely separating the upper extremity from the shaft of that bone; the shaft had been drawn forwards by the brachialis internus, and had formed such adhesions to the fore part of the humerus as to produce a kind of supplementary articulation; whilst the upper fractured portion had been drawn backwards by the triceps. The radius was separated from the ulna, and was thrown outwards and backwards, as if influenced by the supinator radii brevis muscle. No means were employed for the reduction of the dislocation, in consequence of the length of time which had elapsed; but the patient was desired to use the limb as much as possible.

LATERAL DISLOCATION OF THE RADIUS.

Case CCLXXXI.—Mr. Freeman, surgeon, of Spring Gardens, brought to my house a gentleman of the name of Whaley, aged twenty-five years, whose pony having run away with him, when he was twelve years of age, he had struck his elbow against a tree whilst his arm was bent and advanced before his head. The olecranon was broken, and the radius dislocated upwards and outwards, above the external condyle; and when the arm is bent, the head of the radius passes the os humeri. He has an useful motion of the arm, but neither the flexion nor the extension is complete.

CHAPTER XIV.

ON FRACTURES OF THE ELBOW-JOINT.

SECTION I.—FRACTURES OF THE OS HUMERI ABOVE THE CONDYLES.

The condyles of the os humeri are sometimes obliquely broken off just about the joint, and the appearance produced is so similar to that of the dislocation of the radius and ulna backwards, that this fracture is very liable to be mistaken for that dislocation. The following case, which was drawn up by Mr. D. B. Major, one of the dressers at Guy's Hospital, will best exemplify its diagnostic marks.

Case CCLXXXII.—William Law, aged nine years, was admitted into Guy's Hospital on the 3rd of July, 1822, with a fracture of the condyles of os humeri above the elbow-joint, which he had sustained in being thrown from a cart, having fallen upon his elbow. At the time of his admission the arm was slightly bent, and the radius and ulna appeared to project considerably backwards; just above the projection there was a hollow in the back of the arm, so that the appearances much resembled those of dislocation. I extended the fore-arm, and the appearances of the dislocation ceased; but when the exten-

sion was discontinued, those appearances returned. At this time Mr. Key arrived, who explained the accident to be a fracture above the condyles. The arm was put in splints, which were continued to be worn until the 13th of July, when they were occasionally removed, and passive motion was employed.

The appearances of this accident, as will be seen, are like those of dislocation of the radius and ulna backwards; and the mode of distinguishing the two injuries is, by the removal of all the marks of dislocation on extension, and by their return so soon as the extension is discontinued; in general, also, these accidents are detected by rolling the fore-arm upon the humerus, when a crepitus may be felt just above the elbow-joint.

This fracture happens at all periods of life, but much more frequently in children than in persons of advanced age.

Treatment.—Its treatment consists in bending the arm, and drawing it forwards to effect replacement; then a roller should be applied while it is in the bent position. The best splint for it is one formed at right angles, the upper portion of which should be placed behind the upper arm, and the lower portion under the fore-arm; a splint must also be placed upon the fore

part of the upper arm, and both should be confined by straps: evaporating lotions should be used, and the arm be kept in the bent position by a sling. In a fortnight, if the patient be young, passive motion may be gently begun to prevent the occurrence of anchylosis; and in the adult, at the end of three weeks, a similar treatment is to be pursued. But even after the most

careful and judicious means which can be adopted, there is sometimes considerable loss of motion; and when the accident has not been understood, or has been carelessly treated, the deformity and loss of motion become very considerable.

The following is the case of a patient who was sent to me by Mr. Ivimy, surgeon of Portsea.

Case CCLXXXIII.—Mrs. Hewett, of Southsea, met with a severe accident on the 21st of September, by a fall from a chaise, which occasioned a compound fracture of the left arm, as follows. The external and internal condyles were fractured longitudinally; the intermediate space which receives the olecranon was quite comminuted, and three pieces of bone were extracted from the external wound soon after the accident: there was also a transverse fracture about two inches and a half above the condyles.

Evaporating lotions were applied during the two first weeks; the case proceeded favourably; and the lady, in a great degree, reacquired the flexion and extension of the arm.

Case CCLXXXIV.—W. C. Hazy, æt. eight, was admitted into Guy's Hospital on the 4th of July, 1835, with enormous swelling and deformity of the arm; he had fallen on the hand, and the fore-arm had apparently been thrust quite behind the humerus. The case was pronounced to be a fracture of the lower extremity of the humerus, and treated accordingly. But on removing the splints a month afterwards, although the projection posteriorly was quite gone; a very serious deformity still existed. Both ulna and radius were thrown inwards, so that the articular cavity of the ulna rested upon the inner condyle, and the radius seemed to be resting on the elevation between the two articular surfaces. The arm could only be bent to a right angle, and could not be extended beyond 145 degrees. The voluntary motions of the limb were almost lost, but pronation and supination could be effected by another person. There was a thickening along the lower part of the humerus, as if the bone had been broken obliquely downwards. Nothing was done for the dislocation, and when the patient left, very little power remained to the limb.

SECTION II.

FRACTURE OF THE INTERNAL CONDYLE OF THE OS HUMERI.

The internal condyle of the humerus is frequently broken obliquely from the other condyle and body of the bone; and the symptoms by which the accident is known are as follow.

First. The ulna appears dislocated; because it projects behind the humerus with the broken condyle when the arm is extended.

Secondly. The ulna resumes its natural situation on bending the arm.

Thirdly. By grasping the condyles, and bending and extending the fore-arm, a crepitus is perceived at the internal condyle.

Fourthly. When the arm is extended, the lower end of the os humeri advances upon the ulna so as to be felt upon the anterior part of the joint.

Case CCLXXXV.—I saw a girl, a patient of Mr. Steel, of Berkhampstead, who, by a fall upon her elbow, had fractured the olecranon, and also broken the internal condyle of the os humeri, the point of the broken bone having almost penetrated the skin: the cubital nerve had been also injured; for the little finger, and half the ring finger, were benumbed.

The cause of this accident is a fall upon the point of the elbow. It usually occurs in youth, before the epiphysis is completely ossified; although I have seen it, but less frequently, in old age. It is often mistaken for dislocation.

Treatment.—Its treatment consists in applying a roller around the elbow-joint to keep the bone in complete apposition; in wetting it frequently with spirits of wine and water; in bending the limb at a right angle, and supporting it in a sling; and in beginning with passive motion, in the child, at the expiration of three weeks after the accident, and at a month in the adult, to prevent the loss of motion in the joint.

SECTION III.

FRACTURE OF THE EXTERNAL CONDYLE OF THE OS HUMERI.

This accident is readily detected by the following symptoms. There is some degree of swelling upon the external condyle, and pain upon pressure; the motions of the elbow-joint, both of extension and flexion, are performed with pain; but the principal diagnostic sign is, the crepitus produced by the rotatory motion of the hand and radius. If the portion of the fractured condyle be large, it is drawn a little backwards, and carries the radius with it; but if the portion be small, this circumstance does not occur. We have two excellent preparations of this accident in the museum at St. Thomas's Hospital, and in neither case has there been any other than ligamentous union. In one prepara-

tion, in which the external condyle is split obliquely, the bone is somewhat thickened; but although this accident had obviously happened long before death, no union but that by ligament had been produced. The second preparation is a specimen of the transverse fracture of the extremity of the condyle, within the

capsular ligament, in which not the least attempt at ossific union can be detected.

It is obvious, therefore, that this principle of ligamentous union extends to all detached portions within a capsular ligament; the vitality of the bone being supported merely by the ligament within the joint.

This accident usually happens to children, from falls upon the elbow; at least, in the course of my observation, a very large proportion of the cases have been in young persons: I have seen it occur in the adult, but very rarely in advanced age.

TREATMENT.—The treatment required is the following:—A roller is applied around the elbow, and above and below the joint. An angular splint is to be adapted which should admit the elbow, extend behind the upper arm, and receive the fore-arm, so as to support it; a roller should then be bound over the whole to keep it firmly fixed. In the child, this splint may be made of stiff paste-board, bent to the shape of the elbow; but the best mode for its application is, to dip it in hot water and apply it wet, so that it may exactly adapt itself to the form of the limb; it thus becomes the best possible support to the injured arm. Indeed, it may be here observed, that for children this is the best mode of making every support of this kind. The splint is to be worn for three weeks, when passive motion is to be begun; it must be very gentle at first, and may be gradually increased as the pain and inconvenience attending it subside.

The result of the case depends upon the seat of the fracture: if the bone be broken very obliquely, a steady and long continued support of the part will occasion it to unite; for in these cases a considerable portion of the fracture is external to the capsular ligament; but if the whole extent of the fracture be within the ligament, it does not, so far as I have seen, unite by bone, whatever be the means employed.

SECTION IV.

FRACTURE OF THE CORONOID PROCESS OF THE ULNA.

A gentleman came to London for the opinion of different surgeons upon the following case.

Case CCLXXXVI.—This gentleman had fallen upon his hand whilst in the act of running, and on rising, he found his elbow incapable of being bent, nor could he entirely straighten it; he applied to his surgeon in the country, who, upon examination found that the ulna projected considerably backwards; but tha so soon as he bent the arm, it resumed its natural form. He

immediately confined the limb in a splint, and kept it in a sling. When I saw this gentleman in town, several months had elapsed since the accident, yet the same appearances, which the surgeon described when he first saw the injury, remained; namely, the ulna projected backwards whilst the arm was extended, but it was without much difficulty drawn forwards and bent, and the deformity was then removed. It was thought, at the consultation which was held about him in London, that the coronoid process was detached from the ulna, and that thus during extension, the ulna slipped back behind the inner condyle of the humerus.

I had been several years in the habit of mentioning this case at lecture, when a person was brought to the dissecting-room at St. Thomas's Hospital, who had been the subject of the same accident, and the joint is preserved in our museum. The coronoid process, which had been broken off within the joint, had united by ligament only, so as to move readily upon the ulna, and thus alter the sigmoid cavity of the ulna so much as to allow in extension that bone to glide backwards upon the condyles of the humerus.

*

* In this preparation, both the external condyle and the coronoid process are broken off, and both are united by ligament.

CASE CCLXXXVII.—"I saw a case," says Mr. Liston, "of this fracture, in which the injury arose in consequence of the patient, a boy of eight years, having hung for a long time from the top of a high wall, afraid to drop down."*

TREATMENT.—As to the treatment of this accident, I am doubtful whether any mode can completely succeed, as the coronoid process, like the head of the thigh-bone, loses its ossific nourishment, and has no other than a ligamentous support. Its life is

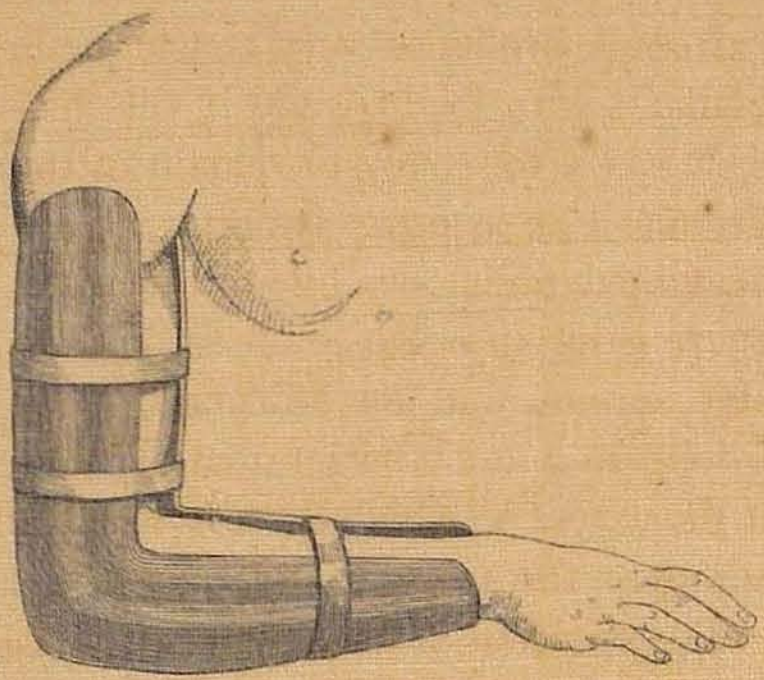

preserved by the vessels of the reflected portions of the capsular ligament upon the end of the bone, which do not appear capable of supporting the least attempt at ossific union; nor is any change on the surface of the bone apparent. It will be proper, however, in this accident, to keep the arm steadily in the bent position for three weeks after the injury, and thus to make the ligamentous union as short as possible, by leaving the bone perfectly at rest.

SECTION V.

FRACTURE OF THE OLECRANON.

SYMPTOMS.—This process of the ulna is not unfrequently broken off, and the accident is followed by symptoms which render the injury so evident, that the nature of the case can scarcely be mistaken. Pain is felt at the back of the elbow, and a soft swelling is soon produced there, through which the sur-

* Practical Surgery, 3rd Edit. p. 77.

geon's finger readily sinks into the joint; the olecranon can be felt in a detached piece, elevated sometimes half an inch, and sometimes two inches, above the portion of the ulna from which it has been broken. This elevated portion of bone moves readily from side to side, but is with great difficulty drawn downwards; if the arm be bent, the separation between the ulna and the olecranon becomes much greater. The patient has scarcely any power to extend the limb, and the attempt produces very considerable pain; but he bends it with facility, and if the limb be undisturbed, it has a tendency to remain in the semiflexed position. For several days after the injury has been sustained, much swelling of the elbow is produced; there is an appearance of ecchymosis to a considerable extent, and an effusion of fluid ensues into the joint in a much larger quantity than is natural; but the extent to which these symptoms proceed depends upon the violence which produced the accident. The rotation of the radius upon the ulna is still preserved. No crepitus is felt unless the separation of the bone be extremely slight.

The following case presented some difficulties in the diagnosis.

CASE CCLXXXVIII.—April 25, 1831, Mr. H., of Northumberland-street, was thrown from his horse, which fell with him, and his left elbow first came in contact with the ground. About an hour after the accident the Editor found it very much swelled, and especially just opposite to the centre of the olecranon, where it presented a rounded, circumscribed, soft tumor, into which the finger very readily passed, but no separation of the olecranon could be felt, and the patient could easily extend the arm. It presented one strong diagnostic mark of fractured olecranon; namely, a bulging of the triceps just above the elbow-joint: the facility of motion, however, of extension equally with flexion, induced me to believe that the bone was not fractured. Leeches and evaporating lotions were applied; and on the third day after the accident the tumefaction having entirely subsided, the separation between the fractured extremities of the olecranon could be readily felt. The peculiarity in this case was the facility of extension of the fore-arm, which was retained until all the swelling had gone down.

The olecranon on the opposite side had been fractured some years previously, by a sword wound.*

Dissection.—This fracture is usually found to have happened through the centre of the olecranon; and it is most frequently in the transverse direction; but I have seen the bone broken obliquely, so that the fractured parts presented very thin edges. On that portion of the olecranon attached to the ulna there are some marks of ossific inflammation, and some very slight traces of it on the detached portion. The cancellated structure of the fractured

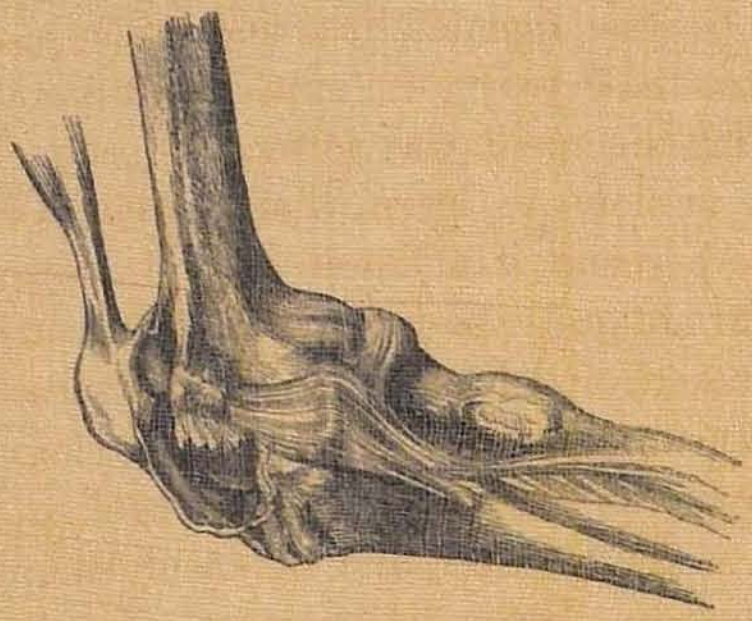

olecranon is filled by ossific matter, and is sometimes smoothed by occasional friction. The os humeri and radius undergo no change. In the appearances of one case which I dissected, and of which I have given a plate, the olecranon is separated two inches from the ulna: the capsular ligament of the elbow-joint is torn through on each side of the olecranon; and the separated portion is united by a ligamentous band, which is stretched from one broken extremity of the bone to the other.

The nature of this injury then is as follows. So soon as the extremity of the bone is broken off, it is, by the action of the triceps muscle, drawn up from half an inch to two inches from the ulna, and the extent of its separation depends upon the degree of laceration of the capsular ligament, and of that portion of the ligamentous band which proceeds from the side of the coronoid process of the ulna to that of the olecranon. That I might perfectly understand the nature of this accident, and the means of its reparation, I tried the following experiments on a dog.

* Surgical Essays, p. 109.

EXPERIMENTS.—The integuments having been drawn laterally and firmly over the end of the olecranon, I made a small incision, and placed a knife upon the middle of that process, in a transverse direction; on striking it with a mallet, the bone was readily cut through; a separation directly took place by the action of the triceps muscle; adhesive matter was effused; and when I examined the limb a month afterwards, I found the bone united by a strong ligament. I broke the olecranon in the same manner in several rabbits; blood was in these experiments first thrown out, and then adhesive matter filled up the space of separation, which subsequently became ligamentous, and firmer and firmer, as the time was protracted between the experiment and the examination. As I found that ligament was formed in each of these experiments, I was anxious to learn whether the olecranon could be made to unite by bone, if a longitudinal fracture were produced with but slight obliquity, so that the broken portions might still remain in contact; and I found that under these circumstances, the osseous union readily took place. Therefore, this bone, like the extremity of the osiscalc when it is broken off, is detached by the action of the muscles, and ligamentous union ensues from want of adaptation. But a different cause for the failure of bony union exists in the fracture of bones within joints; as, for example, in the neck of the thigh-bone, in the coronoid process of the ulna, and in the extremity of the external condyle of the os humeri. In these injuries the want of union proceeds from the diminished nutrition of the fractured parts, the little that exists being derived through the medium of blood-vessels intended for the nourishment of ligament. The preparations made from these experiments may be seen in the museum at St. Thomas's Hospital. I have also seen this process in the living person united by bone, when the fracture has happened very near to the shaft of the ulna.

The ligamentous substance, which generally forms the bond of union in these cases, is often incomplete; having an aperture, and sometimes several apertures in it, when it is of considerable length. The arm is weakened in proportion to the length of the ligament, for if this be very long, extension of the arm is rendered difficult from the necessarily diminished power of the triceps muscle.

Causes.—The causes of this injury are, first, a fall upon the elbow when the joint is bent; and secondly, fracture by the action of the triceps muscle only, when a great and sudden exertion is made during the flexed position of the arm.

Treatment.—The treatment of this accident must be modified according to the degree of injury. If there be much swelling and contusion, it is right to apply evaporating lotions and leeches for two or three days; and after the inflammation is reduced, a bandage should be applied; but in those cases where but little violence is done to the limb, it should be at once secured by bandage. The principles of the treatment are, first, to preserve the power of the limb, by making the separation of the bones as slight as possible, that their ligamentous union may be shortened; and secondly, to restore the natural motions of the joint. If the swelling and inflammation do not prevent it, the surgeon is to place the arm in a straight position, and to press down the upper portion of the fractured olecranon until he brings it in contact with the ulna; a piece of linen is then laid longitudinally on each side of the joint, a wetted roller is applied above the elbow, and another below it; the extremities of the linen are then to be doubled down over the rollers, and tightly tied, so as to cause an approximation; thus the portions of bone are brought and held together; a splint well padded is to be applied upon the fore part of the arm, to preserve it in a straight position, and is to be confined to it by a circular bandage; lastly, the whole is to be frequently wetted with spirits of wine and water.

This is the only injury of the elbow-joint which requires the straight position; those of the condyles and coronoid process demanding that the limb should be kept bent.

In a month the splint is to be removed, and passive motion is to be begun; but if it be attempted earlier, the olecranon will separate from the shaft of the bone, and the ligament become

lengthened and weakened; all attempts at motion must therefore be made with the greatest gentleness.*

Fracture of the olecranon an inch from the point of the elbow into the body of the ulna, requires the same treatment as the common fracture of this portion of the bone.

CASE CCLXXXIX.—Miss ———, aged thirty, fell from her horse on her elbow, and broke the ulna one inch from the point of the olecranon. It was kept bent three months, and no extension could be produced by any effort of herself. I forcibly straightened the arm, and kept it so by a wooden splint. Bony union may in this case be readily produced.

The subjoined plate is intended to show the bands of ligamentous fibres, which, if they remain untorn, prevent the olecranon from separating far from the ulna. In general, however, by bending the arm, there is sufficient separation for the fracture of the olecranon to be easily discovered.

One band of ligamentous fibres crosses from the side of the coronoid process to the olecranon; the other is upon the radial side of the ulna, and is formed by the upper portion of the coronary ligament of the radius which passes from the side of the olecranon towards the neck of the radius. If the olecranon be broken off, and these ligamentous fibres be left entire, the olecranon will remain still united to the ulna by means of

* The patient should be cautioned against using his arm too freely, till the uniting ligament has acquired strength and firmness. A patient of Mr. Mayo's, whose olecranon had been fractured, and had united in six weeks by a ligament of the ordinary firmness, suffered severely from neglecting this precaution; for after using the arm as much as possible for some time, he found that it became weaker and weaker; the uniting ligament was entirely absorbed, so that the fractured olecranon was drawn up by the triceps, the power of extending the elbow was almost lost, and the limb became wasted and useless.—*Ed.*

these ligaments, which I should not have noticed, but for their influence on fractures of this bone.

Compound Fracture of the Olecranon. — In compound fractures of this bone, the edges of the skin must be brought into exact apposition; lint dipped in blood must be applied on the wound, with adhesive plaster over it, and union by adhesion must be effected if possible; but in other respects the treatment is the same as in simple fracture.

I have seen two cases of this accident, both of which have been successfully treated.

Case CCXC. — The Editor had a case in Guy's Hospital in which fracture of the olecranon was complicated with fracture of the internal condyle. The condyle was drawn upwards and backwards giving in some degree the appearance of dislocation of the ulna; but the facility of producing crepitus readily explained the nature of the accident. The olecranon was drawn up to a considerable distance.

The violent inflammation and swelling which followed, prevented the application of splints for a week; during which time the arm was kept on a pillow in the semiflexed position. It then became a question, in what position the arm should be placed; since the semiflexed position is usually recommended for fracture of the condyle, whilst a perfectly straight one is necessary in fractures of the olecranon. But inasmuch as the internal condyle is under the influence of the triceps as well as the olecranon, it seemed to the Editor that the straight position would serve equally for both portions of bone, and it was adopted accordingly. At the end of three weeks the splints were removed, passive motion gradually employed, and at the end of six weeks the power of bending the limb was complete, although the patient could hardly straighten it in the natural degree.

SECTION VI.

FRACTURE OF THE NECK OF THE RADIUS.

This fracture I have heard mentioned by surgeons as being of frequent occurrence, but there must be some mistake in the statement, for it is an accident which I have never seen; and if

instances ever present themselves (which I do not mean to deny), they must be very rare.

The injury would be known by fixing the external condyle of the humerus and rolling the radius, when a crepitus would be perceived.

If such an accident should occur, the treatment which it will require will be the same as that which is demanded for fracture of the external condyle of the os humeri.

SECTION VII.

COMPOUND FRACTURES OF THE ELBOW-JOINT.

These generally happen through the internal condyles of the os humeri, and the fracture takes an oblique direction into the joint. In the most severe accident of this kind, the constitution is generally able to support the injury, if it be judiciously treated; and the recital of the following cases will evince the happy result that may be epxected, if union by adhesion be effected in the treatment.

Case CCXCI. — I was called to Guy's Hospital to see a brewer's servant who had a compound fracture of the elbow-joint, caused by his dray passing over the arm, which had considerably comminuted the bones. I could pass my finger readily into the joint, and feel the brachial artery pulsating on its fore part. Considering the violence done to the part, and the constitution of the patient, who, like most of those in such employment, drank much porter and spirits, and ate but little, I at once told him, I feared there was scarcely any hope of his recovery, unless he consented to the loss of his limb. The man, however, determined not to submit to the operation, although Dr. Hulme, who accompanied me, also endeavoured to convince him of the necessity of amputation; I therefore did all in my power to save both his life and his limb. The bones were easily replaced, and the parts were carefully brought together. The limb was laid upon a splint, lightly bandaged, and placed at right angles. The wound united without any untoward circumstances; and the only check that interrupted his recovery, was the formation of an ab-

cess in the shoulder, which was opened, and immediately healed. The elbow-joint was not even completely anchylosed, for he retained sufficient motion in it to allow him to resume his former occupation.

Case CCXCII.—A gentleman, of the name of Stewart, was thrown from his chaise, and had a fracture of the condyles of the os humeri, with a projection of a portion of its inner condyle through the integuments. The edges of the wound were immediately brought together; and lint, dipped in blood, was laid over them; evaporating lotions were then applied, and the limb was kept in the bent position until the fracture was united. He had some use of the joint afterwards, but its motions were much more limited than in the former case.

Case CCXCIII.—Mr. L., aged seventy-four, who is nearly my opposite neighbour in New-street, Spring-gardens, fell down some steps on the 20th of April, 1818, and shattered his elbow-joint. The condyles were broken, as well as the olecranon, and the internal condyle projected through the skin. Mr. Freeman, surgeon in New-street, was called to him, and he requested me to attend him. When I visited Mr. L., I found, in addition to the above-mentioned circumstances, a considerable hæmorrhage from the wound, whilst the comminuted state of the joint allowed it to be twisted in all directions.

The treatment which we adopted was, to apply lint to the wound dipped in the blood which flowed from the arm; recourse was also had to a many-tailed bandage, a pasteboard splint, and an evaporating lotion. As the parts were in a tranquil state, the dressing was not disturbed until the 15th of May. Some matter was discharged from the external wound, but the joint never manifested any signs of suppuration. The little discharge that appeared did not exceed that which a small superficial wound would produce. The wound was some time in healing, being prevented by the pressure of the splint on which the arm rested. So soon as it was healed, and the bones united, passive motion was begun; and although the form of the joint was irregular, yet a considerable degree of motion was preserved.

This case gratified me exceedingly, the subject of the accident being universally respected for his virtues and his talents; his constitution was feeble, his age advanced, and he could not have supported suppuration of the elbow-joint, nor is it probable that

he would have survived the loss of his limb. By the simple treatment described, all the dangers which threatened him were averted; and he has, for several years, survived this very severe injury. On the contrary, if poultices be applied in these accidents, the adhesive process is prevented, and suppuration produced, which endangers life, or renders amputation necessary. The next case will exemplify this.

Case CCXCIV.—A woman, between fifty and sixty years of age, was admitted into Guy's Hospital, with a wound of the elbow-joint, and fracture of both the condyles of the os humeri. A poultice was directed to be applied, and fomentation ordered twice a day. On the day following the accident, she had a considerable degree of fever. On the third day the upper arm was exceedingly swollen, attended with an abundant sanious discharge from the wound. On the fourth day her strength was greatly reduced, and the wound had almost ceased to discharge, but the arm was very much swollen. On the fifth day she died.

In all cases of this accident, the arm should be kept in the bent position; for as anchylosis, in a greater or lesser degree, is sure to be the consequence, it is attended with less inconvenience in this position than in any other. The edges of the wound should be kept together by placing a piece of lint dipped in blood over them, supported by adhesive plaster, and a bandage lightly applied, wetted with spirits of wine and water.

If the bones be much comminuted, and the wound large, all the detached portions of bone should be removed; but in old people, when much injury is done, there is often not sufficient strength to support the adhesive process, and amputation should be recommended, unless, however, the surgeon thinks fit to endeavour to save the limb by removing the comminuted ends of the bones. This latter practice, which I so thoroughly illustrated when speaking of compound dislocation of the ankle-joint, should always be adopted when there is a probability of success.

Excision of the Elbow-joint.—The two following valuable cases were sent me in 1834, by Mr. M'Intyre, surgeon to the Newcastle Infirmary.

Case CCXV. — John Spence, æt. forty-nine, on March 10th, 1829, in attempting to get upon a coal-waggon going at full speed, missed his hold, and fell, with his arm bent at the

elbow-joint, across the railway, when both wheels passed over it. On examining the arm, I found a compound oblique fracture of the humerus extending from its condyles into the joint. The radius and ulna were fractured and comminuted about two inches from their articulating surfaces. The integuments and muscles on the outer side were severely lacerated and contused; those on the inner side, with the vessels and nerves, had escaped. There being no alternative but amputation or excision, the latter, much to my satisfaction, was preferred by the patient. I began the operation by cutting away a considerable quantity of destroyed integument and muscles, which would have inevitably sloughed off. The lower end of the humerus was then easily exposed; the obliquity of the fracture obliged me to saw it across, to procure an even surface. The radius and ulna being fractured transversely, were removed by the scalpel. The brachial artery was readily felt at the bottom of the wound. The mutilated limb was now dressed with strips of adhesive plaster and bandaged on my arm splint.

20th. Pulse 120; discharge profuse; swelling and pain considerable; bowels irregular; appetite not good.

30th. Pulse 100; less discharge; pain and fever abated.

April 10th. General health improving; much less discharge.

May 20th. The wound granulating and healing rapidly.

June 30th. The wound is now quite closed, and free from pain. The patient can move his hand and fingers freely.

July 30th. In order to support the sore arm, I ordered a leather case, well padded, and bent to a convenient angle, to be applied.

August 10th. The patient finds much benefit from the leather case, and can now carry a moderate weight, or wheel a barrow with ease, but finds great difficulty in raising his arm above his head.

September 1st. He is now employed in one of the coal mines in a situation he could not have undertaken had he lost his arm.

October 20th, 1834. He enjoys good health, and has good use of his arm.

Case CCXCVI.—Joseph Forster, æt. twenty-one, on March 18th, 1834, received a severe blow on the elbow, owing to a stone having fallen down the shaft of a coal-pit above one hundred fathoms deep. On examination I found a comminuted compound

fracture of the elbow-joint, but, fortunately, the blood-vessels and nerves had escaped injury. I immediately informed him that there was no possibility of saving the limb but by excising the bones, which was readily agreed to. I began the operation by enlarging the wound to nearly the extent of six inches, to enable me to remove the end of the humerus by sawing it off, the fracture being oblique; also to remove the ulna and radius each to the extent of about three inches. During the operation there was but little hæmorrhage; only one cutaneous branch required to be secured. After washing the wound, I brought the edges together, which were easily retained in good apposition by introducing two sutures, and dressing the wound with adhesive plaster, pledget, and bandage. An opiate was then given, and perfect quiet enjoined.

21st. The patient slept pretty well during the last two nights; pulse 100. On removing the dressings I found the wound united to a great extent by the first intention, and looking remarkably well.

24th. Pulse 96; tongue clean, bowels regular, appetite good; he complained of the allowance of food being too small; very moderate discharge from the wound, in one or two places only.

30th. He continues improving, and the arm looks as round and long as the other.

April 10th. The wound is nearly closed; a considerable quantity of cartilaginous or bony substance being deposited, so as to fill up the vacant space between the ends of the bones.

May 10th. He continues to gain strength daily; the wound is healed.

June 20th. He is doing well; ordered sea bathing.

July 20th. He has resumed his employment in the coal mine, but, owing to too great exertion, has brought on inflammation in his arm.

August 10th. He continues well; the arm has now the appearance of anchylosis, having been retained in the bent position during the cure, and it is but very slightly movable; yet the patient can use it in any direction with great strength.

CHAPTER XV.

ON DISLOCATIONS AND FRACTURES OF THE WRIST-JOINT.*

SECTION I. — ANATOMY OF THE JOINT.

There are at this joint two distinct articulations, one between the lower extremities of the radius and ulna, and the other between the radius and the bones of the carpus.

Inferior radio-ulnar articulation. — The lower extremity of the radius has on its inner side a concave surface, by which it rolls on the inferior head of the ulna in the motions of pronation and supination. Both this articular cavity of the radius and the lower head of the ulna are covered with cartilage, and are invested with synovial membrane; which membrane is exceedingly loose where it is reflected from one bone to the other, whence it has received the name of *membrana sacciformis.* It is strengthened by a few thin ligamentous fibres before and behind.

Triangular fibro-cartilage. — The inferior articulation of the radius with the ulna is separated from the wrist-joint, properly so called, by a triangular slip of fibro-cartilage, which is attached by its apex to the root of the styloid process of the ulna, and by its base to the edge of the articular cartilage of the lower extremity of the radius. Its apex is ligament, its base cartilage. This triangular fibro-cartilage is concave on both its

* In the description of the dislocations of the wrist-joint, the Editor is of opinion that the nomenclature is defective, and should be entirely changed. For, as the bones of the carpus are the most movable, the dislocations of the wrist-joint should be thus designated, "Dislocation of the Carpus backwards upon the Radius," "Forwards upon the Radius," and "Partial Lateral Dislocation, inwards, or outwards." As to the dislocation of the ulna at the wrist-joint, no such accident can occur, as it does not enter into the composition of that articulation. Neither can it happen that its inferior extremity can be luxated from the lesser scaphoid cavity of the radius; for the ulna being perfectly fixed, the rotatory motions are performed by the radius upon the ulna. Hence the dislocations of the inferior radio-ulnar articulation are produced by the displacement of the movable radius, and not of the ulna.

surfaces, and is covered on its upper surface by the sacciform synovial membrane; and on its under surface by that of the wrist-joint, which is reflected to it from the cuneiform bone.

WRIST-JOINT. — This is formed by the lower extremity of the radius, and the triangular fibro-cartilage above, and by the first three carpal bones below; the radius being in contact with the scaphoid and lunar bones, and the fibro-cartilage with the cuneiform.

The lower extremity of the radius is concave, both from before backwards, and from side to side, so that the ball of the carpus possesses all the motions enjoyed by the ball and socket joints; but from the greater depth of the posterior rim of the radial cavity, the hand enjoys much more lateral motion when the wrist is bent than when it is extended. It is from this depth of the posterior margin of the radius that blows on the front of the carpus are so apt to cause fracture of the epiphysis of that bone, instead of dislocation.

The wrist is strengthened on each side by peculiar ligaments; one (the radio-carpal) proceeds from the styloid process of the radius, to be fixed to the outer edge of the scaphoid bone; and the other (or ulno-carpal) extends from the styloid process of the ulna to the cuneiform and pisiform bones. Besides these, the radius is connected to the carpus by a thin sheet of capsular fibres both before and behind.

The injuries to this joint that we shall speak of successively, are:

First, dislocation of both radius and ulna upon the carpus.

Secondly, dislocation of the radius only.

Thirdly, dislocation of the ulna.

Fourthly, fracture of the lower extremity of the radius, with or without dislocation of the ulna.

SECTION II.

DISLOCATION OF THE RADIUS AND ULNA.

The first accident, namely, the dislocation of both bones is not of very frequent occurrence; but when it does happen, the bones are thrown either backwards or forwards, according to the direction

in which the force is applied. If a person, for instance, in falling, puts out his hand to save himself, and falls upon the palm, so that a dislocation is produced, the radius and ulna are forced forwards upon the ligamentum carpi annulare, and the carpal bones are thrown backwards; whilst if a person falls upon the back of the hand, the radius and ulna will be thrown upon the posterior part of the carpus, and the carpus itself will be forced under the flexor tendons, which pass behind the ligamentum carpi annulare.

Symptoms.—The appearances of the first dislocation are these: a considerable swelling is produced by the radius and ulna, on the fore part of the wrist, and a similar protuberance upon the back of the wrist by the carpus, with a depression above it; the hand is bent back, being no longer in the line with the fore-arm.

In the other dislocation these symptoms are reversed, but it is easy to see that in both cases two swellings will be produced, one by the radius and ulna, and the other by the bones of the

carpus, according to the direction in which they are thrown; and these become the diagnostic signs of the accident.

Diagnosis.—Severe falls upon the palm of the hand will produce sprains of the tendons on the fore part of the wrist, and occasion a very considerable swelling of the flexor tendons, opposite the wrist-joint. This accident assumes the appearance of dislocation, but may always be distinguished from it by the existence of one swelling only, which does not appear immediately after the injury is received, but succeeds it gradually. And further, if the surgeon be called directly after a dislocation has happened, there is then a great flexibility of the hand, as well as distortion, and the extremities of the radius and ulna on one side, and of the carpal bones on the other, are easily detected. Moreover, the relative situation of the styloid pro-

cesses of the radius and ulna, with the carpal bones, is altered in dislocation, but not in the sprain.*

Treatment.—The reduction of this dislocation, in whatever form it may have occurred, is by no means difficult. The surgeon grasps the patient's hand with his right hand, supporting the fore-arm with his left, whilst an assistant places his hands around the upper arm, just above the elbow; they then pull in different directions, and the bones become easily replaced. The reduction is in both cases the same, for the muscles draw the bones towards their natural position as soon as they are separated from the carpus by extension.

When the hand has recovered its natural situation, a roller, wetted in spirits of wine and water, is to be lightly applied around the wrist, and the whole is to be supported by splints, placed before and behind the fore-arm, and reaching as far as the extremities of the metacarpal bones, for the more perfect security of the limb.

The following curious case, in which both wrists were dislocated; one forwards, and the other backwards, occurred in the practice of Mr. Rudall, of Sheepwash, and was communicated to me in July 1840, by Mr. Haydon, surgeon, of Goswell-road, London.

Case CCXCVII.—J. D., aged about thirteen years, applied on June 11th, 1840. He had been thrown very violently from a horse, which ran away with him, and fell on the back part of the palms of his hands, (I mean the parts contiguous to the carpus,) and on the upper part of his forehead. On examining him, we found a lacerated wound of the scalp about two inches in length. The left wrist presented a considerable protuberance on its anterior aspect, and the styloid process of the radius no longer had its station with regard to the trapezium. The radius was thrown, forward before the carpus, and took up its residence on the scaphoid and trapezium. The right wrist presented a very considerable tumor on its posterior aspect, occasioned by the presence of the radius and ulna; and there was a very irregular knotty tu-

* In fractures of the fore-arm near the wrist, says Boyer, the inflammatory swelling might render the diagnosis less clear, and cause the fracture to be mistaken for a luxation of the hand. But the two cases may be distinguished by simply moving the hand; by which motion, if there be luxation without fracture, the styloid processes of the radius and ulna will not change their situation; but if a fracture do exist, these processes will follow the motion of the hand.—*Ed.*

mor, terminating abruptly, on its anterior aspect, caused by the presence of the bones of the carpus.

There was a very careful examination made, to determine what parts came in contact with the resisting force. We found very extensive bruises on the palms of both hands, but not the slightest on the back of either hand.

We could not obtain the slightest evidence of any fracture existing; and recollecting the opinion of Dupuytren, "that there was not a single unequivocal instance on record of a *dislocation* of the radio-carpal articulation, and that he invariably found these pretended accidents always turned out to be fractures of the radius near the articulation," we were very careful in our examination.

Moreover, we were strengthened in our opinion that this was a case of dislocation, unattended with any fracture, because the dislocations appeared so perfect; the two tumors in each member so distinct; the reduction so complete; the strength of the parts after reduction so great; and lastly, by the very trifling pain felt after reduction, for within an hour after, the patient could rotate the hand, and supinate it when prone—this could not, we believe, have been done, had there existed a fracture.

We should not have reported this case, had it not seemed important, and one of very rare occurrence; for we find in the same person, from the same accident, and from a force applied in the same manner, one wrist (*the left*) presenting a dislocation of the radius forward; the other (*the right*) presenting a dislocation of the radius and ulna backwards; while Sir A. P. Cooper, whose great experience makes all his opinions possess great weight and value, states, in his book on dislocations and fractures, that "the dislocation of both bones is not of very frequent occurrence; but when it does happen, the bones are thrown either backwards or forwards, according to the direction in which the force is applied." Now here we have a dislocation both ways, from the same force.

June 24. The patient is going on well. We have again carefully examined the wrists, and remain convinced in our first opinion, that there is no fracture. There is at present no deformity. The patient suffers from the usual effects of extensive laceration, and spraining of the ligaments.

The means of reduction and after-treatment have not been alluded to, as we believe they differed in no respect from those that are usually employed.

The next case is taken from one of the medical journals.

CASE CCXCVIII.—"I happened," says the narrator, "to be at a friend's house, and was asked if I would like to see the hand of one of the daughters, a young lady of twenty, which had been dislocated for two years. It was kept wrapped up in a napkin on account of its unsightly appearance. Upon examination I found it in the following state. The scaphoid and lunar bones were so completely thrown out of the scaphoid cavity, that the posterior part of the upper row of carpal bones, with the ends of the radius and ulna, represented the anterior part of a stump. The fingers were strongly clenched into the palm of the hand, and the knuckles, formed by the junction of the first phalanges with the metacarpal bones, were so firmly pressed against the inside of the fore-arm, opposite the flexor tendons, that the skin was ulcerated. Upon inquiring how this had happened, I was informed it was in consequence of convulsive fits. Whether the parts were thus dislocated by the strong action of the flexor muscles during an hysteric paroxysm, or in consequence of a person inadvertently aiding that action, by pressing on the back of the hand, appeared immaterial; and upon reflecting that this derangement of parts had not been accompanied by any morbid process, I, to the surprise of the young lady and her friends, gave it as my opinion that the parts might be restored to their former state. She accordingly came to Lewes to be under my care for that purpose.

"I commenced the process in the following manner. Having immersed the hand in warm water, I succeeded in getting the little finger sufficiently out to admit of a small bolster of wool, wrapped in linen, being placed within its grasp; in which situation it was left. This plan was pursued daily; the fingers being taken in succession, and the bolster gradually increased till it exceeded the size of a cricket-ball. Having succeeded thus far, the wrist became the next object of trial, the rigidity of which was so extremely great, that had not my patient possessed the most laudable courage and perseverance, she must have been disheartened from any farther attempt. By the use of warm water, and embrocating the part with oil, it gradually gave way, in the course of about ten weeks, to a moderate degree of force applied by my hand daily.

"During this stage, till the carpal bones were replaced in the scaphoid cavity, it was extremely difficult to maintain the ground

we had gained from time to time, in consequence of the bolsters, though aided by bandages, being insufficient to prevent the flexor muscles from drawing the hand down into the situation which I have described.

"Under these circumstances, the utmost advantage was derived from an apparatus which I contrived for the purpose, and which consisted of a spring made of iron, which projected from the back part of the wrist over the back of the hand. To this was fixed a piece of soft leather, passed round the inside of the fingers and palm; by which means the hand was effectually retained in the situation in which it was left. When the carpal bones had been replaced, they were kept in their situation by means of a common splint passing along the outside of the arm, from the elbow to the ends of the fingers, and another of the same length along the inside; these were continued for some time, and then laid aside; since which time (now upwards of two years) the hand has continued perfectly well."

COMPOUND DISLOCATION OF THE WRIST-JOINT.

The following case of this accident came under the Editor's care in Guy's Hospital during the present year. It is given in the words of Mr. Pope.

Case CCXCIX.—Dennis M'Carty, an Irishman, æt. twenty-eight, was engaged in carrying wheat on board a vessel, when his foot slipped, and in endeavouring to save himself by placing his hand on the side of the vessel, the sack fell on the back of the wrist-joint and produced a compound dislocation. The carpal bones were dislocated forwards upon the radius and ulna, and the flexor tendon of the thumb was torn through. Upon the arrival of Mr. Cooper, amputation was deemed necessary, and was performed at half past 7 P.M., about two hours after the accident happened. The circular operation was preferred. This occurred on April 6th, 1841. Two arteries were secured at the time of the operation; but when the circulation became more fully established, it was then necessary to tie two others, as there was secondary hæmorrhage. Freezing mixture was also applied.

April 7th. The patient has passed a restless night, and appears rather feverish: he was ordered a dose of calomel and opium.

10th. The stump was dressed for the first time since the operation; it appeared healthy. There was slight suppuration.

15th. The stump was dressed again, and a slight erysipelatous blush was observed round the wound. The man complained of pain in the stump. Tongue furred.

He was ordered a drachm of Epsom salts in a saline draught, three times a-day.

18th. He was considerably better: the stump looked healthy.

20th. The first ligature came away; and the others on the 30th; and on May the 18th the patient was discharged, well.

SECTION III.

DISLOCATION OF THE RADIUS AT THE WRIST.

Symptoms.—This bone is sometimes separately thrown upon the fore part of the carpus, and lodged upon the scaphoid bone and the os trapezium. The outer side of the hand is, in this case, twisted backwards, and the inner, forwards: the extremity of the radius can be felt and seen, forming a protuberance on the fore part of the wrist, and the styloid process of the radius is no longer situated opposite to the os trapezium.

Cause.—This accident usually happens from a fall when the hand is bent back; and I have also known it arise from a fall upon the hand, by which the condyles of the os humeri were broken obliquely, and the radius dislocated at the wrist, being thrown upon the fore part of the scaphoid bone, where it could be distinctly felt; this case happened in the lad whom I mentioned when speaking of fractures of the os humeri (Vide Case CCLII.); his hand was hanging backwards, and he felt great pain upon its being moved.

Treatment.—The extension necessary to reduce a dislocation of the radius, and the treatment which it demands, are the same which are required for the luxation of both bones; and there is no difficulty in the operation, the hand being extended whilst the fore-arm is fixed.

SECTION IV.

DISLOCATION OF THE ULNA.

As this bone does not form a part of the wrist-joint, but is received into a capsular ligament of its own, and is separated from the wrist by a movable cartilage, it is more frequently dislocated, separately, than the radius.

When this accident occurs, the sacciform ligament is torn through, and the bone generally projects backwards,* without any accompanying fracture of the radius. Dislocation forwards is rare. The ulna rises and forms a protuberance at the back or front of the wrist, as the case may be; and the hand is twisted; and although it may be easily pressed down into its natural position, yet so soon as the pressure is removed the deformity returns, as the lacerated ligament has no longer the power to retain it in its place.

The diagnostic marks of the injury are the projection of the ulna, much above the level of the os cuneiforme, and the altered position of the styloid process, which is no longer in a line with the metacarpal bone of the little finger.

Treatment. — The reduction is accomplished by pressing the ulna into its natural articular cavity by the side of the radius; and in order to retain it in this situation, splints must be placed along the fore-arm, in a line with the back and palm of the

* Boyer met with a case of luxation of the ulna anteriorly, which is exceedingly rare. A woman, engaged in a riot that took place near the market-place of St. Germain, was pushed out of the house by a man who twisted her hand violently in the supine direction. She felt horrible pain, and cried out, that her wrist was breaking, and immediately saw that a deformity had occurred. Boyer was called in: he found the hand fixed in the supine state, the fore-arm bent, and the hand supported before the breast. The inferior extremity of the ulna crossed before the radius in a remarkably oblique direction. The reduction was accomplished only by the fourth attempt.

The luxation of the inferior extremity of the ulna backwards, says Boyer has been frequently observed. As the luxation forwards is produced by a violent supination, so that backwards is the result of a violent and sudden pronation. Such was the case of a female mentioned in Dessault's Surgical Journal, who luxated the cubitus backwards in wringing wet clothes; in doing which the hands are put in the greatest state of pronation possible.—*Ed.*

hand; the splints should be padded throughout; but upon the extremity of the ulna an additional compress of leather should be placed, to keep it in a line with the radius; a roller should then be applied over the splints to confine them with sufficient firmness.

For the following communication on the subject of this accident, I have to thank my old pupil, Mr. Sylvester, who sent it to me in the year 1840.

"I happened," says Mr. Sylvester, "in the course of conversation, to hear a surgeon say that, some years since, he had met with a very puzzling injury of the wrist; that he had vainly attempted to remedy the mischief, and that he was not a little chagrined at his want of success. The deformity, he said, was very striking, but the actions of the joint were now tolerably free, having been gradually restored. He followed up this candid statement by offering to introduce me to the patient, from whom I obtained the following account."

Case CCC. — "M. W., aged seventy-four, about four years since, returning from the village church, (by the by, the most romantically situated one in Somersetshire,) fell, with tremendous violence, down a flight of stone steps, and alighted on her right hand on the hard, chequered pavement. The wrist became instantly swollen to an immense size, and the nature of the accident could not be ascertained, but there was a peculiar twisted appearance which remained after the subsidence of the tumefaction, and still remains. There is tolerable use of the joint; but it is weak; there is very free motion between the radius and ulna, proving that they have been separated by the violence.

"It has often struck me, that the common description of the motions of the radius and ulna at the wrist is incorrect. The lower end of the radius does *not* move upon the lower end of the ulna, like an axis or spoke; the pronation and supination of the hand are effected by the turning of the *upper* end of the radius and ulna; both bones rotate, as the slightest attention to one's own arm will discover. I say this, however, under correction of, and with the humblest submission to your opinion."

SECTION V.

FRACTURES OF THE LOWER END OF THE RADIUS.

SYMPTOMS.—This bone is generally fractured about an inch above the styloid process. The cure is difficult, the lower extremity of the shaft of the bone being drawn by the action of the pronator quadratus amongst the flexor tendons, where it may be distinctly felt; in this situation it interferes very considerably with the motions of the fingers, by confining the action of the flexor profundus perforans. Mr. Cline, in his lectures on this subject, used, nearly in these terms, to recommend the following treatment. "When a fracture of the radius happens just above the wrist-joint, you must be very careful in your treatment of it, to prevent the injury from leading to the permanent loss of the use of the fingers; for so soon as the injury has happened, the pronator quadratus muscle draws the fractured end of the bone obliquely across the fore-arm, amidst the flexor tendons; your object, therefore, in the treatment of this accident is, to prevent the action of the pronator from producing that effect; and the mode of treatment which you are to adopt is, to make the hand by its weight oppose the action of that muscle. For this purpose, when the bone has been placed in its right position, by drawing the hand in a line with the fore-arm, apply a roller around the fore-arm to the wrist; then a splint upon the fore and back part of the arm to reach to the palm and back of the hand, so as to preserve it in a half supine position; and confine the splints by means of a roller, which should reach only to the wrist. The arm is then to be placed in a sling, which is also to support it no farther than to the wrist. Thus the hand, being allowed to hang between the ends of the splints, draws the end of the radius, so as to maintain a constant extension upon it, opposing the action of the pronator quadratus muscle, and keeping the broken end of the bone constantly in its place."

An oblique fracture of the lower extremity of the radius in the situation of the junction of the epiphysis with the shaft of the bone, that is to say, at about three quarters of an inch above the styloid process, is a very common accident, and is readily caused by falls on the front of the carpus; in fact, it may be readily

enough produced in the dead subject by forcibly pushing the hand backwards, as the subjoined communication from my nephew, Mr. Edward Cock, the demonstrator at Guy's Hospital, will testify.

In the year 1833 I had been making some experiments on two wrist-joints with a view of ascertaining the circumstances under which fractures and dislocations were liable to occur, and I begged Mr. Cock to examine them, and report the results to me; and they were as follow:—

"In the first arm," says Mr. Cock, "you will remember, a knife was first passed between the radius and ulna to divide the ligaments of the sacciform joint and the interarticular cartilage; the hand was then bent forcibly backwards, without however producing any displacement of the ulna, and when still greater violence was used, the radius gave way. On examination it appeared that the knife had completely divided the sacciform ligaments and the interarticular cartilage. The extremity of the radius was broken off at the epiphysis and completely detached. The ulna was not in the slightest degree displaced, having apparently been retained in its situation by the strong internal lateral ligament of the wrist, which ligament was uninjured.

"In the second arm, you may remember, the hand was bent back without any previous division of the ligaments, and notwithstanding great force was used, no displacement of the bones could be produced, although the extremity of the ulna seemed to have acquired a somewhat unnatural degree of mobility. On examination, not the slightest laceration had taken place either in the ligaments of the sacciform joint or the interarticular cartilage, nor indeed in any of the ligaments of the wrist. The radius, however was broken, as in the other arm, although the separation was not so complete.

"This fracture would probably account for the undue degree of mobility observed in the extremity of the ulna.

"Should we not infer from this, 1st, that it requires a much less degree of force to fracture the radius, than to displace the extremity of the ulna, or to rupture any of its connecting ligaments, even supposing that this last could be produced, without extraordinary violence? 2dly, that when the interarticular cartilage has been torn through or divided, the internal lateral ligament of the wrist tends powerfully to prevent the dislocation of the ulna?"

This fracture in the living subject is accompanied with some degree of projection of the ulna at the back of the wrist; and when the patient holds his fore-arm horizontally in a state of pronation, the back of the wrist appears deeply bent, and there is an evident projection of the radius and ulna on its dorsal surface, and of the carpus on the palmar, that has no doubt often led to the supposition that a dislocation existed. But I need not again mention the diagnostic signs.

The next case, in which the radius of one arm was fractured, and the opposite wrist dislocated, is worthy of notice.*

CASE CCCI.—T. C., aged nine, was admitted into the University College Hospital, London, on May 12th. He states that yesterday, about four o'clock in the afternoon, he was out bird's-nesting, and had climbed to the top of an elm, thirty or forty feet high, when the branch on which he stood gave way, and he fell to the ground. He alighted on the palms of the hands.

He was brought into the ward at half-past six, and on examination, Mr. Taylor, the house surgeon, readily detected dislocation of the left wrist. The carpus formed a considerable projection on the back of the articulation, while the styloid processes of the radius and ulna were distinctly felt in the palm; these bones could be traced through their whole course, and were found to be entire. The fore-arm was much shortened and deformed.

On extending the parts, and at the same time moulding the wrist into shape, the bones returned into their situation suddenly, and with a snap; the patient immediately regaining the use of the joint.

The right wrist next demanded attention. There was some deformity from effusion into the shaft of the flexor tendons, and great pain on motion. On careful manipulation, a fracture of the radius, close to the styloid process, was detected. The general appearance of the wrist had some resemblance to a dislocation such as described. Fomentations were applied to the left wrist.

The right fore-arm was now extended slightly, with the hand inclining downwards; pasteboard splints, padded with tow, were placed on each side, and retained by rollers. On the following morning the same apparatus was applied to the left arm.

* Lancet, June 12th, 1841.

If this fracture occurs in a very oblique direction, so great a displacement of the radius ensues, that dislocation of the ulna forwards is also produced.

I have given a plate of this accident, from a preparation of it in the museum at St. Thomas's Hospital. The lower end of the radius is seen in its natural situation, articulated with the carpal bones. An inch above the ligamentum annulare carpi, the broken extremity of the radius is seen projecting under the flexor tendons of the wrist, which have been removed to show its situation; the ulna is dislocated forwards, and rests upon the os orbiculare.

SYMPTOMS.—The signs of this injury are, that the hand is thrown back upon the fore-arm, so as, at first sight, to exhibit the appearance of a dislocation of the hand backwards; and a projection of the ulna is felt under the tendon of the flexor carpi ulnaris muscle, just above the os orbiculare; and thirdly, the fractured extremity of the radius is easily detected, under the flexor tendons of the hand. I have seen this accident frequently, and at first did not exactly understand the nature of the injury; indeed, dissection alone taught me its real character.*

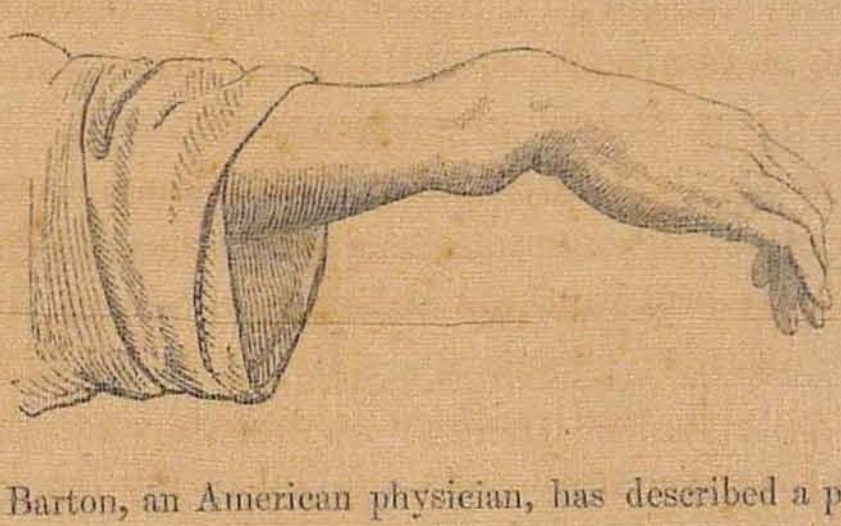

* Dr. Rhea Barton, an American physician, has described a peculiar variety of this accident, in which the posterior edge of the articular cavity of the radius is broken off, and the carpus partially dislocated backwards.—*Ed.*

Treatment.—A very powerful extension is required to bring the broken ends of the radius into apposition, and great difficulty exists in confining them when this is effected. The hand is to be extended by the surgeon, and the fore and upper arm are to be drawn back by an assistant; then a cushion is to be placed upon the inner part of the wrist, and another to the back of the hand, and are to be firmly bound down by a roller, for the purpose of keeping the ulna and broken end of the radius in situ; a splint, well padded, is then to be applied to the back part and inner side of the fore-arm, which is to extend to the extremities of the metacarpal bones; these splints are to be confined by a roller, reaching from the upper part of the fore-arm to the wrist, and no further. The arm should be then placed in a sling. This position is to be preserved for three weeks in young persons, and for four or five in the aged, before passive motion be attempted. The recovery in these cases is slow, and six months will sometimes elapse before the motion of the fingers is completely restored.

COMPOUND DISLOCATION OF THE ULNA, WITH FRACTURE OF THE RADIUS.

This is a very serious accident when the radius is much comminuted, but recovery proceeds very well when the radius is broken without being shattered. I saw a case of this injury in Hertfordshire, in which the man met with the accident by falling upon the back of his hand, and the ulna protruded an inch and a half through the integuments; the bone was immediately reduced and bandaged; the wound healed by the adhesive process, and the man recovered the perfect use of his limb.

The ensuing case was reported by Mr. Peploe Cartwright, dresser at Guy's Hospital.

Case CCCII. — Susannah Griffith, a woman from Rotherhithe poorhouse, aged seventy-two, was admitted into Guy's Hospital, on the 10th of April, 1822. Whilst walking on the pavement, her foot had accidentally slipped, and she fell with her right hand under her in such a manner that the palmar surface was forcibly bent against the inner side of the fore-arm; the carpal extremity of the ulna was, consequently, thrown violently outwards through the integuments, and the lower end of the radius was obliquely fractured.

The parts were reduced, and the edges of the wound brought as closely into contact as their lacerated condition would admit; a pledget of lint, dipped in blood, was applied to the part, and a bandage over it.

On the third day the arm became tumefied and inflamed, and poultices were applied. By the 21st of May, the fracture of the radius had united, and the patient recovered the use of the thumb and two first fingers; the whole of the articular cartilage had come off in the form of black sloughs, intermixed with spiculæ of the adjacent bone, and the granulations were so prominent, as to lead to the application of adhesive straps; the healing process, however, was greatly retarded by a frequent displacement of the extremity of the ulna, owing to the constitutional irritability of the patient, and to the œdematous state of the arm, which did not allow the bandage to be applied with the tightness requisite for its due confinement.

On the 18th of June, the wound was nearly healed; but still a small portion of the end of the ulna will exfoliate, and she applies the nitric acid lotion to hasten its exfoliation.

Case CCCIII.—A man was admitted into St. Thomas's Hospital, under the care of Mr. Chandler. I now forget in what manner the accident had happened, but the ulna projected through the integuments at the back of the carpus; and a compound fracture of the radius, with great comminution of the bone, was produced. The ulna was at first replaced, but immediately resumed its dislocated position on the back of the wrist, although it did not again protrude through the skin. The hand and fore-arm were placed in a poultice, and were ordered to be fomented twice a day. A copious suppuration ensued, attended with violent constitutional irritation; and Mr. Chandler, in order to save the patient's life, after a lapse of five weeks, amputated the limb.

On dissection, I found the ulna dislocated backwards, and its extremity just drawn within the opening of the integuments, through which it had protruded. The radius was broken into several pieces, some of which, being loose, were necessarily a great source of irritation; the tendons and muscles were some of them lacerated, as the extensor carpi radialis longior, and the extensors of the thumb.

TREATMENT.—In a similar case it would be proper, when loose pieces of bone can be felt at the extremity of the radius, that the wound should be enlarged for their removal; and instead of fomentations and poultices, a quantity of lint, dipped in the patient's blood, should be applied round the wrist, lightly bound with a roller. The arm should be supported upon a splint, so as to be kept perfectly free from motion; evaporating lotions should be applied; and the limb should not be disturbed, unless the patient has symptoms of a suppurative process, when a small opening should be made in the bandage to allow of the escape of pus, but still the bandages should be suffered to remain. The patient should be bled from the arm if the inflammation and constitutional irritation be considerable, and under these circumstances, leeches should be occasionally applied. The bowels should be kept gently open, but all active purging should be avoided.

CASE CCCIV.—John Winter, June 21st, 1818, fell from a ladder on his hand and knee; the hand was bent back; the radius was broken, and the ulna caused to protrude at the inner part of the wrist. Mr. Steel, of Berkhampstead, attended: the bones were reduced, a roller was put around the wrist, and the wound healed very soon by adhesion. In seven weeks he was well, excepting that a slight swelling of the tendons remained for a few weeks longer.

The next case was sent to me for my opinion by Mr. Davies, of Merthyr, who certainly acted wisely in endeavouring to save the patient's limb, for a mutilated hand is better than none.

CASE CCCV.—"I had lately under my care," says Mr Davies, "a case of compound dislocation of the ulna at the wrist, with comminuted fracture of the radius a little higher up, and of course a great deal of contusion of the soft parts. I put up the fore-arm in the usual manner with splints, the hand in a mid-state between pronation and supination, and the limb consequently resting on the wound. In a short time, as might have been expected,

a high degree of inflammation supervened, and the neighbourhood of the wound, as well as the ulnar aspect of the limb, assumed a livid appearance. Apprehensive that, if those parts continued to bear the pressure caused by the weight of the greatly tumefied limb, very considerable sloughing, if not gangrene, would be the result, I changed its position, and placed it prone on a broad splint; emollient cataplasms and the usual applications were made use of. In consequence of very considerable suppuration, it became necessary to practise extensive incisions in the vicinity of the wound, and on the ulnar aspect of the limb: I was thus constrained to continue the same position of the fore-arm. Long before those incisions healed, the wrist became anchylosed, and the fracture united; the radio-ulnar articulation at the carpus being consolidated, the power of rotating the hand, in even the slightest degree, was, of course, lost. A sinus communicated with the fracture, through which several pieces of bone were removed, and the probe indicated that there were yet more in a state of necrosis.

"The patient continuing to find considerable pain in the arm, and thinking that, because he had lost the power of rotating it, and of bending the wrist, that it would be useless to him, urgently requested me to remove it, which I could not conscientiously accede to, for the following reasons:—there was no swelling nor inflammation, nor anything to indicate considerable local disease; the thumb and fingers were flexible, and he would have acquired the perfect use of them; and, above all, his constitution, so far from betraying signs of being undermined by the local affection, had rallied, and he was gaining strength and flesh. In this determination I was corroborated by the most respectable practitioners, here and in the neighbouring towns, to whom he had resorted for the purpose of having his arm amputated, on my refusal. All these having similarly declined, he applied to a person in limited practice here, who immediately removed the limb, after impressing on the patient's friends, and circulating the assertion as widely as possible, that its non-rotation proceeded from improper treatment. Under ordinary circumstances, I should have passed such a statement unheeded, but there are some attending this case which render me anxious that the truth should be known, and to get your opinion on these two points, namely,—whether immobility of the radius is not a necessary

consequence of its anchylosis at the wrist with the ulna? and, if it be, whether in such a state of parts as that which I have described,—where anchylosis and consequent non-rotation must be the necessary results of any treatment, and the hand being permanently fixed in one position instead of another the only difference,—a surgeon is not justified in placing the limb in such a position as will best obviate dangerous pressure on the parts most injured? Should you favour me with that opinion I shall feel myself under a great obligation."

CHAPTER XVI.

ON DISLOCATIONS AND FRACTURES OF THE CARPAL AND METACARPAL BONES, AND OF THE FINGERS AND TOES.

SECTION I.—DISLOCATIONS OF THE CARPUS.

The eight bones of the carpus are joined to each other by short ligaments, which pass from bone to bone, allowing but a very slight degree of motion of one bone upon another; but, besides this mode of articulation, there is a transverse joint between the first and second row of carpal bones, forming a complete ball and socket. The ball is produced by the rounded extremities of the os magnum and os unciforme: the cup, by the scaphoid, lunar, and cuneiform bones. A ligament passes from one row of bones to the other, including this articulation.

The dislocation of a carpal bone is but of rare occurrence; the following case, which was reported by Mr. F. R. Elkington, dresser at Guy's Hospital in 1822, gives an example of it.

Case CCCVI. — Mary Nichols, aged sixty, slipped down, and, trying to save herself, fell upon the back of her hand and fractured the radius obliquely outwards, through the lower articulating surface. The fractured portion, with the os scaphoides, was thrown backwards upon the carpus. The wrist was slightly bent, and there was an evident projection at the back of the carpus. The fingers could be completely extended, but only semiflexed. A crepitus might be distinctly felt, either by moving the hand, or the styloid process of the radius backwards or forwards. By slight extension, and steady pressure upon the displaced part, the fracture was easily reduced. There was much extravasation and pain; six leeches were applied, afterwards evaporating lotions, and two long splints; and as soon as the swelling had in some measure subsided, strips of

soap plaster. At the end of six weeks the fracture was firmly united, but the motions of the wrist are still imperfect, and the hand cannot grasp anything.

Ganglia are sometimes mistaken for this accident; but in such cases a smart blow with a book will disperse the swelling, and dispel the cloud of doubt which enveloped the mind of the surgeon.

The os magnum and the cuneiform bone, from relaxation of their ligaments, are sometimes thrown somewhat out of their natural situation, so that when the hand is bent, they form protuberances at the back of the wrist. This state is productive of so great a degree of weakness, as to render the hand useless unless the wrist be supported. I was consulted by a young lady, a patient of Mr. Cumming, of Chelsea, who had such a projection of the os magnum, that she was, in consequence, obliged to give up her music and other accomplishments, on account of the attendant weakness; for when she wished to use her hand, she was compelled to wear two short splints, which were adjusted to the wrist, and bound upon the back and fore part of the hand, and fore-arm. Another lady, who had a weakened state of limb, arising from a similar cause, wore for the purpose of giving it strength, a strong bracelet of steel chain, clasped very tightly around the wrist. But the supports generally directed to be worn in these cases are straps of adhesive plaster, and a bandage over the wrist to confine and strengthen it. The affusion of cold water upon the hand from a considerable height may also be employed, and the part should be afterwards rubbed with a coarse towel, to give vigour to the circulation, and strength to the joints.

Case CCCVII.—M. Richerand, the Editor of Boyer's Lectures on Fractures and Dislocations, met with a remarkable case of dislocation of the os magnum. A woman, during a labour pain, squeezed the edge of the mattress violently, turning her wrist forwards; she instantly felt a slight crack and some pain, to which her other sufferings did not allow her to attend. Fifteen days afterwards, she showed her hand to Professor Baudelocque, who attended her, and who sent M. Richerand to her. He found a hard circumscribed tumor at the back of the carpus, which consisted of the head of the os magnum, and was readily replaced by making gentle pressure on it and extending the

hand. Chopart had met with a similar case, so had Boyer, and M. Richerand had also seen one other case of this dislocation, without any other injury.

Case CCCVIII.—Daniel Woodhill, a young, stout, and muscular policeman, came to Guy's Hospital in December 1830, in consequence of an injury his wrist had sustained from a fall on the hand, which was bent under him to such a degree as brought the palmar aspect of the fingers in contact with the fore-arm. Upon examining the hand, (the part where he complained of most pain,) a round and hard tumor, rather larger than a marble, produced a most evident deformity on the back of the wrist, opposite to and above the base of the metacarpal bone of the middle finger. The hand was slightly bent, and extension gave considerable pain; the tendon of the extensor carpi radialis brevior muscle was thrown slightly out of its course, and was rather nearer than natural to the radial side of the hand; the fore-finger was abducted from the middle one, and any attempt to approximate them gave great pain at the bases of their metacarpal bones; and opposite to the base of the middle one there was a depression quite evident both to the sight and touch. Reduction was attempted by extending the whole hand, at the same time making pressure upon the displaced bone: this not succeeding, extension was made from the middle and fore-fingers only, while pressure was kept up on the os magnum, which suddenly slipped into its place without any difficulty: the tumor disappeared; the depression below it was filled up, and the middle and fore-fingers were approximated; in short, the whole hand regained its natural shape; on flexing it, however, the dislocation immediately recurred, and the whole deformity returned. The bone was then again reduced, and to maintain its coaptation, a splint was placed on the palmar surface of the fore-arm and hand, while a compress was applied on the dorsal surface of the wrist immediately upon the os magnum, and the bandage which confined the whole apparatus was kept wet with evaporating lotion. The man went home, as he was anxious to do so, but he presented himself at the hospital again in two days, when it was found that the bone had been retained in its place, although the patient had loosened the bandage in consequence of some swelling which had occurred. On removing the splint and performing the slightest flexion of the hand, the os magnum

again became dislocated, and was again put up as before. He was in the habit, for ten days after, of frequently coming to Guy's and showing the dislocation to the pupils, as it was always easily reduced, and often by pressure only. I described to him the necessity of his allowing the bone to remain for some time in its natural situation, if he wished to recover the permanent use of his hand; and that therefore he ought by no means to submit to this repeated displacement. A day or two afterwards, he was committed to prison for some offence, and has not since been heard of.*

COMPOUND DISLOCATION OF THE CARPAL BONES.

These accidents are of frequent occurrence, and they are generally caused by guns bursting in the hand; portions of the instrument being forced through the carpus, and between the metacarpal bones.

In these cases a carpal bone may be sometimes removed by dissection, and the patient may recover; not only saving his hand, but, in a considerable degree, preserving its motions; of which the following case, reported by Mr. Fagg, dresser at Guy's Hospital, is a good example.

Case CCCIX.—Richard Mitchell, aged twenty-two, was admitted into Guy's Hospital, under Mr. Forster, on the 17th of October, 1822, for an extensive wound in the wrist-joint, inflicted by what is called a wool-comber's devil. On examination it was found that the wound extended through two thirds of the circumference of the joint, and was attended with a great deal of contusion; the scaphoid bone projected at the back part, being attached only on the side towards the joint; in consequence of this, the joints into which it enters were laid open; the extensor tendons of the thumb, and of the middle and fore-fingers, were torn through; the radial artery was also torn, but did not afford any considerable hæmorrhage. The scaphoid bone was removed with a scalpel; the edges of the wound were brought together by sutures, and lint dipped in blood was applied to it and confined by adhesive straps; the fore-arm and hand were laid on a splint, so as to keep the joint perfectly at rest; the patient was bled to twelve ounces, and an evaporating

* Surgical Essays, p. 223.

lotion ordered. In two or three days the dressings were removed, in consequence of the pain, when a good deal of surrounding inflammation was found, and in one spot a slough; the sutures were removed, and a poultice ordered; two or three days after this, abscesses formed along the thecæ of the tendons which were opened. The slough quickly separated, and the inflammation subsided, as the suppurative process became established. In two or three weeks, the wound was so well filled, as to allow the application of adhesive straps, under which treatment it gradually healed. The only constitutional symptoms which occurred during the progress of the case were those of common irritative fever, which were relieved by the exhibition of antimony, with opium and the liquor ammoniæ acetatis, and the use of mild cathartics; and a pulmonic affection, which threatened phthisis, was relieved by the use of leeches and diaphoretics, but it considerably retarded his recovery.

Whilst his wound was in the progress of healing, passive motion was early and regularly resorted to; and after it had healed, friction, with the soap liniment; but he had only a limited power of moving his fingers when he left the hospital.

The only intelligence I can now gain of him is, that he has lately gone to work, under the hope that the constant habit of grasping bodies (which indeed I strenuously recommended to him previously,) will restore the motion of his fingers.

When only one or two of the carpal bones are displaced by guns bursting in the hand, they may be dissected away; but if more considerable injury be done, amputation will be necessary.

SECTION II.

DISLOCATIONS AND FRACTURES OF THE METACARPAL BONES.

These bones are so firmly articulated with the bones of the carpus, that I have never seen them dislocated but by the bursting of guns, or by the passage of heavily-laden carriages over the hand; and in each of these cases there is generally so much injury produced as to render amputation necessary. In the former

of these accidents, a bone, and sometimes two, are capable of being removed; and if it be necessary to amputate the middle and ring finger, the fore and little finger may be so nicely brought together, and secured in such exact adhesion, as to produce little deformity.

Case CCCX.—I was called by Mr. Hood, surgeon at Vauxhall, to a Mr. Waddle, of Bow-lane, Cheapside, whose gun burst whilst he was shooting, and whose hand was lacerated by a portion of the barrel passing through the middle of it; the metacarpal bones of the middle and ring fingers were fractured, and also much comminuted by the violence of the injury, but the integuments were only lacerated, and not completely removed. I dissected out the two fingers, with the metacarpal bones which supported them, and brought the edges of the skin together by suture, approximating the fore and little finger, and applying a roller, so as to bind them together; the parts united perfectly, and the maimed hand was afterwards extremely useful to him: the case, indeed, is highly worthy inspection.

Case CCCXI.—A boy, twelve years of age, was brought into Guy's Hospital, who, by the bursting of a gun, had his thumb and all the fingers, excepting the fore-finger, blown to pieces; the whole hand was exceedingly shattered, and the metacarpal bones were separated from the carpus. Upon examination of the hand, I found that the tendon of the fore-finger was uninjured, so that its use remained perfect; and as the integument could be still saved, so as to cover its metacarpal bone, I dissected out the trapezium (the thumb had been entirely carried away by the concussion), and the metacarpal bones of all the fingers, excepting that of the fore-finger, which was afterwards of the greatest use to him. I kept him for some time at the hospital, to show to the students the restorative powers of nature, and the utility of this finger, saved out of the wreck of his hand; he used it as a hook with the greatest facility.

Fracture of the Head of a Metacarpal Bone.—The extremity of the metacarpal bone towards the fingers, which is called its head, is sometimes broken off, and it gives the appearance of dislocation of the finger, as the head of the bone sinks towards the palm of the hand. In the treatment of this case, a large ball is to be placed in the hand, and to be grasped by it, and bound over it by

a roller; and thus the depressed extremity of the bone is raised to its natural situation.*

The following case gives an example of severe injury to the hand, rendering amputation necessary.

Case CCCXII.—W. Foskett, aged seventy-two, was admitted into Guy's Hospital on the 5th of April, 1833, under Mr. B. Cooper, in consequence of a severe injury he had sustained by his hand being crushed between the handle and body of an iron roller on the preceding evening.

Upon examination of the injured hand, a great laceration of the soft parts on the back of the hand was found, extending obliquely across from without to within: there was also a deep laceration on the palm, but to a less extent. On closer investigation the metacarpal bones of the middle and fore fingers were found fractured about their centres, but not comminuted; the upper fractured extremities of both were drawn considerably outwards; and more especially that of the fore-finger. The metacarpal bones of the little and ring fingers were dislocated outwards and backwards; there was also a considerable hæmorrhage, which had continued more or less from the time of the accident.

I saw the patient shortly after his admission; and having ascertained the whole extent of the injury, I recommended immediate amputation; because, from the age of the patient, I considered that there could be but very slight hopes of the reparation of so severe an injury, and because I believed that the hand never could be useful again, even though the bones united, and the soft parts healed. This I explained to the patient, who immediately consented to the loss of the hand, which I removed in the following way, through the wrist-joint.

Placing the thumb and fore-finger of my left hand upon the extremities of the styloid processes of the radius and the ulna, and pronating the patient's hand, I made a convex incision on the

* It is rarely that these fractures unite without some little irregularity remaining. When the metacarpal bone of the little finger is broken, the extremities are apt to project backwards and outwards; and when this bone, or that of the fore-finger is broken, a splint, with pads and compresses to act upon the projecting extremities, may be more useful than the ball in the hand, which is described above, but which appears to be the best plan for fracture of the middle metacarpal bones.—*Ed.*

back of the wrist (with the convexity towards the fingers), beginning a little below the styloid process of the ulna, and ending at a corresponding point below the styloid process of the radius. The incision was made through the skin and cellular membrane only, not yet dividing any of the extensor tendons; the flap was then dissected back, and the extensor tendons divided at the level of the base of the flap, thus entirely preventing their protrusion. The patient's hand was then supined, and a corresponding flap made anteriorly; the flexor tendons were then divided in the same manner as the extensor; the flaps were now held back by an assistant; and grasping the patient's hand, and holding it between pronation and supination, and pressing it down towards the ulna, I divided the external lateral ligament, carried my knife across the joint, so as to divide the anterior and posterior ligaments, and by the division of the internal lateral ligament, I removed the hand.

The operation did not occupy so much time as this description of it. The arteries were secured, (the ulnar was so ossified as to crepitate when seized by the forceps,) the edges of the flaps were then brought together and secured by sutures and adhesive plaster, and a roller was applied along the whole of the fore-arm. The only precaution which I have to point out with respect to this operation, is that the first incisions ought not to be commenced directly opposite the styloid processes, as they might project in the wound, and prevent its healing.

On the following day, the patient was tolerably comfortable; but the day after there was a slight attack of erysipelas of the arm. On the 11th, when the stump was dressed for the second time, the edges of the wound looked sloughy, without any apparent attempt at adhesion. On the 13th, it looked nearly in a state of sphacelus; and on the 19th the palmar flap had entirely sloughed away, leaving a healthy, granulating surface; which, with the aid of tonics and a generous diet, soon cicatrized.

Under all circumstances, I believe that the flaps made in this operation, and especially the palmar one, must always have a great tendency to slough, in consequence of the little subcutaneous tissue which remains attached to the skin, especially in working people, from the thickness and hardness of the cuticle; hence it is advisable to make the principal part of the flap from the dorsal surface. In this particular case, the age of the patient, the

degree of contusion of the soft parts, and the ossification of his arteries, all tended to diminish the chance of reparation by adhesion.

It was curious to watch the process of granulation in this case; the cartilaginous extremity of the radius, and the under surface of the interarticular cartilage, could be seen gradually absorbing, presenting a honey-comb appearance, then softening into a pulpy mass, and alternately rising into healthy granulations; proving that the process of reparation in all structures is essentially the same; but that its progress in cartilage is slower than in softer structures, although much less so than in bone.

This process of reparation does not agree with the views of Hunter, who says that when cartilage is exposed, it does not granulate like soft parts, nor exfoliate like bone; but that granulations spring from the surrounding soft parts, and shoot over it, so as completely to cover, without adhering to it. In this case such a process could not take place, as there were not sufficient surrounding soft parts for the granulations to arise from.*

SECTION III.

DISLOCATIONS AND FRACTURES OF THE FINGERS AND TOES.

The phalanges of the fingers and of the toes are united by capsular ligaments to the metacarpal and metatarsal bones, and to each other; and their union is further strengthened by lateral ligaments, proceeding from the side of one phalanx to that of the next. Posteriorly, they are defended by the tendon of the extensor muscle of the fingers; and anteriorly, by the thecæ and flexor tendons. Dislocation of the phalanges, therefore, is but rare; but when this accident does occur, it more frequently happens between the first and second phalanges, than between the second and third.

This dislocation may be seen in the adjoining figure; the

* Surgical Essays, p. 120.

second phalanx being thrown forwards towards the thecæ; and the first, backwards. I could not learn if the ligaments had been torn, as the dislocation had existed for a length of time, and the

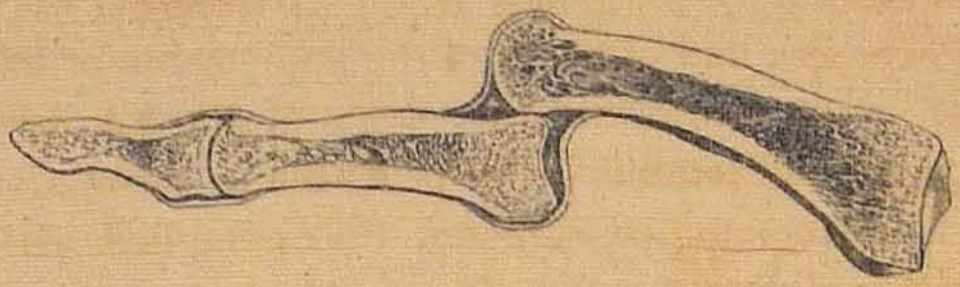

ligament, if it had ever been lacerated, was then united; the extensor tendon was very much stretched over the end of the first phalanx; and a new capsular ligament covered the head of the dislocated bone.

This accident may be readily distinguished by the projection of the first phalanx backwards, while the head of the second may be, although less distinctly, felt under the thecæ.

The reduction may be effected by making extension, with a slight inclination forwards, so as to relax the flexor muscles. If the bone has not been dislocated many hours, it is easily reduced; but if neglected at first, this can only be accomplished by a long continued extension very steadily applied. I have seen too much mischief arise from injury to the tendons and ligaments of these joints, ever to recommend the division of them (which some have advised) to facilitate reduction, when extension will not succeed. The observations which I have made respecting the dislocation of the fingers, also apply to the toes; of which, however, the dislocations are more difficult to reduce, from their greater shortness, and the less pliability of the joints.*

Dislocation from Contraction of the Tendon.—A toe is sometimes gradually thrown out of its natural direction, by a contraction of the extensor tendon and thecæ; and the first and second phalanges are, consequently, drawn up and projected against the shoe, so as to prevent the patient from being able to take his usual exercise.

I have frequently seen young ladies subject to this inconveni-

* In almost all cases of compound fracture of the last phalanx of the fingers, it is better at once to amputate than to leave the reparation of the part to nature; because, from the peculiar structures connected with it, the healing is slow and difficult, and can hardly occur without anchylosis to the second phalanx.—*Ed.*

ence in the toe, and attribute it to the tightness of their shoes; it appears an extremely harsh measure on the part of the surgeon, to amputate a toe under such circumstances; yet it is sometimes absolutely necessary, as the contraction deprives the person of exercise, and of many of the enjoyments of life. In the first person whom I saw with this state of the toe, I refused to amputate, fearful of tetanus being produced by the operation; but the lady went to another surgeon, who complied with her request, and she did very well. In consequence of the perfect recovery of this lady, and the comfort which she derived from the loss of the annoyance, I was induced, at the request of Mr. Toulmin, of Hackney, to remove from Miss T., a patient of his, one of her toes, which was constantly irritated by the pressure of her shoe in walking, and prevented her from taking the exercise necessary to the preservation of her health; she did very well, perfectly recovering the use of her foot.

The fingers are sometimes contracted in a similar manner by a chronic inflammation of the thecæ, and aponeurosis of the palm of the hand, from excessive action of the hand in the use of the hammer, the oar, ploughing, &c. &c. When the thecæ are contracted, nothing should be attempted for the patient's relief, as no operation, or other means, will succeed; but when the palmar aponeurosis is the cause of the contraction, and the contracted band is narrow, it may with advantage be divided by a pointed bistoury, introduced through a very small wound in the integument. The finger is then extended, and a splint is applied to preserve it in the straight position.

Last September twelvemonth, my nephew, Mr. Bransby Cooper, who was transacting my business during my absence from town, performed this operation for a Lincolnshire farmer, who, by this circumstance, had been prevented from following his avocations, and he perfectly recovered the use of his foot.

SECTION IV.

DISLOCATIONS OF THE THUMB.

These accidents are very difficult to reduce, on account of the numerous strong muscles which are inserted into the part.

The thumb consists of three bones; its metacarpal bone, and two phalanges. The metacarpal bone of the thumb is articulated with the os trapezium by means of a double pulley; that of the trapezium directing the thumb towards the palm of the hand, and that of the metacarpal bone directing it laterally. The metacarpal bone is connected with the trapezium by a capsular ligament; and a very strong ligament joins it to the palmar part of the trapezium, at its lower extremity. At its distal extremity this bone has a rounded projecting articulatory surface, upon which the hollow of the first phalanx rests, both being surrounded by a capsular ligament, and strengthened by two strong lateral ligaments. There are eight muscles inserted into the thumb; two into the metacarpal bone, the extensor and flexor ossis metacarpi; two into the first phalanx, the flexor brevis pollicis, and the extensor primi internodii; the abductor and adductor pollicis are also inserted into the first phalanx, through the medium of the sesamoid bones; the extensor secundi internodii and flexor longus pollicis are inserted into the second phalanx. These muscles necessarily offer great resistance to the reduction of dislocations, and therefore those of the thumb are amongst the most difficult to reduce, if any considerable time be allowed to elapse after the accident has occurred, before the attempt at reduction be made.

Dr. Penneck, of Penzance, sent a very interesting essay to the Lancet some years ago, in which he recommends another method of employing the extension, as will be evident from the following case.*

Case CCCXIII.—About forty years since, says Dr. Penneck, when an apprentice, I was sent to a young farmer residing six miles from Penzance, who was thrown from his horse whilst carrying a heavy basket. I found his left hand severely bruised, the second phalanx of his thumb dislocated on the back

* Lancet, vol. i. p. 260, New Series.

of the first, and the joint laid open by a wound in the integuments and capsular ligament. After vain attempts to make an extension, which the shortness of the part prevented, I hit on the following method, which fully answered my expectation, and which I have since practised with complete success. I took a piece of bleeding tape, and tied the middle part of it round the *first* phalanx, letting it cover a part of the end of the dislocated bone, and having the knot on the opposite side; I twisted both parts round my hand, and directing an assistant to support the patient's hand and fix the thumb, I made extension, and found the dislocated phalanx slip readily into its place, when the tape slipped off, and the operation was completed. I dressed the part superficially, and it soon healed. I do not recollect the after treatment, but the patient recovered with a useful joint, although it is rather stiff. This method of using the tape appears to me far better than pressing on the dislocated bone by the fingers, or bending it by the thumb, because, by the tape, the force is always applied in the right direction, and it carries the displaced bone straight on, clear of the first phalanx; besides, it never distresses the joint by making a greater extension than is required to pass the bone into its proper place; whereas the common method of bending forcibly the dislocated bone over the first phalanx as its fulcrum, compels the dislocated bone to make a large sweep, and puts the capsular ligament greatly on the stretch; and in the case of a compound dislocation, such as I have described, might have increased the rent in the capsular ligament, and rendered amputation necessary.

Dr. Penneck gives three other cases illustrative of the efficiency of this practice.

Dislocation of the Metacarpal Bone from the Trapezium.*—In the cases which I have seen of this accident, the

* It is quite unanatomical to consider the first bone of the thumb as a metacarpal bone, as in every respect it resembles a phalanx. The muscles which are inserted into it move the thumb upon the os trapezium instead of the wrist-joint, as all the muscles inserted into the metacarpus are destined to do, and the very distribution of the blood-vessels to the thumb is similar in arrangement to the blood-vessels of the phalanges; so that, whether anatomically or physiologically considered, it must be maintained that the thumb is devoid of a metacarpal bone. The very circumstance of the dislocation of this bone occurring, is a further proof of the propriety of its being considered as a phalanx rather than as one of the metacarpal bones, which are scarcely obnoxious to this accident.—*Ed.*

metacarpal bone has been thrown inwards, between the trapezium, and the root of the metacarpal bone supporting the fore-finger; it forms a protuberance towards the palm of the hand; the thumb is bent backwards, and cannot be brought towards the little finger. Considerable pain, with swelling, is produced by this accident.

Treatment.—For the facility of reduction, as the flexor muscles are much stronger than the extensors, it is best to incline the thumb towards the palm of the hand during extension, and thus the flexors become relaxed, and their resistance diminished. The extension must be steadily, and for a considerable time, supported, as no sudden violence will effect the reduction. If the bone cannot be reduced by simple extension, it is best to leave the case to the degree of recovery which nature will in time produce, rather than divide the muscles, or run any risk of injuring the nerves and blood-vessels.

This bone is sometimes dislocated by the bursting of a gun, which produces compound luxation; it can usually, in these cases, be easily returned to its natural situation. When the integuments have been brought and confined over it by suture, a poultice is to be applied; and, under common circumstances, where the degree of bruise has not been very considerable, a cure is perfected. Sometimes, however, the metacarpal bone becomes so much detached from the trapezium, and the muscles are so severely torn, that it is necessary to remove the thumb, in which case it is best to saw off also the articular surface of the trapezium.

Case CCCXIV. — Such a case happened lately to a servant of Mr. Grover, of Hemel Hempstead: the metacarpal bone of the thumb was dislocated, and the muscles were so lacerated, that it became necessary to remove the thumb at the os trapezium; but the articular surface of the trapezium projected so far that the integuments could not be brought over it: I therefore directed this surface to be sawn off, through the os trapezium; and a poultice being applied, the man recovered by the granulating process.

The next case of this accident was sent to me in 1820, by my friend Mr. George Cooper, of Brentford.

Case CCCXV.—Master Arthur Trimmer, aged thirteen years, on the 2nd of February 1819, whilst a wild-fire was gradually

consuming, was in the act of adding, from a copper flask, dry powder, of which it contained about half a pound, when an explosion took place, and the flask bursting in his hand, caused severe laceration of the palm, and a compound dislocation of the thumb. The whole mass of muscle connecting the thumb with the hand was completely torn through; and observing the thumb lying upon the carpus, dislocated from its articulation with the trapezium, I was about to have removed it with a scalpel, when I saw the tendon of the flexor longus pollicis glisten in its sheath, uninjured, as well as the tendon of the extensor longus; I therefore put the parts in something like a natural position, and took ten minutes to reflect upon the best mode of proceeding. The hæmorrhage was great at the moment, but the wound being contused and lacerated, it ceased on slight pressure.

Considering the thumb of the right hand to be a very important organ, I resolved, if possible, that it should be preserved, assuring the friends of the young gentleman, who were under great apprehension lest tetanus should ensue, that the probability of it would not be increased by the attempt to save the thumb.

Sir Benjamin Brodie, having been also sent for at the time of the accident, arrived in about three hours, and being of opinion with myself that there was a chance of saving the limb, I brought the parts together with three ligatures, two towards the palm, and one on the posterior part of the hand, put on adhesive straps, allowing sufficient room for swelling, and applied an evaporating lotion to the hand and fore-arm. I gave him at bed-time a pill containing three grains of calomel and one of opium, and in the morning a cathartic mixture.

February 3rd. The patient had a restless night, but the part has not been very painful.

February 4th. His pulse running 120 and hard, I took away about eight ounces of blood, and ordered him the effervescing mixture, paying attention to the state of his bowels. Continued the antiphlogistic plan.

February 7th. I removed the dressings and ligatures, and had the pleasure to find that considerable adhesion had taken place, that no tetanic symptoms made their appearance, and that every day he suffered less from constitutional irritation.

February 9th. I again removed the dressings; the wound was looking healthy, and suppuration was not considerable: I therefore

continued to dress with adhesive plaster, and small quantities of lint, and over that a bandage about an inch wide and two yards long, by means of which sufficiently equable pressure could be made to promote the inosculation of granulating surfaces, as well as to produce a tolerably even external state of the parts during the advance of the adhesive process.

From this time it was dressed every second day, and on the 16th I began to give it passive motion, at first by simply bending the first phalanx of the thumb, so as to break down any adhesions that might have taken place between the tendons and their thecæ. By the 23rd I gave trifling motion to the second phalanx, and towards the end of the month the wound was healed. Through the month of March I gradually increased the motion, and on the 1st of April, my little patient left Brentford on a visit to the Isle of Wight, with injunctions to give daily motion to the joint; and I am happy to add, he now makes use of it in writing as well as ever, and finds the thumb perfectly useful for all the ordinary purposes of life.

DISLOCATION OF THE FIRST PHALANX.

This may be either simple or compound. I shall first describe the simple dislocation. In this accident the first phalanx is thrown back upon the metacarpal bone, and the lower extremity of the latter projects very much inward towards the palm of the hand, and the extremity of the phalanx projects backwards. The motion of that joint is lost, but that of the thumb, through the medium of the metacarpal bone and trapezium, remains free; so that, as an opponent to the fingers, its power of action continues; but with respect to flexion and extension, which are performed between the metacarpal bone and the first phalanx, they are destroyed by the dislocation.

Treatment. — The extension is to be made by bending the thumb towards the palm of the hand, to relax the flexor muscles

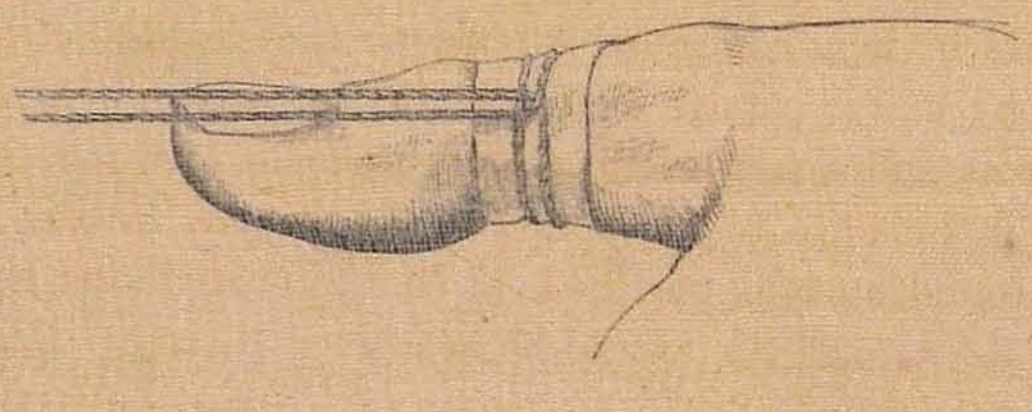

as much as possible; and the following is the mode of applying the extending force, which may be considered as the general mode to be adopted in dislocations of the toes, thumb, and fingers. The hand is to be first steeped in warm water for a considerable time, to relax the parts as much as possible; then a piece of thin wetted leather, wash-leather for instance, is to be put around the first phalanx, and as closely adapted to the thumb as possible; a portion of tape about two yards in length is then to be applied upon the surface of the leather, in the knot which is called by the sailors the *clove hitch*, for this becomes tighter as the extension proceeds. An assistant places his middle and fore-finger between the thumb and fore-finger of the patient, and makes the counter-extension, whilst the surgeon, assisted by others, draws the first phalanx from the metacarpal bone, directing it a little inward towards the palm of the hand.

The extension should be supported for a considerable length of time, and if success does not attend the surgeon's efforts, it is right to adopt the following plan. The leather and sailors' knot are to be applied as before directed, and a strong worsted tape is to be carried between the metacarpal bone of the thumb and the fore-finger; the arm is then to be bent around a bed-post, and the worsted tape fixed to it; a pulley is then to be hooked to the tape which surrounds the first phalanx, and extension is to be made: this mode is almost sure to succeed. If, however, under the steadiest, best directed, and most persevering attention, the bone be not reduced, a disappointment which will sometimes happen in dislocations which have been neglected, then the surgeon's efforts must cease; no operation for the division of parts should be made, as the patient will have a very useful thumb after a time, even without reduction.

In compound dislocations of the first phalanx of the thumb, if there be much difficulty in its reduction, and the wound be large, it is best to saw off the extremity of the bone, rather than to bruise the parts by long continued extension: they are to be healed by adhesion; and if passive motion be begun early, a joint will soon be formed, and a very useful member remain. In this case, lint, dipped in blood, is to be applied to the wound; a roller must be bound round, and the part be kept cool by evaporating lotions for several days, until the wound be healed.

I very recently saw the following case of compound dislocation of this bone.

Case CCCXVI.—A gentleman came to my house, whose first phalanx had been thrown upon the back of the metacarpal bone of the thumb by the bursting of a gun. The flexor muscles, and the abductor, were much lacerated just below the os trapezium; the extensors were uninjured. I applied the tape to the first phalanx, and extending, easily reduced it; I then brought the edges of the integuments together by suture, and directed a poultice to be applied, on account of the great contusion of the parts: and the recovery was very complete.

DISLOCATION OF THE LAST PHALANX OF THE THUMB.

If this be a simple dislocation the best mode of reducing it is, that the surgeon should grasp the back of the first phalanx with his fingers, apply his thumb upon the fore part of the dislocated phalanx, and then bend it upon the first as much as he possibly can.

In compound dislocations of this joint (of which I have given a plate), it is best to saw off the extremity of the second phalanx,

taking care not to injure the tendon which is torn through; for when the bone is removed, the ends of the tendon may be readily approximated, and adapted to each other. The extremity of the tendon should be smoothed by a knife, and the part be then bound up in lint, dipped in blood, and confined by a roller; and it should be kept quiet for a fortnight or three weeks, when passive motion may be begun.

The three following cases which occurred in the Editor's practice will illustrate the efficacy of the rules laid down.

Case CCCXVII.—In June, 1833, a gentleman called at my house to consult me, who, the evening before, had been thrown down from placing his foot upon a piece of orange-peel; he fell

to the ground with great violence, and immediately upon the inferior part of his right thumb, which forced the superior extremity of the last phalanx upon the dorsal surface of the second; the extreme phalanx was permanently extended, deviating from the position of the first or second, when either of them are dislocated in that direction, in consequence of the shortness of this bone, when dislocated, not admitting of its being acted upon by the flexor tendon. The great deformity was produced by the inferior extremity of the second phalanx, which formed a very considerable projection upon the palmar surface of the thumb, while a deep cleft was observed on the corresponding dorsal surface. I fixed a broad piece of tape by the clove hitch on the luxated bone, and assisted by my apprentice, Mr. J. H. Roberts, made extension for about three minutes, when it slipped into its place. I must confess I was surprised at the facility with which the reduction was effected, considering the smallness of the bone dislocated, the difficulty of application of an extending force, and the powerful muscles in opposition.

Case CCCXVIII. — Colonel C., in jumping out of one of the open cabs, caught the end of his thumb in the iron rail, which prevented his liberating his hand as he jumped from the step upon the pavement. Being a very short man, he became almost wholly suspended by the last phalanx of his thumb, which was immediately dislocated, its superior extremity being thrown upon the dorsal surface of the second phalanx. The accident had happened sixteen hours previously to his consulting me; however, forming the clove hitch upon a piece of tape, without any previous preparation, I, in a few minutes, succeeded in restoring the displaced bone to its natural situation.

Case CCCXIX. — Patrick Sweeny, aged fifty-one, came to Guy's Hospital in February last, in consequence of an injury he had sustained to the thumb of the right hand, occasioned by the fall of a large stone upon the dorsal surface of the last phalanx.

Upon examination it was found to be a compound dislocation, the base or superior extremity being thrown forwards upon the palmar surface of the second phalanx; it was immediately reduced by making extension, at the same time pressing forcibly upon the base of the dislocated bone. The facility of its reduction depended upon the extensive laceration of the ligaments; splints were placed upon the thumb, saline purgatives adminis-

tered, and the patient was desired to keep his hand in a perfect state of rest. On the following day he complained of little or no pain, and everything seemed to be going on well; but three days after, an erysipelatous blush appeared on the hand, which it was in vain to attempt to check, and it extended up the arm, causing so much constitutional irritation as to render it necessary to take the man into the hospital. As all the usual means still failed in checking the progress of this disease, it clearly indicated the necessity of doing everything most likely to alleviate the local cause of these urgent symptoms. The splints were therefore removed from the thumb and a large poultice applied: the benefit of this treatment became immediately obvious, and after poulticing for a short time, the last phalanx sloughed away, and the inferior extremity of the second exfoliated; the wound ultimately granulated, and the patient left the hospital in about a month quite well.

CHAPTER XVII.

ON DISLOCATION OF THE RIBS.

Authors describe different species of dislocations of the ribs; for instance, it is said that their heads may be thrown from their articulation with the vertebræ forwards upon the spine; but this accident is certainly extremely rare, and must be very difficult of detection in the living subject.

A person, by falling on his back upon some pointed body, may, however, receive a blow upon his ribs, by which they may be driven from their articulations.

Such an injury would produce the usual symptoms of fracture of these bones; their motions would be painful, and respiration necessarily difficult.

The treatment which would be required would also be the same as that which is pursued in fracture of the ribs, viz., the abstraction of blood, and the application of a circular bandage; the former to prevent inflammation of the pleura and lungs; the latter to lessen the motion of the ribs. Any attempt made to effect their reduction would be entirely fruitless.

Case CCCXX. — Mr. Webster, surgeon at St. Albans, when examining the body of a patient, who had died of fever, found the head of the seventh rib thrown upon the front part of the corresponding vertebra, and there anchylosed. Upon inquiry, Mr. Webster learned that this gentleman, several years before, had been thrown from his horse across a gate, for which accident he had been subjected to the treatment usually followed in fractures of the ribs, and there is every reason to believe that it was at this time that the dislocation occurred.

The cartilages connecting the ribs with the sternum are frequently supposed to be dislocated from the extremities of the ribs, and sometimes from the sternum. Mothers, for instance, have several times brought their children to me, saying, "My child has some time since had a fall, and see how the form of its

breast is altered." The sixth, seventh, and eighth cartilages of the ribs are most frequently the subjects of this alteration of form; and when the ribs are carefully examined, it is found that their natural arch is diminished, their sides flattened, and, consequently, the extremities of the ribs, with their cartilages, thrust forward; but the appearance which is thus produced is a common result of constitutional weakness, and not of the accident to which it is attributed.

The termination of the cartilages at the sternum sometimes projects from a similar cause, giving rise to the same false impression upon the minds of the parents, that the circumstance must have arisen from accident, and not from disease.

Sometimes, however, but very rarely, it happens that a cartilage is torn from the extremity of the rib, and projects over its surface. In this case the same treatment is required as in fracture of the ribs. The patient is to be directed to make a deep inspiration, and then the projecting cartilage is to be pressed into its natural situation; a long piece of wetted paste-board should be placed in the course of three of the ribs and their cartilages, the injured rib being in the centre; this dries upon the chest, takes the exact form of the parts, prevents motion, and affords the same support as a splint upon a fractured limb. A flannel roller is to be applied over this splint, and a system of depletion pursued, to prevent inflammation of the thoracic viscera.

Case CCCXXI.—A baker's boy applied for relief at Guy's Hospital, who was the subject of displacement of the cartilages of the fifth and sixth ribs from their junction with the sternum, produced partly by the constant action of the pectoral muscles in kneading bread, but principally by his defective constitution. Mr. B. Cooper stated to the boy the necessity of changing his occupation in life, and recommended him to seek some employment in the country, and ordered him some tonic medicine. As, however, he was obliged to continue in his situation, little hope could be entertained of his recovery.

CHAPTER XVIII.

ON INJURIES OF THE SPINE.

SECTION I.—ANATOMY OF THE SPINE.

I WILL commence this chapter, as usual, with a short account of the structure of the spinal column, merely to revive ideas which may have faded from the memory.

I need scarcely observe, by way of commencement, that this column is constituted of twenty-four bones, called vertebræ, each composed of a body of spongy texture in front, and of an arch behind; that by means of their articular processes, ligaments, and muscles, these bones are united into a column, in which great strength and great capability for motion are combined; and that they are divided into three classes,—the cervical, dorsal, and lumbar; of which, the cervical and lumbar are formed and articulated so as to enjoy considerable flexibility, whilst the dorsal are comparatively fixed.

The bodies of the vertebræ, from the second cervical to the last, are united by means of thick elastic layers of a substance called the *intervertebral fibro-cartilage*, which is composed of concentric lamellæ of cartilage, connected by oblique fibres which decussate each other; the superficial set of which are sometimes called the *intervertebral ligaments*. The centre of this substance is soft, so as to form a pivot, which supports the central line of the vertebræ; whilst the elasticity and compressibility of the outer edge of this uniting medium, allows the vertebræ between which it is interposed to move upon its centre in all directions.

The column formed by the bodies of the vertebræ is also further connected by an anterior spinal ligament, which proceeds from the second vertebra of the neck to the sacrum, and is united to all the bodies of the vertebræ excepting the first. There is also a posterior spinal ligament, situated within the canal of the spinal column; it proceeds from the second cervical vertebra,

where it is continuous with the perpendicular ligament of the axis, and descends to the sacrum, sending out lateral processes to the superior and inferior edges of the bodies of the vertebræ. Both the anterior and posterior spinal ligaments are much more intimately connected with the intervertebral substance than with the bodies of the vertebræ; in fact, the posterior spinal ligament has a very slight connexion with the bones, being separated from them by the large veins which emerge from the canals on the posterior surfaces of the bodies of the vertebræ.

The articular processes are covered with cartilage and united by capsular ligaments.

The transverse processes of the dorsal vertebræ have ligaments passing from the one to the other, called *intertransverse*, but they are very thin and slight; the transverse processes of the cervical, and sometimes of the lumbar, are united by muscles.

The arches of the vertebræ are united by layers of an elastic ligament, called the *ligamentum subflavum*, which allows of considerable separation of the spinous processes; and thus rendering muscular support for the erect position of the body less necessary, by its elasticity again approximating them.

The vertebræ of the neck are united at their spinous processes by an elastic ligamentous substance, which is termed the *ligamentum nuchæ*: the spinous processes of the other vertebræ are connected by a rounded cord, called the *supra-spinous* ligament, which extends from the prominent spinous process of the seventh cervical vertebra to the sacrum.

Besides the above ligaments, which are common to all the vertebræ, there is a peculiar and more complicated set which connect the two first cervical vertebræ to the occiput.

The occiput is united to the atlas, first, by a *circular ligament*, which extends from the edge of the foramen magnum to the upper margin of the ring of the atlas both before and behind the condyles; secondly, by *capsular ligaments*, which articulate the condyles of the occiput to the corresponding processes of the atlas; and thirdly, by a rounded cord called the *anterior occipito-atlantal* ligament, which passes from a tubercle on the under surface of the basilar process of the occiput to the tubercle in the centre of the anterior arch of the atlas.

Within the circle of the atlas is a *transverse ligament*, dividing it into two rings; the posterior of which transmits the spinal cord,

the anterior being that in which the head rotates on the odontoid process of the axis. This transverse ligament is united to the occiput above, and to the axis below, by a *perpendicular ligament*, which is given off from the dura mater at the edge of the foramen magnum, and which having mingled itself with the transverse ligament, becomes continuous with the posterior common vertebral ligament at its commencement on the body of the axis.

It will be readily understood that this perpendicular ligament, which descends from the occiput, and the transverse ligament of the atlas, cross each other at right angles; whence they are sometimes described together as the *crucial ligament of the axis.*

The odontoid process is connected with the occiput by means of two ligaments which proceed from both sides of its apex, and are inserted into the inner sides of the condyles. The ligaments which connect the axis with the atlas require no particular notice, as they do not differ from those of the other vertebræ, excepting, of course, the articulation of the odontoid process of the former with the ring of the latter.

Thus the spinal column, from the two important purposes which it serves, namely, from its supporting the head and all that part of the body situated above the pelvis, and also from its containing and protecting the spinal marrow, upon which the voluntary motion and sensation of the extremities depend, is most carefully protected from external injury, by the number of its bones, and the strength of its joints, whilst its connexion with the bones of the chest adds materially to its stability.

The effects which are produced by violence done to the spinal chord, are very similar to those which are produced by injuries to the brain; for example:—

Concussion.

Extravasation.

Fracture.

Fracture with depression.

Suppuration and ulceration.

It has been generally stated by surgeons that dislocations of the spinal column frequently occur; but if luxation of the spine ever does happen, it is extremely rare; as in the numerous instances which I have seen of violence done to the spine, I have never witnessed a separation of one vertebra from another through the intervertebral substance, without fracture of the articular

processes; or, if those processes remain unbroken, without a fracture through the bodies of the vertebræ. Still I would not be understood to deny the possibility of dislocation of the cervical vertebræ, as their articular processes are placed more obliquely than those of the other vertebræ. I must, however, observe, that from the vicinity of our hospitals to the river, sailors are often brought into them with injuries of the spine, by falls from the yard-arm to the deck; and as there is almost always an opportunity of inspection in these cases, a dislocation must be extremely rare, since I have never met with a single instance of it, those injuries having all proved to be fractures with displacement.

I am well aware that respectable surgeons have described dislocations as occurring in the cervical vertebræ, but I wish to state my own experience, with no further reference to that of others.*

SECTION II.

CONCUSSION OF THE SPINAL MARROW.

When a person receives a very severe blow upon the spine, or from any great force has it very suddenly bent, a paralysis of the parts beneath will frequently succeed, in a degree proportionable to the violence of the injury; although, after such an effect, the person, in general, gradually recovers the motion and sensation of the parts. This accident will be exemplified by the following cases.

Case CCCXXII. — A man was admitted into Guy's Hospital under the care of Dr. Curry, who had received a severe blow from a piece of wood, which fell upon his loins, and knocked him down; and as he came to the hospital on the regular day of admission, and not immediately after he had received the injury, he was placed amongst the physicians' patients. His lower extremities were in a great degree deprived of motion, and their sensibility was much diminished. When resting upon his back in bed he could slightly draw up his legs, but could not bend them to a right angle with the thigh; and a considerable time

* See the note at p. 13.—*Ed.*

elapsed before he could make the muscles of the lower extremities obey the effort of his will. As there was still the appearance of severe contusion, and much deep-seated tenderness in the situation of the blow upon the loins, Dr. Curry ordered blood to be repeatedly drawn away by cupping, and the bowels to be acted upon by calomel; and when the pain and tenderness, in consequence of the contusion, had been removed, a blister was applied to the loins, and a discharge supported for three weeks by the application of the unguentum sabinæ. The linimentum ammoniæ was ordered to be rubbed daily upon the lower extremities. In six weeks the motion and sensation of his legs had almost entirely returned, and he was then directed to be submitted to the influence of electricity. By this treatment, in ten weeks he completely recovered.

Case CCCXXIII. — I attended a gentleman, who, by a fall from his gig, had received a severe blow upon his loins, and who had, at first, great difficulty in discharging both his urine and fæces, but he was relieved by fomentation and cupping.

The two next instructive cases are taken from Mr. Mayo's Outlines of Pathology.

Case CCCXXIV. — A man, aged fifty, was admitted into the Middlesex Hospital, after having fallen out of a loft, and pitched on the junction of his back with the neck. He did not lose his senses, but on being lifted up, his arm and feet were found to be numb and powerless. In a few days he recovered the feeling and use of his legs; the numbness and weakness likewise gradually left the arms; but his hands remained affected, and continue so still. The hands are numb and weak; the thumbs and fingers are drawn inwards, and incapable of complete extension. The treatment employed was cupping, blistering on the neck, and calomel. About six months after the accident, strychnine was employed, but without benefit.

Case CCCXXV. — James Jacob, aged thirty-nine, was admitted into the Middlesex Hospital, in May, 1835. On the 1st of March he was standing at the top of a flight of seventeen stone steps, when on turning suddenly to speak to some one, he slipped and fell backwards to the bottom. He was stunned by the fall, but knows that he pitched upon the upper part of his back, because his coat was cut through at this part, and his back and shoulders were much bruised. He was lifted up, and soon re-

covered, and walked to his room. No symptoms supervened for a month during which he recovered from the bruise, and lived as heartily as before the accident. He was then without any warning seized with spasm of the left foot and hand, which went off in a few minutes, but the hand and arm remained weak and numb. This was attended with pain of the back part of the head, and occasional confusion of thought, and aching and shooting pains between the shoulders; he had also frequent desire to make water, which came on suddenly with great urgency. He continued in this state a fortnight, when he had twitchings in the arm and leg, and gradually recovered the use, first, of the arm, and then of the leg. A fortnight after the restoration of the left side, the right arm and leg were affected just as the left had been. This again got better. At the time of, and for six weeks after his admission, he was liable to spasmodic seizures of the hands and feet, which lasted a few minutes; the pulse during these seizures was frequent and feeble; the skin cold and inclined to rigor; his limbs were weak, and he had pain at the back of the head, and occasional confusion of thought. On striking the upper dorsal vertebræ, an obscure and deep-seated pain was felt in the part. He has now (August 7th) been entirely free from symptoms for several weeks. He has remained in the hospital; has been cupped upon the back; issues have been applied over the part which was struck; and for six weeks, the mouth was kept slightly affected with mercury.

This case presented, as Mr. Mayo observes, threatenings of inflammatory softening of the spinal cord.

The next case, which is quoted from Boyer, gives an example of concussion, which proved fatal, without leaving any lesion that could be detected after death.

Case CCCXXVI. — "A hosier fell into a shallow ditch on his loins; the concussion was sufficient to paralyse the lower extremities. His death soon followed; but no disorganization nor effusion could be found on examination either in the skull or vertebral canal."

Case CCCXXVII. — "A builder," says Boyer, "fell from a height of fourteen feet, and remained for some time senseless; and on recovering from that situation found that he had lost the use of his lower extremities. He had also retention of urine, involuntary discharge of fæces, and some difficulty of respiration,

Death occurred on the twelfth day after the accident; the body was opened, and the vertebral canal was found to contain a sanguineous serum, the quantity of which was sufficient to fill a little more than its lower half."*

Case CCCXXVIII.—A man, æt. forty-six, was brought into the Hôtel Dieu at Angers, on Oct. 17th, 1817. He had fallen on his back, where he complained of great pain, and his legs were palsied. He lingered till the 3rd of November, and then died; after having experienced great difficulty of breathing for some days.

On examination after death the bones were found not to be fractured. On opening the spinal canal with care, there were found two lacerations of the sheath of the cord opposite to the fourth and fifth dorsal vertebræ; each laceration was longitudinal, and almost an inch long, and directly in the middle of the cord behind. Through each of them a portion of the medullary matter of the cord had exuded, forming a patch about two or three lines in thickness, and of the size of a *sou* piece.†

The next case seems to be one in which the sheath of the spinal cord was implicated in inflammation which commenced in the ligamentous structures of the spine.

Case CCCXXIX.—"A man," says Boyer, "exercising himself at feats of activity, distended so much the intervertebral ligaments, by the strained posture which he assumed, that he was instantly seized with acute pain in the part so distended. The next day, the legs, the bladder, and rectum were palsied, and the patient died in a few weeks."

* The above cases furnish a sufficient illustration of the causes, nature, and consequences of concussion of the spinal marrow. They show that violent blows, without producing any effects on the spinal cord which can be detected by dissection, yet may be sufficient to annihilate its functions, as though it were compressed or lacerated; they show that such injuries, although they may produce no ill results at the time, yet, like similar injuries of the head, require great care in order to prevent future ill results; and they also show the treatment necessary to avert and remove these ill consequences.—*Ed.*

† This case is an example of concussion, producing palpable lesion. It may be presumed that most cases of concussion are attended with some injury to structure, although in most instances so minute as to escape detection by our means of examination. The case is quoted from Ollivier's work, p. 425.

SECTION III.

EXTRAVASATION INTO THE SPINAL CANAL.

A very severe blow upon the vertebræ will sometimes produce extravasation upon the spinal cord, but more frequently upon the sheath in which it is contained. Of late years it has been our custom, in examining dead bodies, to saw off the spinous processes of the vertebræ, in order the more accurately to examine the spinal marrow; and under such circumstances, in cases of severe injury, blood has been several times found on the outer side of the spinal sheath; and, in one instance, it occurred upon the spinal marrow, just above the cauda equina.

The case which best illustrates this subject is one which I visited with Dr. Baillie and Mr. Heaviside, the particulars of which I have obtained from Mr. Heaviside, whom I have ever found ready to make his beautiful anatomical collection useful to the profession.

Case CCCXXX. — Master ——, a fine youth, aged twelve years, in June, 1814, was swinging in a heavy wooden swing, and in just commencing the motion forward, was caught by a line which had got under his chin, by which accident his head and the whole of the cervical vertebræ were violently strained; as, however, the line slipt immediately off, he thought no more of it. Subsequently to the accident, for some months, he was not aware of any pain or inconvenience, but his school-fellows observed that he was less active than usual: instead of filling up his time by play, he would be lying on the school forms, or leaning on a stile or gate when in the fields. They were always teasing him on this account; and at last he was persuaded that he was weaker than he used to be. From this time he continued to decline both in strength and power. About the middle of May following he came to London. His complaints were occasional pains in the head, which were more severe and frequent about the back of his neck (where a blister had been applied without relief) and down his back. The muscles at the back of the head and neck were stiff, indurated, and very

tender to external pressure. He felt pain in moving his head or neck in any direction; added to these symptoms, there was a great deficiency in the voluntary powers of motion, especially in the limbs.

May 18th. Two setons were made in the neck, and he was ordered various medicines, none of which proved useful.

May 29th. His complaints and the paralytic affection of his limbs were getting much worse, added to which he felt a most vehement, hot, burning pain in the small of his back. This, by the next day, was succeeded by a sense of extreme coldness in the same part. Some time after the same pain occurred higher up in the back, and then disappeared. Pulse and heat natural.

June 3rd. A consultation of Dr. Baillie, Dr. Pemberton, Mr. A. Cooper, and Mr. Heaviside, was held, and the administration of mercury was determined on. The pil. hydr. was taken for a few days, but as it ran off by the bowels, mercurial frictions were consequently preferred. He felt his limbs getting every day weaker, but his neck was more free from pain when moved, and he was more capable of moving it by his own natural efforts.

June 7th. His respiration became laborious; he passed a bad night; on the following day all his symptoms increased, and at five in the afternoon he expired.

Dissection.—The whole contents of the head were carefully examined and found perfectly healthy; but upon sawing out the posterior parts of the cervical vertebræ, the theca vertebralis was found overflowing with blood, which was effused between the theca and the enclosing canals of bone. The dissection being further prosecuted, this effusion was found to extend from the first vertebra of the neck to the second vertebra of the back, both included.

The preparation only shows a small proportion of the effused blood which had become coagulated on the theca, as much of it, being fluid, escaped in the act of removal.*

* This valuable case presents a striking analogy with those in which blood is slowly effused on the brain after a blow, which, perhaps, caused no ill symptoms at first. Hæmorrhage into the spinal sheath, or spinal apoplexy as it is called, sometimes also occurs as an idiopathic disease.—*Ed.*

SECTION IV.

FRACTURES OF THE SPINE.

These are very serious accidents, but their importance depends upon the degree of injury to the spinal cord with which they are attended; for if it happens that the bones are fractured without injury to the spinal cord, the consequences may be very trivial; whilst, if the injury causes the bones to be displaced, and to compress or lacerate the cord, or, if it be attended with violent concussion of the cord, even although the bones retain their natural position, a most serious train of symptoms will ensue, which generally terminates in death.

FRACTURES WITHOUT INJURY TO THE CORD.

I will first give instances of fractures without serious injury to the cord; and the most trivial of these are, perhaps, fractures of the spinous processes, portions of which are sometimes broken off, but these accidents do not usually affect the spinal marrow unless when attended with considerable concussion.

Case CCCXXXI.—Mr. Aston Key, in dissecting a subject at St. Thomas's Hospital, found a spinous process loose, which he kindly brought to me, with the following account:—"The fractured vertebra was the third dorsal: the cause of the accident I could not ascertain, as it occurred in a subject brought into the dissecting room. There was a complete articulation formed between the broken surfaces, which had become covered with a thin layer of cartilage. The synovial membrane and capsular ligaments resembled those of other joints, excepting that the former was more vascular. The fluid within the joint had the lubricating feel characterizing synovia."

The following is another case of this accident.

Case CCCXXXII.—A boy was admitted into Guy's Hospital, who had been endeavouring to support a heavy wheel by putting his head between the spokes, and receiving its weight upon his shoulders. The wheel overbalanced him, and he fell, bent double. When he was brought into Guy's Hospital, although he

had been perfectly straight before, he had the appearance of one who had long suffered from distorted spine; yet this injury had not produced paralysis of the lower extremities. Three or four of the spinous processes had been broken off, and the muscles torn on one side, so as to give an obliquity to the situations of the fractured portions. This boy quickly recovered without any particular attention, and was discharged with the free use of his body and limbs, but he still remained deformed.

At the time when I lived with Mr. Cline, as his apprentice, the following case occurred in his practice, the particulars of which I cite from his account.

CASE CCCXXXIII.—A boy, about three years of age, from a severe fall, injured his neck; and the following symptoms succeeding the accident, Mr. Cline was consulted.

He was obliged to walk carefully upright, as persons do when carrying a weight on the head; and when he wished to examine any object beneath him, he supported his chin upon his hands and gradually lowered his head, to enable him to direct his eyes downwards; but if the object was above him, he placed both his hands upon the back of his head, and very gradually raised it until his eyes caught the point he wished to see.

If, in playing with other children, they ran against him, it produced a shock which caused great pain, and he was obliged to support his chin with his hand, and to go immediately to a table, upon which he placed his elbows, and he remained thus supporting his head a considerable time, until the effects of concussion had ceased. He died about twelve months after the accident; and upon the inspection of his body, which was conducted by Mr. Cline, the first vertebra of the neck was found broken across, so that the dentiform process of the second vertebra had so far lost its support, that, under different inclinations of the head, it required great care to prevent the spinal marrow from being compressed by it; and as the patient could not depend upon the action of the muscles of the neck, he therefore used his hands to support the head during changes of position.

CASE CCCXXXIV.—W. Cross,* an agricultural labourer, in the summer of 1827, slipped from a hayrick, and fell, head foremost, to the ground, pitching upon the occiput. He was stunned

* This case is taken from a paper published by Mr. B. Phillips in the Medico-Chirurgical Transactions.

by the fall, but was soon able to walk half a mile to the parish surgeon, who bled and purged him.

On the following day, he felt scarcely any inconvenience from the accident, and in two days more he went about his usual business.

From the day succeeding the accident he felt what is called a *stiff neck;* in fact, he was unable to turn his head. This was all that he complained of when Mr. Phillips first saw him, which was nearly a month from the occurrence of the accident, and on that day he had walked two miles.

He was a powerful, scrofulous-looking man, aged 32, and said that his health had been usually good.

On examination, a small tumor was perceptible immediately over the second cervical vertebra, pressure upon which occasioned only a very little pain; there was a slight degree of uneasiness about the back of the neck; there was a complete inability to roll the head; and, on a subsequent examination, a slight projection, or fulness, was discernible at the back of the pharynx, as nearly as possible at the level of the body of the second cervical vertebra; but there were no other morbid symptoms either of sensation or motion.

Mr. Phillips conceived the case to be a chronic scrofulous inflammation of the first or second vertebræ, or both; and that the articulating surfaces between them had been so modified as to threaten anchylosis. The case was, therefore, treated by leeches and caustic issues, and the patient was confined to the recumbent posture.

Some weeks afterwards, a violent attack of pleurisy came on; and, after that, a general dropsy, of which the patient died, about the forty-seventh week from the date of the injury.

On examination, after death, it was found that the atlas had been fractured and divided into two portions. The anterior portion, which included the anterior arch, and the surfaces for articulation with the occiput and with the axis, had been separated from the posterior portion of its ring, and had been carried obliquely downwards and forwards, until it arrived at the same plane with the axis, but anterior to it; and it was attached to the body and transverse processes of the axis by perfect bony union. The posterior fragment of the atlas, consisting of its laminæ, remained in its proper situation. The odontoid process of the axis was broken off.

The impetus of the blow which the patient received, evidently passed downwards and forwards from the upper and back part of the occiput, through the articulation of the occiput with the atlas, which latter bone it divided into two parts, as we have seen, and drove the anterior portion forwards. But in order that this anterior portion should move forwards, one of two things was necessary,—either the odontoid process must be fractured, or the transverse ligament ruptured. The former accident happened, luckily, for the patient; for if the ligament had been torn through instead, the process would, most probably, have compressed the spinal cord, and have caused suffocation immediately.*

FRACTURE WITH INJURY TO THE SPINAL CORD.

But I pass on to the consideration of those cases of fracture which far more frequently come under the surgeon's observation, in which the fracture is attended with serious injury to the spinal cord from laceration, compression, bruising, or concussion, or from subsequent inflammation and softening. And as the symptoms and result of these accidents differ according to the situation of the fractured bones, they may be divided into two classes: first, those which occur above the third cervical vertebra; and, secondly, those which occur below that bone.

In the first class, the accident is almost always immediately fatal, if the displacement be to the usual extent. Death, in the second class, occurs at various periods after the injury. The origin of the phrenic nerve, from the third and fourth cervical pair, is the reason of this difference; for as the parts below are paralysed by the pressure upon the spinal cord, the phrenic nerve, if the accident be below the fourth cervical vertebra, retains

* Several cases are described, especially by continental surgeons, of partial luxation of the cervical vertebræ. In some instances it is said that the parts have been replaced by extension and manipulation; whilst in one case it happened that sudden death was the consequence of an attempt at reduction. The following may be an example of the accident.

Case CCCXXXV.—A lawyer, writing at his desk, says Boyer, heard the door behind him open; he quickly turned round his head, to see who was coming in, but could not bring it back to its natural position. Many surgeons of Paris saw this patient; the head was turned to the right, and slightly inclined to the shoulder of the same side. This inclination was much less than it would have been in a spasmodic contraction of the sterno-mastoideus muscle.—*Ed.*

its functions, and the diaphragm supports respiration; but if, on the contrary, the fracture be situated above the origin of this nerve, death immediately ensues. It is true, that a small filament of the second cervical nerve contributes to the formation of the phrenic, but it is in itself insufficient to support respiration under fracture of the third vertebra.

The first case that I will give of serious injury to the spinal chord from displacement of the vertebræ, is one which Mr. Else, who preceded Mr. Cline as teacher of anatomy at St. Thomas's Hospital, used to mention in his lectures.

Case CCCXXXVI.—A woman who was in the venereal ward at St. Thomas's Hospital, and who was then under a mercurial course, while sitting in bed, eating her dinner, was observed to fall suddenly forward; and the patients, hastening to her, found that she was dead. Upon examination of her body, the dentiform process of the second vertebra had been broken off, and the head, in falling forwards, had forced the root of the process back upon the spinal marrow, which occasioned her instant dissolution.

Louis, says Boyer, in making researches on the manner in which persons die who are hanged, found that those despatched by the executioner of Lyons, perished by the dislocation of the first vertebra from the second; whilst those hanged at Paris were suffocated by strangulation. He discovered the cause of this difference to be a rotatory motion given to the body of the victim by the executioner of Lyons, at the moment that the ladder was taken from under his feet.

The following well-known case of Petit's shows how the second cervical vertebra may be displaced from the first.

Case CCCXXXVII.—A boy, six or seven years old, went into the house of a neighbour, who, in playing with him, lifted him from the ground by the chin and back of the neck, telling him that he was going to show him his grandfather; a common expression among the vulgar. Scarcely was the child raised from the ground, when he began to struggle, and by his efforts dislocated his neck and died on the spot. Remarkably enough, the child's father in his rage, threw a sharp instrument at the person who had caused his son's death; which struck him in the back of the neck, dividing all the muscles, penetrating between the vertebræ, and dividing the spinal cord; so that he died instantaneously in the same manner that the child had done

FRACTURES OF THE LUMBAR VERTEBRÆ.—The effects which arise from fracture and displacement of the spine below the origin of the phrenic nerve, depend upon the proximity of the accident to the head. If the lumbar vertebræ be displaced, the lower extremities are rendered so completely insensible, that no injury inflicted upon them can be perceived by the patient. Pinching, burning with caustic, or the application of a blister, are alike unfelt. The power of volition is completely destroyed, not the smallest influence over the muscles remaining. The sphincter ani loses its power of resistance to the peristaltic motion of the intestines, and the fæces pass off involuntarily. The bladder is no longer able to contract, and therefore the urine is retained until drawn off by a catheter. But the involuntary powers of the limbs remain nearly the same as before. The circulation proceeds, although perhaps somewhat more languidly, yet sufficiently to preserve their heat: and local inflammation can be excited in them. A blister applied upon the inner side of the thigh or leg, of which the patient is wholly unconscious, will still inflame, vesicate, and heal; showing that the involuntary functions may proceed in parts which are cut off from their connexion with the brain and spinal marrow.* The penis, under these circumstances, is generally erect. Patients die from this injury at various periods, according to the degree of displacement of the vertebræ. In general, in fractures of the lumbar vertebræ, the patient dies within the space of a month or six weeks after the injury; and usually for some time before death, the urine passes off involuntarily, from extreme debility. I remember a patient of Mr. Birch, in St. Thomas's Hospital, who lived more than two years after this accident, and then died of gangrene of the nates.

FRACTURES OF THE DORSAL VERTEBRÆ.—In fractures and displacement of the dorsal vertebræ, the symptoms are very similar to those described in fractures of the lumbar; but the paralysis extends higher, and the abdomen becomes excessively inflated. I remember one of our pupils saying, when a patient was brought into Guy's Hospital who had suffered from injury to the dorsal vertebræ, "Surely this man

* I have always thought that although sensation and volition depend upon the brain, the spinal marrow, and the nerves, yet that the involuntary functions depend principally upon the nerves.

has ruptured his intestines, for observe how his abdomen is distended." But the first fæcal evacuation relieved this state, and proved that it had merely arisen from excessive flatulency. This symptom proceeds from diminished nervous influence in the intestines;* for although their peristaltic motion can proceed independently of the brain and spinal marrow, yet it is quite certain that the involuntary functions of the intestines, like those of the heart, can be influenced by the brain and spinal marrow; for we see even states of the mind producing affections of the intestines; one state rendering them torpid, and another irritable; as we see the heart leaping with joy, and depressed by disappointment. We also observe pressure on the brain rendering the intestines very difficult of excitement, even through the influence of the strongest aperient. From displacement of the dorsal vertebræ, death sooner succeeds than in similar injuries to the lumbar, the patient usually surviving the accident not more than a fortnight or three weeks; but still I knew a case of a gentleman in the city, who met with this accident, and who lived rather more than nine months. The period of existence is short or protracted, in proportion as the injury is near or distant from the cervical vertebræ, and as the displacement is slight or considerable; it depends also upon the degree of injury which the spinal marrow has sustained.

Fractures of the cervical vertebræ, below the origin of the phrenic nerve, produce paralysis of the arms, as well as of the lower parts of the body; but this paralysis is seldom complete. If it occurs at the sixth or seventh vertebra, the patient has some feeling and powers of motion; but if at the fifth, little or none. Sometimes one arm is much more affected than the other when the fracture is oblique, and the axillary plexus of nerves is, in consequence, partially influenced. Respiration in these cases is difficult, and is performed wholly by the diaphragm, the power of the intercostal muscles being destroyed by the accident.† The abdomen is also tumid from flatulency, as when the

* Preceding dissolution, in almost all diseases, a great evolution of air into the intestines is observed, and from the same cause.

† I have constantly observed a peculiar suffused appearance of the countenance, like that of a person recovering from asphyxia, in cases of fracture of the spine. I do not remember to have seen this symptom noticed by any one else, but it is one on which I always rely, as a diagnostic mark: it appears to be a consequence

dorsal vertebræ have sustained any injury. The other symptoms, in regard to the lower extremities, the bladder, and the sphincter ani, are the same as in fractures of the vertebræ below the cervical. Death ensues in these cases in from three to seven days, according as the fracture happens to be seated in the fifth, sixth, or seventh vertebra. I have scarcely known the subject of this injury to live beyond a week, and but rarely to die on the second day, although they sometimes die so early, if the fifth cervical vertebra has sustained the injury. I have already stated, that in fractures and displacements above the fourth cervical vertebra, death almost instantaneously follows.* The longest life I have known after such an accident has been ten months.

Dissection.—In the dissection of these cases the following appearances are found. The spinous process of the displaced vertebra is depressed; the articular processes are fractured; and the body of the vertebra is broken through; for it but rarely happens that the separation and displacement occur at the intervertebral substance. The upper fragment of the body of the vertebra is usually advanced from half an inch to an inch. Between the vertebræ and the sheath of the spinal marrow, blood is extravasated; and frequently there is extravasation of blood on the spinal cord itself. The spinal marrow is compressed and bruised in slight displacements, and is torn through when the injury has been very extensive; but the dura mater remains whole. When the patient has survived the injury for some time, a bulb is formed at each end of the lacerated spinal marrow, which laceration is usually produced by the bony arch of the spinous process.

A most interesting case of this accident has been published by Mr. Harrold, an intelligent surgeon at Cheshunt; and a preparation made from his case is preserved in the Museum at the Royal College of Surgeons.

The outline of the case is as follows.

Case CCXXXVIII.— A man, twenty-eight years of age, was knocked down by a quantity of chalk, which, falling upon him,

of the imperfect arterialisation of the blood, through the inability of the muscles of respiration to perform their office properly.—*Ed.*

* That is, if the injury be sufficient to annihilate the functions of the spinal cord.—*Ed.*

broke his spine at the lower part of the dorsal, or the beginning of the lumbar vertebræ.

The principle upon which Mr. Harrold proceeded was, to produce union of the bones, by preserving the spine perfectly at rest; and to effect this object the patient was placed on a fracture bed, which permitted him to evacuate his bowels without disturbance. The urine was drawn off daily by the catheter for several weeks; after which time he was able to retain from a pint to a pint and a half, and to discharge it when he pleased. An ulcer was produced upon the sacrum, from the constant pressure of his body upon the bed; and although he was insensible of it, the sore gradually healed.

At the end of six months his state was as follows. His back was straight, flexible, and apparently as strong as ever. He retained and passed his urine, but probably he discharged it more by the action of the abdominal muscles than by any contraction of the bladder. He had a stool once in three or four days. His health and spirits were good, but he had neither sensation nor volition in the lower extremities. He dressed himself entirely; and let himself down stairs step by step. He died after the lapse of twelve months wanting nine days, from the accident, owing to a sore on the tuberosity of the ischium, and to disease of the bone.

I carefully examined the injured parts, which are preserved in the museum of the College of Surgeons, and found the following circumstances.

The bodies of the first and second lumbar vertebræ had been fractured: the first had advanced, and the second had been forced backwards.

The fracture had united by ossific matter, which had been spread over the fore part of both vertebræ to a considerable extent, and a little had been deposited upon the dorsal vertebræ.

The spinal canal had been much diminished by a portion of bone forced into it from the first vertebra of the loins: this portion of bone had split the theca vertebralis into two, and divided the spinal marrow almost entirely: there appeared above and below the bone a bulbous projection of the spinal marrow, formed by its divided extremities, which were separated nearly an inch from each other.

Mr. Brookes also has a preparation in his excellent anatomical

collection, of fracture of the spine at the seventh and eighth dorsal vertebræ. The person had lived sufficiently long for a great deposit of ossific matter to have formed upon the anterior and lateral part of the fractured vertebræ. The spinal marrow was almost entirely torn through, but the spinal sheath remained. Mr. Brookes could not learn how long the person had survived the accident.

I will now give a series of cases to illustrate the various circumstances attending these accidents.

Case CCCXXXIX. — John Attwood, æt. seventeen, a fine healthy-looking muscular young man, was admitted into Guy's Hospital on July 26th, 1836, under Mr. Key. He was thrown from a waggon, which turned over on him, and was found with his head bent forwards between his knees. His symptoms on admission, which was three-quarters of an hour after the accident, were, an entire loss of sensation of the lower extremities, (the boundary of sensation being the crista of the ilium and Poupart's ligament,) priapism, and a most acute tenderness in the abdomen. On examining the back, considerable displacement of the lower dorsal vertebræ was found, the spines of the lower vertebræ being nearly an inch posterior to those above. There was a great deal of blood effused in the neighbourhood of the injury, which gave a slight appearance of lateral curvature; the pulse was quick and pretty full, reaction having begun. Mr. Key made slight extension by traction at the feet, the shoulders being the fixed point, with supposed good result. The patient was cupped to ten ounces, at the seat of pain; and one ounce of healthy urine was drawn off by the catheter, the passage of the instrument not being felt. In the evening he was easier; pulse 106, and full; skin hot; copious perspiration, confined to the face; three ounces of urine drawn off; partial priapism remaining. He was ordered two grains of calomel and one of opium at bed-time, and a dose of castor oil in the morning.

27th. Pulse 110, and full: abdomen less tender; urine acid; twelve ounces of it drawn off. He was ordered fifteen grains of nitre, and twenty-five minims of antimonial wine, in saline mixture, every six hours.

In order to see the comparative effects of a blister on a paralysed and on a non-paralysed limb, a small one was applied to

the inner side of the calf of the leg, and another to an analogous part on the fore-arm of the same side.

27th. Bowels open freely, passage of fæces not felt; tongue white; acute tenderness of abdomen disappeared. Elastic gum catheter left in the bladder.

28th. Fever continues, with difficulty of respiration; abdominal tenderness partially returned; urine alkaline; fæces passed involuntarily.

29th. Increased pain in back and abdomen; respiration 32 in the minute; urine more alkaline. Bladder has been injected with warm water. The blisters have risen almost equally well, perhaps that on the arm most extensively. A draught, containing fifteen grains of nitre and twenty minims of dilute nitric acid, three times a day.

30th. Urine abundant and acid; less thirst. Blisters to be repeated on the opposite side.

August 1st. Pain in back more severe; more abdominal tenderness; urine alkaline. Bowels freely opened; pulse 104. Blisters have produced similar effects on the arm and leg.

2nd. Delirious through the night; great pain in the back. He is apparently labouring under pneumonia. Pulse 112; urine the same.

4th. Fever continues much the same. The injection of the bladder twice daily brings away a considerable quantity of mucus, &c. He is too irritable for examination by the stethoscope.

6th. Better.

10th. Improving; a diffused erysipelatous blush on the back; nates excoriated. The projection of the spine is now only a quarter of an inch below the fracture.

15th. Great increase of phosphatic deposit in the urine.

16th. An abscess has burst at the upper part of the scrotum, near its junction with the penis, communicating with the urethra; the scrotum and penis are œdematous, and are ordered to be suspended. He still requires the catheter.

20th. He has several times, during the last week, experienced numbness and pain in the left knee, and once in the foot; the feet are œdematous; when the left hip is touched he perceives it; slow emaciation. Linseed-meal poultice to the spine.

September 13th. Generally speaking, much the same.

October 2nd. With the exception of two fresh ulcers having formed on the back, he is much the same. He was ordered a quarter of a grain of strychnine, and twelve minims of dilute nitric acid thrice a day.

10th. Pneumonia returned; the whole of the left lung consolidated; urethral fistula enlarged; paralysis rather increased. The strychnine was omitted, and he was ordered expectorants.

27th. Pneumonia improved.

November 7th. Feels pretty well, only slight pain in the back; cough entirely gone; tongue clean; appetite good; sleeps well. Omit medicine.

December 15th. Entire want of sensation in the lower extremities.

For the next two months his general health continued very good. Full diet, with wine.

July 6th, 1837. Emaciation has again commenced; appetite and general strength failing.

17th. Appetite gone; powers failing; diarrhœa and constant vomiting. He gradually sunk, and died on the 28th July.

Post-mortem examination twenty-six hours after death.—The body was considerably emaciated, and the skin over the posterior parts of the lower extremities inflamed, and in several parts ulcerated. The spinous processes of several of the dorsal vertebræ were laid bare, and appeared enlarged and ulcerated. The heart was tolerably healthy. The right lung was somewhat adherent towards the apex; the adhesions were of old formation; it was pretty well collapsed and crepitant, and was quite free from consolidation. The bronchial tubes were increased in vascularity, and, in parts, thickened. The left lung also presented a few old adhesions towards its apex; it was similar in appearance to the right. The cavity of the peritoneum was free from adhesion and effusion of lymph. The liver of large size, coarse, of lightish colour, and fatty. The spleen was considerably enlarged; its tunic thickened and opaque; its substance softened. The right kidney was of moderate size, and somewhat granular: its pelvis contained several calculi, from the size of a pea to that of a moderate-sized nut. The left kidney was rather small and granular, its tunic firmly adherent.

The body of the first lumbar vertebra appeared to have been fractured through, and was considerably displaced backwards, so

as to encroach upon the canal in the latter place; the spinal marrow was divided so that the body of the lower and the arch of the one above were immediately in contact with one another. The spinal marrow, for a considerable distance above this part, was completely softened, so that there was nothing but the empty sheath remaining in the canal. The cauda equina did not appear to have suffered from the compression, as it remained undisturbed. There was a small groove through which a portion of the spinal marrow appeared to have been transmitted. The projected portion of the body of the vertebra was in a considerable degree loosened in texture, and appeared to have commenced ulceration; it was soft, and easily separated with the knife. The sheath surrounding the injured part of the cord did not appear to be ulcerated. The spinous process of the vertebra appeared to have been destroyed. The intervertebral substance between the twelfth dorsal and first lumbar appeared to have been destroyed, whilst in the other parts it was softer and larger than natural. There appeared to have been perfect anchylosis produced between the body of the fractured vertebra and the body of that situated above it. The arch of the fractured vertebra appeared to have been fractured and repaired, so that it is a very imperfect one. The articular processes were so very indistinct as to render it impossible to distinguish them.

Case CCCXL.—John Lias, æt. thirty-four, was admitted into Guy's Hospital on 18th June 1838, under Mr. Cooper. He had been generally employed as an engineer, and in elevating a heavy wheel, it fell upon his back whilst in a bent position. At present he has completely lost all power of motion and sensation in the lower extremities; he has retention of urine, and involuntary evacuation of fæces; and there is a depression of the spinous process of the twelfth dorsal vertebra. Mr. Key ordered exten-

sion of the body to be made, which replaced the fractured vertebra to a considerable degree. But the patient felt no relief whatever in the lower half of the body, and complained of considerable pain at the anterior part of the abdomen.

27th. He has sensation in the right leg, and can move it a little; but the left is motionless, and devoid of sensation. The involuntary evacuation of urine and fæces continues.

August 7. Countenance cadaverous, cheeks and eyes sunk; he breathes with great difficulty, and appears to suffer from pain; articulation very indistinct. Pulse 120, small.

On the 9th he died.

Inspection the same day.—The body of this patient appeared to have suffered rapid and great emaciation; the surface was pale and the features pinched, retaining a marked expression of pain and distress; the coverings of the sacrum and right knee had sloughed.

The right lung was adherent by old and recent false membrane; the lining of the large bronchi was lividly, but not deeply, injected, and coated with frothy mucus; the smaller tubes were dilated, their secretion puriform; it appeared generally to be undergoing a reparative stage of pneumonic change. The upper lobe of the left lung was healthy, the lower consolidated; the edges of both lungs in points were rounded by vesicular dilatation. The heart was healthy.

The aorta, about two lines below the insertion of the remains of the canalis arteriosus, presented a fissure extending two-thirds round the circumference of the canal, and offering the appearance of a smooth rent completely through the lining and middle coats, excepting where at one point a small band, formed by the separation of a portion of the circular fibre and serous coat stretched across the fissure. To the edge of this band a rough conical vegetation was attached, which was the only appearance of thickening presented by the torn edges, which were merely rounded and turned away from the current of blood. Extravasation was prevented by the thickening of the outer tunic of the vessel, which was slightly dilated, and contained a small clot. The abdomen was tympanitic; the omentum slightly adhered to the fundus of the bladder; dirty yellow pus escaped from behind the muscles and fascia when the abdomen was opened. The liver was large, rather coarse and soft, light-coloured, but

allowing the escape of much blood when cut into. The kidneys were highly gorged with blood, and their pelvis distended by a dirty puriform secretion. The bladder was contracted; the muscular tissue about half an inch in thickness; the cavity small, and containing a little turbid urine; the lining corrugated, dark-coloured, and some spots coated with patches of unadherent lymph. A large sloughy cavity occupied the entire posterior and upper surfaces of the bladder, containing thick, fœtid pus.

The body of the twelfth dorsal vertebra had suffered comminution, and a small portion still remained attached to the upper part of the column: this had been displaced downwards backwards and to the right side; the remainder of the body, attached to the lumbar column, was nearly in contact with the concavity of the angle of the eleventh rib. The dura mater of the cord was healthy; the canal had become distorted in a curve outwards and to the right, and the cord had suffered pressure at the commencement of the cauda equina. Upon the left side a portion of the comminuted bone, from the posterior part of the vertebra, had been forced into the canal, and, without lacerating the dura mater, had thrust the nerves of the cauda equina upon that side obliquely upwards, in such a manner as to subject them to pressure; the nerves upon the right side were thus placed out of sight in the hollow formed by the yielding of the column in that direction. The nerves upon the latter side must have been comparatively free from pressure, except that there appeared to be some traces of blood extravasated between the membranes and the bone at that part. The cord had not suffered rupture at any spot, but its tissue was in a softened condition, to the extent of about an inch above the point of greatest pressure. The arachnoid had undergone little change excepting a very distended state of its veins upon the right side.

The upper dorsal vertebræ were not removed, but no distortion of their bodies, as seen from the thorax, was observed.

CASE CCCXLI.—William Billson, a lighterman, æt. forty-nine, was brought to Guy's Hospital on November 18th, at half past two P.M., having received a severe blow on the cervical vertebræ, from the hatch of a vessel, which had inadvertently been let fall on him, and threw him prostrate on the deck.

At the period of his admission, he was in a partially comatose state, with a weak and compressible pulse; beside which symptoms, there were none others which would indicate a fracture of the vertebræ, although from the violence of the blow it was reasonably supposed that such, or something analogous had occurred. The extremities were moved at will, but the patient expressed pain on so doing, which was attributed to contusions he had received from falling. Upon examination of the right arm and leg, of which he complained the most, there appeared several contusions, especially about the knee. He answered questions rationally.

After being placed in bed a dose of calomel, colocynth, and house-mixture was administered, which operated freely. At seven P.M. he complained of much pain on pressure over the nape of the neck, to relieve which he was cupped on the part affected to ℥xii; after which the comatose symptoms entirely disappeared, and the pain on pressure was much less.

19th. He slept tolerably well during the night. He is able to lift himself, but expresses pain in so doing, referable to the neck and contused parts. Fomentations ordered to the contusions, and a dose of calomel and opium at bed-time. Bowels open.

Until November 27th he remained much in the same state, fomentations and embrocations being employed, by which the contusions were lessened. On the morning of that day an erythematous blush appeared over the back extending with irregular edges towards the chest. The pulse was small, quick, and compressible; the tongue covered with a dry brown fur.

He was ordered one grain of calomel, half a grain of opium, and one-sixth of a grain of tartar emetic twice a-day; and a saline draught every four hours. Warm fomentations to be applied to the back. The erythema was attributed to the scarifications.

28th. He slept but little during the night. Erythema much the same. Pulse still weak and compressible. Tongue somewhat improved. Ammonia was added to his effervescing mixture, and the tartar emetic was omitted.

29th. He slept much better. Tongue improved. Pulse much the same. He was ordered four ounces of brandy and a pint of porter daily.

30th. He slept tolerably well. Pulse weaker. Tongue improved. Continue the mixture and brandy.

December 1st. He has been unable to retain either fæces or urine during the night. Pulse still weaker. To take ammon. carb. gr. v.; tinct. cinch. ʒi.; tinct. opii gtt. xii.; infus. serpent. ℥iss, 4ta quâque hora.

2nd. At two A.M. the dresser for the week, Mr. Webber, was requested to see him. He then appeared to be dying; complaining of excruciating pain (which appeared to be spasmodic) on the right side; to relieve which, brandy, ammonia, and opium was administered, and a mustard sinapism applied to the side, which had the desired effect, for he shortly became relieved, and remained so until his death, which happened two hours afterwards.

Post-mortem Examination.—The body was stout and well built, but not very fat. The lungs were distended with air; the heart was decidedly large, and the right side of it was full to excess; it had on its upper surface a patch an inch square of opaque thickening, and an adjoining line, nearly an inch long, of the anterior coronary artery was similarly affected, but no other part.

The peritonæum and abdominal viscera presented no particular appearances, excepting that the kidneys were remarkably cystiform; both these organs were enlarged, but the right the more so; they were very thickly set with simple globular urinary cysts, which varied in size from about the dimension of a pea to that of a bean. The secerning structures were very much encroached upon at all parts, but there was probably much left that was active. The tunic was little separable, and the general substance was moderately firm and injected. The contents of the cells consisted pretty uniformly of a dull palish urinous fluid; that of one large cyst was black and rather thick. The bladder contained half a pint of urine. The left leg from above the knee was full and tense, and in a marked degree livid; the surface

scarcely pitted: the vastus internus and most of the muscles of the leg were inflamed, and tumid from a fluid infiltration, and in many spots becoming pale and softened from an infiltration of fibrine and drops of incipient pus. The surrounding tissues were in a similar condition, tinged with blood, watery, and in points actually suppurating. An erythematous erysipelas had faded from the nucha. Over the seventh cervical spinous process was a broad thick-coated whitish leathery bursa; the fluid of which I did not see, but it must have been moderate in quantity, and of a watery character. The body of the sixth cervical vertebra was found broken through horizontally, and the inferior vertebral substance involved; the displacement, as first seen anteriorly, was very inconsiderable.

Case CCCXLII.—A man, æt. forty-five, fell from a scaffold, and received a blow on his back. All the parts below the epigastrum became immediately paralysed. At the end of nine days, it was observed for the first time that a slight involuntary action of the muscles of the thighs was induced when pressure was accidentally made on that part; afterwards, severe cramps and painful convulsions took place, whenever pressure was made on any part of the body, or even by lifting up the bed-clothes. At last they were almost constant, so as almost to awake him from his sleep. When he died, nine weeks after the accident, it was ascertained that there had been fracture of the ninth dorsal vertebra, with such a degree of displacement as to produce a slight compression of the spinal cord. There was an abscess containing from four to six ounces of pus, communicating with the fracture and extending into the posterior mediastinum. The membranes of the spinal cord, and the cord itself, presented a natural appearance externally; but on the latter being divided longitudinally, the central part of it was found to be in a softened state, so that on being macerated for a short time in water, it almost completely disappeared.*

Case CCCXLIII.—A boy was admitted into St. George's Hospital in September 1827, with a fracture and considerable displacement of the third and fourth lumbar vertebræ, so as to cause a manifest alteration in the figure of his spine. He was

* This and the following case are taken from Sir B. Brodie's paper on Injuries of the Spine in the Medico-Chirurgical Transactions. They are quoted because they present instances of the involuntary contractions which sometimes follow injuries of the Spine.

paralytic in his lower limbs. An attempt was made to restore the displaced vertebræ to their natural position, and was attended with some, but not complete success. At the end of a month, he became affected with slight involuntary motions of the lower limbs, and at the same time he began to recover the power of using them voluntarily. Early in the following January he quitted the hospital, and I have since, says Sir B. Brodie, had no opportunity of seeing or hearing of him.

The next case was sent me by my former pupil, Mr. W. Baxter, surgeon in the New Road.

Case CCCXLIV.—A man suffered dislocation with fracture of the sixth and seventh cervical vertebræ, in consequence of a sack of malt, weighing 150 lbs. falling on his neck whilst it was bent upon the chest. The symptoms were, partial paralysis of the upper, and complete paralysis of the lower extremities; sensibility was natural above the level of the groins, but absent below them; the respiration was performed solely by the diaphragm: there was severe and constant pain about the sixth cervical vertebra, and in both shoulders; the pulse was strong and frequent, and the tongue furred and dry; the thirst was excessive; there was no sleep; the skin was burning hot; the belly tympanitic; the fæces and urine retained; the latter highly ammoniacal; and there was partial priapism. The intellectual faculties were perfect.

Post-mortem appearances.—Great extravasation of uncoagulated blood among the neighbouring muscles, and into the posterior mediastinum; fracture of the spinous process of the sixth cervical vertebra; separation of the bodies of the sixth and seventh, (the sixth projecting forward,) with laceration of their anterior ligament; fracture of the upper and anterior portion of the body of the seventh, which portion remained attached to the anterior perpendicular ligament, and fracture of the articulating surfaces. The medulla was compressed by the body of the seventh and the broken surfaces of the spinous process of the sixth vertebra.

I received the following case from Mr. Greenwood, of Horselydown, in the year 1826.

Case CCCXLV.—Mary Vincent, aged 47, in raising a turn-up bedstead into its place, let it slip from her hand, when above her head, and received it on its fall on the back of the neck. This

occurred July 26th, 1826. I did not see the woman until eleven days after the accident, at which time I found her labouring under considerable difficulty of breathing, occasioned by paralysis of the intercostal muscles, so that respiration was carried on by the diaphragm and abdominal muscles only. There was great diminution of the muscular power generally, but no other parts were paralysed but those just mentioned.

About three weeks after the accident, supposing herself to be sufficiently well to have her things changed, she attempted to move for that purpose, and immediately the right arm and hand became paralysed. I ought to have observed before, that when I first saw the patient, she complained of pain at the seat of the injury, which appeared to be about the situation of the fourth or fifth cervical vertebra; at this part there seemed to exist a depression, and pressure in this situation occasioned universal paralysis, as did the actions of coughing and sneezing. The woman lived until Friday, November 10th, 1826, a period of fifteen weeks and six days. Her death seemed to result from the effect produced by the injury on her digestive organs. She lost her appetite, became sick, was frequently attacked with purging, which latterly became constant, and was thus gradually worn out.

In the way of remark, it may be well to add that, when the purging first occurred and was only occasionally present, it had the most extraordinary effect upon her, so that, after continuing a few hours, she would appear to be just dying, but would presently rally again on the exhibition of stimulants.

Case CCCXLVI.—John Sayer, æt. thirty, a shipwright, was admitted into Guy's Hospital, on the 13th of November, 1832, with all the symptoms of fractured spine, having fallen from a wharf, a height of twenty feet, upon the shore, and pitched directly on his occiput. On his admittance into the hospital, about half-an-hour after the accident, at half-past ten, A.M., he was the subject of paraplegia, of the loss of sensation of the right inferior half of the abdomen, and of a complete state of priapism; his pulse was very feeble, and his countenance much suffused, his abdomen tympanitic, his breathing difficult, and he complained of a sensation of chilliness, and pains in the arms and neck, especially of the right wrist, which was considerably swollen. He had made water just before the accident.

He was ordered to be covered up warmly, to have bottles of hot water to his feet, and to take the julep of ammonia every five or ten minutes, until reaction had come on.

At 12, mid-day, the pulse remained unaltered, and the countenance equally suffused; the state of priapism was somewhat less, and the sensibility of the right side of the abdomen had in some degree returned. About half-a-pint of urine was now drawn off, which was quite natural both in appearance and smell.

At 4 P.M. He remains much the same; has taken some barley-water.

At 11 P.M. The pulse was fuller and quick; he was restless, and complained of a feeling of faintness; the countenance remained much the same; his water was again drawn off, which was quite natural, and he was ordered thirty drops of the tinct. opii in an ounce and a half of camphor mixture.

Wednesday morning, 11th November. He remains much in the same state; dozes occasionally, but has had little sleep. Pulse not so full; rather more suffusion of the face, attended with watering of the eyes. A pint of urine was drawn off, but he has had no motion since the accident. A castor-oil enema was ordered, which not operating, at half-past three in the afternoon, he was ordered a colocynth enema; this produced the desired effect, the contents of the bowels passing away involuntarily: he had three or four motions between three o'clock in the afternoon and eleven at night, at which time his pulse was about 100. He then complained of some nausea, for which he was ordered twenty-five drops of laudanum in an ounce and a half of camphor mixture, which succeeded in allaying his sickness.

15th. Pulse 100, and fuller; less distress of countenance, although still much suffused; the watering of the eyes had ceased; breathing apparently performed with less difficulty, although entirely by the diaphragm; the tongue covered with a light-brown dry film; he had incessant nausea, with occasional vomiting during the night; bowels frequently open, the contents passing away involuntarily.

10 A.M. Sickness better; he kept some coffee on his stomach; complains of great thirst; belly tympanitic; urine, which has been drawn off, has a strong ammoniacal smell; symptoms remained the same all the day, except that his sickness returned in the afternoon; ordered brandy and soda water, which remained on his stomach.

At 12, midnight, his urine was drawn off, which was highly ammoniacal. An opiate draught was given him.

16th. Pulse 92, more compressible; tongue covered with a dark-brown fur resembling calomel decomposed by a weak solution of lime; he has had but little rest; he kept the draught for an hour on his stomach after he had taken it, but rejected everything else; other symptoms the same. A pint and a half of urine was drawn off, highly ammoniacal.

Half-past 6 P.M. Pulse the same; face bedewed with perspiration; the vomiting in some degree abated; he has kept broth and the brandy and soda water in a state of effervescence, with lemon juice, on his stomach; his bowels have not been relieved since last night, excepting passing a dessert-spoonful of white mucus, something like the white of an egg; a common enema was ordered.

10 P.M. The clyster has operated two or three times; pulse 96, and more compressible; breathing oppressed and hurried; he is much troubled with expulsion of wind per anum. All the other symptoms remain the same; the perspiration on the face is lessened; three ounces of water were drawn off, which was, as in the morning, very ammoniacal; he was ordered thirty drops of laudanum at bed-time.

Saturday, 17th, 11 A.M. Pulse 92, small and compressible; abdomen still tympanitic; he has had some sleep, and no recurrence of vomiting; he does not complain of thirst; the bowels have not been relieved; he has some feeling in his thigh, but not in his legs; a pint and a half of urine was drawn off, mixed with a considerable quantity of blood and mucus.

Half-past 9 P.M. He remains the same as in the morning; was ordered a clyster, which operated almost immediately; half-a-pint of urine was drawn off, mixed with blood and mucus, and smelling powerfully of ammonia; some quantity has passed from him involuntarily during the day; he has kept nourishment on his stomach; was ordered to repeat the anodyne at night.

Sunday, 18th, 11 A.M. He has passed a tolerable night; pulse 75, and compressible; contents of the bowels have been twice passed involuntarily, as has the urine; a pint, however, was drawn off by the catheter, this morning, with somewhat less blood in it. Abdomen still tympanitic; countenance more depressed and anxious; he has taken, in the last two days, arrow-

root and milk, which has been retained. This morning, I noticed that his urine passed from him in small quantities with each effort of respiration.

10 P.M. He is much the same; his urine was drawn off; the bowels have been twice relieved; ordered tinct. opii ʒss. h. s.

Monday, 19th, 11 A.M. He seems weaker; urine passing at intervals involuntarily, less tinged with blood; a pint of it was drawn off by the catheter; priapism still remaining, but not always to the same degree.

6 P.M. He is sinking gradually; no water could be drawn off.

Tuesday, 20th, 11 A.M. He has had a very restless night. A clyster, which had been given last night, had operated two or three times; urine continues to pass at intervals involuntarily; he has vomited occasionally since six this morning. Pulse 85, but scarcely perceptible; abdomen very tympanitic, with disposition to priapism; half-a-pint of urine was drawn off, which had not so ammoniacal a smell, but was highly alkaline, as proved by the test paper.

10 P.M. The bowels have been relieved; stertorous breathing has come on; the abdomen is excessively tympanitic; the pulse imperceptible. He is to continue the tincture of opium at bed-time.

Wednesday, 21st. Sinking fast; pupils insensible; he expired at 12 mid-day.

Post-mortem examination.—On raising the skin there was a remarkable absence of fat, and the muscles were particularly firm and dry; two of the lower ribs, on either side, were found to be united, so as to form a bifid termination; the left lung was free from pleuritic adhesions, rather engorged, and somewhat emphysematous, indicated by a round and puffed margin; the right lung had some adhesion at the apex, and its substance was rather too firm for a state of health; the heart was natural, but there was rather more fluid in the pericardium than is usually found, and the membrane itself was somewhat tinged with a rose-colour, arising from the turgescence of its vessels. On opening the abdomen, the intestines were very much distended with flatus, but presented no other morbid appearance, than in one or two places a small flake of puriform secretion, on their peritonæal covering. The bladder was distended, and its posterior part was adherent to the parts in contact with it by bands that had assumed a considerable degree of organization, and in laying

it open, the mucous membrane was found thickened, discoloured, and ecchymosed in patches, with flakes of lymph scattered all over its surface; this state was probably the effect of the frequent use of the catheter, the introduction of which had latterly been attended with some difficulty. The urine found in the bladder was tinged with blood, and highly ammoniacal: the ureters were healthy, as were the spleen, the pancreas, and the liver. On turning the body to expose the back for the purpose of examining the vertebræ, no mark of external injury was visible. The whole spinal cord was removed, and found healthy, excepting opposite the sixth cervical vertebra, where its substance was broken down, and very much discoloured. It is proper to notice that, although the medullary substance of the spinal marrow was perfectly healthy, excepting in the very seat of the injury, there was a considerable turgescence of the vessels of the dura matral sheath throughout. On a careful examination, the sixth cervical vertebra was found split longitudinally, and so separated as to project backwards over the seventh. The posterior ligament proper to the bodies of the vertebræ was slightly torn.

The diagnostic marks of the nature of this accident were so clear that it was impossible to mistake the cause of the symptoms, as arising from compression of the spinal marrow; and as soon as I saw the patient, without examining the spine, I prognosticated that it was the sixth or seventh cervical vertebra that was injured; and this I was led to believe from observing that all the intercostal muscles were paralysed, respiration being only carried on by the diaphragm, the action of which was perfect, and this could not have been the case if either of the dorsal vertebræ had been fractured, or the cervical above the sixth.*

Case CCCXLVII.—A horse-dealer was shot by a pistol containing two balls, one of which penetrated the side of the neck high up, and rather in front. He ran towards the man who shot him, but, after about twenty or thirty steps, fell, insensible. When taken up, he was suffering from violent convulsive movements of the arms and muscles of the chest; his legs were paralysed. He was bled repeatedly, and returned to his senses, after twenty-four hours, but his tongue was palsied, so that he could not speak. He died on the fourth day. On examination, it was

* Surgical Essays, p 41.

found that the lamina and transverse process of the second cervical vertebra had been fractured and driven in, so that the spinal marrow was compressed, and all the great nerves which leave the spine at that part were bruised.

In the three next cases, which are taken from Ollivier, it will be noticed that the functions of the spinal marrow were only partially impeded by the injury; although in the second case death occurred from a subsequent aggravation of that injury, and in the third, although the spinal marrow was able to transmit an obscure sensibility, yet the irritation of the fracture produced softening and disorganization.

Case CCCXLVIII.—A French soldier was wounded in the loins; after his recovery he possessed the perfect muscular use of his legs, but he could not hold his water, and he had entirely lost the sensation of the inner and fore part of the thighs, as well as of the penis and scrotum, so that the hairs on the genitals could be pulled out without his feeling it in the least.*

Case CCCXLIX.†—A waggoner, whilst loading his waggon, fell backwards, and pitched on the back of his head and neck. He was immediately brought to the Hôtel Dieu, and on examination complained of violent pain at the back of the neck; both the upper and lower extremities were palsied, but more decidedly so on the left side than on the right; sensation also was almost absent on the left side, and but little impaired on the right; the respiration was rather laborious, and performed both by the diaphragm, and by the muscles of the neck and chest.

For the first fortnight the patient was obstinately costive, and could not void his water without the catheter; but at the end of that time he could evacuate both the bladder and rectum at will. At the same time the motions of the limbs became freer, and sensibility returned: this improvement advanced, and at the end of three months the patient left the hospital, able to walk with a stick, and only complaining of slight weakness of the legs.

The same day he walked three leagues into the country to seek work; but not finding any, he walked back again, but just before he reached home, he suddenly fell down, and all the symptoms came on again.

He was a second time brought to the Hôtel Dieu, when it was

* Ollivier, p. 306. † Ibid. p. 256.

noticed that all the symptoms were more aggravated than they had been at first; the palsy and insensibility were greater, and the breathing more difficult; he had also completely lost all power over his bladder and rectum. A large ulcer soon formed on the sacrum; and although he had a trifling amendment at one time, he died on the fortieth day after his relapse.

After death it was found that the body of the fourth cervical vertebra was displaced forwards over the fifth; the intervertebral substance had disappeared, and the two bones were freely movable; but there was some degree of callus uniting them which had evidently been broken at the time of his relapse. The upper border of the body of the fifth vertebra projected considerably into the canal. The left upper articular process of the fifth vertebra was broken, as was the corresponding process of the fourth, which was carried forward, and lodged in the groove for the nerve on the transverse process. The fourth vertebra had been slightly twisted round from right to left, so that the left half of the marrow was more compressed by its lamina than the right half was.

The spinal cord was remarkably contracted at the seat of the injury, especially where it had been compressed by the lamina of the fourth vertebra during life. The anterior columns had not been ruptured, but the posterior were so. In the substance of the cord was a little kernel of fibro-cellular tissue, formed doubtless by a consolidation of the cellular tissue of the cord. The pia mater was thickened at the seat of the injury, and the cord seemed swollen above and below it, and of greater consistence than natural.

M. Ollivier remarks, with regard to this case, that the patient might have recovered permanently had the real nature of the case been suspected, and if he had been made to wear a pasteboard collar, so as to keep the neck immovable, and prevent the fractured surfaces from being separated till they were firmly consolidated.

Case CCCL. — A robust water-carrier received a violent blow on the bottom of the back, from a cask which fell upon him; his legs instantly became palsied, and he died at the end of six days, with all the ordinary symptoms of fractured spine, excepting that his legs still preserved an obscure sensibility. On examination after death, the body of the tenth dorsal vertebra was

found to be crushed into that of the twelfth, so that their spinous processes were separated, and the spine formed an angle. The spinal marrow was flattened out against the upper border of the body of the twelfth vertebra, and was softened for about an inch.

Treatment.—As to the treatment of these cases, I fear, that whatever be done, the majority of them will prove fatal.

To bring the spine into its natural form by extension, would be impossible, if it were attempted; and even if that object were attained, it would scarcely be practicable to preserve it in its situation, as the least motion would again displace it. Rest will be essential to ossific union, but ossific union will not save the patient if the pressure upon the spinal marrow be not removed.*

Mr. Henry Cline was the first person who took a scientific view of this accident. He considered it to be similar to fracture with depression of the cranium, and to require that the pressure should be removed; and as the cases had proved so uniformly fatal, he

* The principal points to be attended to in the subsequent treatment of these cases, may be thus briefly summed up. The patient should be kept perfectly at rest in the horizontal posture; and the utmost care should be taken to prevent sloughing of the skin which covers the sacrum; a circumstance which is extremely liable to occur, because the patient lies continually, like a log, on the same points, without power to shift his position, and because he does not feel any pain when the skin is beginning to suffer, and therefore perhaps the surgeon's attention may not be directed to the part till a considerable ulcer has formed. The water-bed, or Mackintosh air-cushions, half filled with water, placed under the lower part of the back, seem to offer the best chance of preventing this troublesome complication. The urine should be regularly drawn off by the catheter twice a day; and when it begins to be offensive, and the bladder secretes a ropy mucus, which generally happens in protracted cases, relief is afforded by syringing out the bladder with warm water. The muriatic or nitric acids are sometimes administered to counteract this state of the urine, but they seem to be of very little service. The bowels must be kept open with purgative clysters, and occasional aperients, and their tympanitic state may be somewhat benefited by rubbing the abdomen with the compound camphor liniment. If there is very great pain, and the pulse is firm, the constitution robust, and inflammatory symptoms are urgent, a moderate abstraction of blood may be of service; but the experience of most surgeons has shown that when the cord has been lacerated, bleeding, calomel, antimony, and other weakening remedies do but hasten the fatal issue: in fact, when the patient does not die early from the more immediate results of the injury, or from deficiency of respiration, he generally sinks from diarrhœa, and loss of flesh and strength, which must be obviated by opiates and tonics, and whatever other remedies may seem applicable to each particular case.—*Ed.*

thought himself justified in stepping out of the usual course, with the hope of preserving life. He made an incision upon the depressed bone as the patient was lying upon his breast, raised the muscles covering the spinal arch, applied a small trephine to the arch, and cut it through on each side, so as to remove the spinous process, and the arch of bone which pressed upon the spinal marrow. The only case in which he tried it did not succeed; and, unfortunately, he did not live to bring his opinion sufficiently to the test of experiment, to warrant a decided judgment. He was blamed for making this trial. I am not sure that he would have been ultimately successful; but, in a case otherwise without hope, I am certain that such an attempt was laudable.*

In those cases in which the first and second cervical vertebræ have been broken and displaced, death, from obstructed respiration, is too sudden to allow time for any surgical relief.

This operation was also performed by Mr. Tyrrell in St. Thomas's Hospital in the year 1822, and the following account of the case was given to M. Ollivier (in whose work on the Spinal Cord it is published) by M. Georgi, a foreign physician who was accidentally present.

Case CCCLI. — On the 17th of October, 1822, a porter, thirty years of age, was brought to St. Thomas's Hospital, having received a fall on the back whilst carrying a heavy load. The lower part of the body was paralysed, and a fracture with depression of the tenth dorsal vertebra was discovered. The cause of the paraplegia being evident, Messrs. Cooper, Travers, Green, and Tyrrell gave it as their opinion that the depressed portion of bone should be raised. The operation was performed the same day by Mr. Tyrrell in the following manner: —

The patient was placed flat on a table covered with pillows so as to make the back prominent. An incision about four inches in length was then made directly over the spines of the four last dorsal vertebræ. The muscles being dissected from both sides to the same extent, and being separated from the arches of the ninth and tenth vertebræ, a circular trephine was applied on that of the last, which was in vain attempted to be raised. A chain saw was

* I beg the reader to observe, that this operation is not mine,—that I have expressed some doubts of its ultimate success; but I wish the trial to be made, as the only means of deciding positively on its utility; and if it saves only a life in one hundred, it is more than I have yet seen accomplished by surgery.

then applied between the spinous processes of the ninth and tenth vertebræ, and that of the latter sawn off at its base, so that the finger could be introduced between the sides of the vertebræ, which were then removed by Hey's saw. The arch of the ninth vertebra was ascertained to be depressed like the others, and was immediately sawn off in the same manner. The spinal marrow enveloped in its membranes was thus exposed for the extent of three inches; the dilatation and contraction of the organ were so plain that they could be seen at any part of the theatre. The skin was then brought together by three sutures, and the wound simply dressed.

A few hours after the operation, *the patient distinctly felt when he was pinched*, which he had not done before, since the accident; but the power of motion never returned, and that of feeling was only of momentary continuance. A few days afterwards the fæces passed off involuntarily, together with the urine, which was bloody. At last the patient expired, twelve days from the operation, after having displayed signs of very acute inflammation of the peritonæum and intestines.

On examining the body, the peritonæum was found inflamed, as well as several parts of the mucous membrane of the intestines, which were of a deep violet colour. That portion of the sheath of the spinal cord which had been laid bare by the operation, was of a blackish colour, as though gangrenous. No other examination of the spinal marrow was made, as it was preserved for the museum.

Case CCCLII. — Mr. Oldknow, of Nottingham, repeated this operation in the year 1819, and gave me the following account of the result.

"The operation had completely removed the pressure from the spinal marrow, but not until so much diseased action had been induced, as to prevent the possibility of its regaining its healthy structure. The following were the diseased appearances:—Slight sanguineous effusion along the whole dorsal vertebræ, between the internal vertebral ligament and dura mater (not sufficient to occasion injurious pressure). Dura mater more dense and thick at the immediate seat of injury. Pia mater more vascular, through which was seen the spinal marrow, for about the extent of one and a-half inches, a little swollen and presenting a livid appearance; when cut lengthways, its healthy organization was quite destroyed, and instead of it a reddish grey matter was

observed interiorly of about the consistency of thick cream. The operation was not performed until six days after the accident; had it been done immediately, I think it is very possible the man might have recovered. The seat of injury was the seventh cervical vertebra; the roots of its spinous process were fractured and forced under their connexions with the superior oblique processes, the capsular ligaments of these latter being lacerated, as also the intervertebral substance between the seventh cervical and first dorsal vertebræ. In operating I first separated the spinous process at its base with Hey's saw, and then removed its roots by a trephine." †

SECTION V.

SUPPURATION AND ULCERATION OF THE SPINAL CORD.

The only case which I could determine to be of this nature by dissection was the following.

Case CCCLII*.—A gentleman, who resided about eight miles from London, had, by a fall, received a severe blow upon his spine; but as it produced no immediate ill effect, he thought very lightly of it. In going down to his country house he was exposed to the inclemencies of the weather, and he was on a sudden seized with pain in his back, paralysis of the lower extremities, retention of urine, and an involuntary discharge of fæces. I was requested to see him on account of the retention of urine, and went daily for a length of time to Wimbledon Common, where he resided, to make use of the catheter. For several weeks his symptoms remained unchanged, excepting that now

† In the letter in which Mr. Oldknow communicates this case to Sir Astley, he mentions a case of fracture of the trochanter major, which bore considerable resemblance to Case CII. The patient was eighty years of age, and lived half a year after the fracture. On examining the hip, a little while before his death, Mr. Oldknow thought he had mistaken the case, for on rotating the limb inwards, he perceived a bony projection moving with the shaft of the femur, and describing part of a circle, which he took for the head of the bone, but which, on dissection, proved to be the misplaced trochanter.—*Ed.*

and then the integuments of the sacrum gave way, and required great attention to prevent a dangerous sore. Towards the close of his existence he complained of a sense of uneasiness and distension at the upper part of his abdomen. His appetite failed him; he rejected his food, and had a great deal of fever, with quick pulse and profuse perspiration. He sunk gradually, worn out by irritation.

I removed the spinal marrow, and have it preserved in the collection at St. Thomas's Hospital.

Upon opening the spinal sheath, a milky fluid was found within it, just above the cauda equina; and higher than this, for the space of three inches, the spinal marrow was ulcerated to a considerable depth, and was in the softened state which the brain assumes when it is rendered semifluid by putrefaction. All the other parts of the body were healthy, excepting the bladder, which was considerably inflamed, and exceedingly distended by the long continued retention of the urine.

In a case similar to this, it will be necessary to make use of precautions to prevent inflammation, by cupping or by leeches. Blisters should be applied; and if the fever still continue, a seton should be made, or issues be opened, to prevent the continuance of inflammation, by producing and supporting external irritation.*

* This case terminated just as Case CCXXVI. might have done, if proper precautions had not been taken. The softened diffluent state of the spinal marrow is similar to that which will have been noticed in the accounts of the *post-mortem* examinations of several of the preceding cases; in fact, it will be seen that this state closely corresponds to ulceration and gangrene, and is the result of the ordinary process of disorganization of nervous matter, when deprived of vitality by injury or slow inflammation.—*Ed.*

APPENDIX.

No. I.

ADDITIONAL OBSERVATIONS ON FRACTURE OF THE NECK OF THE THIGH-BONE.

The Editor thinks it worth while to add a few more of the communications which Sir A. Cooper received from different individuals, in testimony of the truth of his doctrines on the subject of fractured neck of the thigh-bone, and of the real nature of some of those supposed exceptions to his doctrines which are occasionally so assiduously promulgated.

The first is from Sir James M'Gregor, and is dated 1824.

"In the Fasciculus of engravings of morbid appearances published by the medical department of the army, there is one of a femur, stated to represent a fracture at its neck, which was supposed by the surgeon at the Military Hospital at Chatham to be united by bone, a circumstance, the probability of which you have questioned; it became, therefore, an object of scientific inquiry to ascertain the fact. With this view, Sir William Franklin and I requested Mr. Guthrie to show the bone to the Council of the Royal College of Surgeons, who came to the conclusion that the alteration which has taken place in the cervix femoris did not occur in consequence of a fracture, but from the gradual effects of the weight of the body upon it. We are disposed to concur in the opinion of the Council, and in any future edition of the Fasciculus this will be stated. You are at liberty to make such use of this communication as you may deem fit."

The second is from Professor Burns of Glasgow, and is also dated 1824.

"During the course of operations in the University last winter, a female subject was brought to my room, in whom, from the shortening of the limb and other external appearances, there was every reason to believe that the cervix of the thigh-bone had at a former time been broken. The toes were not turned much from the usual direction, but, if anything, rather inwards. I know nothing of the history of the patient, but, as you have devoted much attention to the subject, I send you the dissection.

"The whole of the head and neck of the thigh-bone was gone, and the shaft alone remained. The axis was changed, so that the trochanter minor was directed outwards, and the front of the shaft (namely, that part lying between the anterior margin of the great trochanter and the top of the internal ridge or edge of the shaft from which the arch of the cervix springs,) was applied to the pelvis. From this account a much more decided rotation of the toes inwards might be expected, but the lax connexion of the new articulation and the action of the muscles may account for the parts having taken a less decided position. Rotation could be easily performed with the hand. The new articulating surface of the thigh-bone was rough, though nearly flat, and measured full two inches by one and a half.

"The acetabulum and pelvis, on the other hand, were quite altered. The inner portion of the acetabulum is the only part unchanged; all the outer edge is absorbed, and the hollow itself is filled up with bone, except at the very inner part. This in the recent state was occupied with a substance of a mixed nature, comprising cartilage, bone, and cellular matter. Intermixture of cartilage was also met with in the more outer portion; and the whole mass or site of the former acetabulum was covered with a thin layer of cartilage. A new articulating surface was formed on that part of the pelvis which lies between the acetabulum and the anterior margin of the sciatic notch. The top of this surface is level with what was the upper margin of the acetabulum, and the very fore part of its top bears the same relation to the inferior spine of the ilium. It is two inches by one and a half, is rough, and covered with thin cartilage. The articulating surface of the femur was connected to it by a kind of capsule, arising everywhere from the slightly elevated margin which marks the boundary of this articulating surface. But a band of a stronger and more ligamentary nature extended from the femur to the site of the acetabulum, which probably was the remains of the capsular or synovial envelope of the joint. The articulating surface is not oval, but rather angular, and has at its anterior part a slight ragged depression. In this case, which is far from singular, I believe there is an evident attempt by nature to mould the part so as to form a new joint, as useful as circumstances would permit."

The next was received from Mr. Sands Cox, of Birmingham, in 1833. "When Mr. Bransby Cooper was last amongst us," says Mr. Cox, "he examined some of my specimens of fractured necks of thigh-bones, and asked me if I ever communicated the result of my examinations to you, and said that you would be pleased to receive an account of them. On looking over, last week, Dupuytren's Leçons Orales, the subject was brought to my mind, where he says, '*Sir A. Cooper n'a probablement vu que des fractures du col de fémur qui n'ont pas été guéries—c'est la seule manière d'expliquer l'opinion du chirurgien Anglais qui nous semble évidement erronée,*' and refers to preparations in the museums of Paris. As a true Borough disciple, during my residence in that city in the year 1825, and again in 1830, I examined most of the preparations, and cannot say that I saw a single specimen which warranted such an assertion. I believe, in 1819, that you visited the Continent,—were you favoured by the sight of any preparation of bony union?

"During the last five years I have examined upwards of fifteen cases, and in no single instance have I met with ossific union where the fracture has been decidedly within the capsule. In one case there was an extraordinary deposition around the neck and on the surface of the neck, but I believe the case to have been fracture external to the capsule. In another case there was complete ligamentous union, with an irregular attempt at ossific deposit. In a third, great absorption of the neck had taken place; in a fourth, there also was non-union, though the fracture was through the trochanter major. I examined, about three weeks ago, the ileo-femoral articulation of a patient who walked firmly and steadily for two years after the accident. I found the capsule extraordinarily thickened and contracted, a narrow ligamentous band between the fractured portions, and the margin of the bones beautifully rounded. I have examined the ileo-femoral articulations of many old people, to ascertain the effects of old age upon the neck of the femur, and in many cases I have met with considerable depositions of ossific matter around the neck and on the base of the head. These cases may very likely be sometimes reported as fractures with ossific union."

The next is a letter from Mr. Sheppard, senior surgeon to the Worcester County Hospital, which was published in the Provincial Medical and Surgical Journal for Nov. 6, 1841.

"I observed in the recently published volume of the Medico-Chirurgical Transactions, an account of a case* of fracture of the neck of the

* The following is an outline of the case in question. The patient was more than eighty years of age, and the case was treated by the straight splint for six or eight weeks.

thigh-bone, by Mr. Walter Jones of this city, whose opinion of the precise nature of this injury (that it was entirely within the capsular ligament) has been corroborated by Mr. Stanley of St. Bartholomew's Hospital. Having had an opportunity of examining the limb, through the kindness of Mr. Jones, I was allowed to send it to the late Sir Astley Cooper, who examined it with great interest, and wrote to me his opinion respecting it on the 23rd of October, 1840, expressing a strong desire to be made acquainted with the mode of treatment that had been adopted after the accident. As Sir Astley's opinion was *not* exactly in unison with Mr. Stanley's, I take the liberty of transcribing that part of Sir Astley's letter which relates to the subject.

"'Your son had the kindness to bring me an oblique fracture of the neck of the thigh-bone, in part within, and in part external to the capsular ligament; in part united, and in part not; and the neck of the thigh-bone absorbed.'

"Since death has so recently removed from us that 'great master of the healing art,' I thought that his opinion of a case upon a subject which he had so long made his study, and so much elucidated, might not be altogether uninteresting to those who might hereafter have an opportunity of examining the specimen now preserved in the museum of St. Bartholomew's Hospital."

To the foregoing letter the Editor will add a case which Mr. Sheppard sent to Sir Astley in 1840, and which was accidentally omitted from the proper place. It is inserted for the purpose of showing how useful a limb may become after a fracture within the capsular ligament, with the simple treatment directed by Sir Astley, when there is nothing in the age or constitution that is unfavourable to the patient's recovery.

Case CCCLIII.—"I will take the opportunity," says Mr. Sheppard, "of mentioning a case that occurred in my own practice in the year 1835. The patient was a thin spare man, in his sixty-fourth year, guard to the Ludlow mail, by the overturning of which the neck of the thigh-bone was fractured, within the capsule. I have not the *least doubt* of this; for the case bore all the evidences of that accident: the leg was considerably shortened, the trochanter drawn up above the acetabulum, and the foot and knee

He became well enough to go about with a stick, and died a year and a half afterwards, of bronchitis. On examination, the capsule was found much thickened, and it was necessary to divide the shaft of the bone before the knife could be passed round the joint, so nearly had the supposed fracture approached the acetabulum. The direction of the fracture could not be traced, nor the bond of union be made out, till the bone had been macerated. As the portions of capsule became loose, they were removed by the forceps, and displayed, as was believed by Mr. Jones and Mr. Stanley, a line of fracture entirely within them.—*Ed.*

were turned outwards; on extending or drawing down the limb and rotating it, at the same time making pressure on the trochanter, I could feel and hear a crepitus. This man was treated in the following way. The limb was bandaged from the toes to the hip, a long straight splint was applied to the outer side of the limb, and the ankles were tied together. He left his bed after seven or eight weeks' confinement to it, and was permitted to move about upon crutches. He gradually gained strength in the limb, threw first one crutch aside and then the other, and walked about with a stick. At the end of eighteen months he was able to resume his situation as mail-guard, got up and down from his box with facility, and even dexterously. He was before this able to throw his stick aside, and walked with a *very slight limp*. He continued at his post till his death, which occurred about a year after he resumed his occupation, and died of bronchitis, from taking cold."

No. II.

CASES OF NON-UNION OF FRACTURED BONES.

The failure of bony union after fracture is occasionally one of the most perplexing occurrences in the practice of surgery, since some cases of it are equally impossible to account for and to remedy.

It is true, that in numerous instances the failure of union may be traced to a defective state of the constitutional powers, or to the absence of some of those conditions of the fractured limb without which union cannot be produced in the healthiest constitutions. There is no difficulty, for example, in understanding that the materials effused for the consolidation of a fracture can never be converted into a bony callus, if subjected to frequent motion and disturbance. It may also be conceived, that if the system is under the influence of gout, or syphilis, or cancer, or if the vital powers are exhausted by age or debility, that the reparative processes may be feeble and inadequate. If, again, a fractured limb be deprived of its due share of nervous influence, a failure of reparation is not much to be wondered at, because we well know that in many cases, when the influence of the nerves is cut off, the nutritive action of the blood vessels becomes languid, and the warmth, growth, and strength of the part are diminished.* Moreover, if, during the existence of a fracture, an acute disease, such as a fever, happens to come on, or if the patient becomes pregnant, it is not unaccountable that the union of the fracture should be suspended, whilst the whole course of nutrition is perverted, as it would be in fever, or whilst all the energies of the system are employed in the elaboration of the fœtus. But yet there are some cases in which everything, both as regards the constitution and the part, might be supposed favourable for union, but still in which nature refuses her ordinary offices, and art is incapable of exciting them.

There are three obvious indications which the surgeon has to act upon in these cases. The first is to ensure all the mechanical conditions which

* This is exemplified by a case mentioned by Mr. Travers, in which a patient had a fracture of the arm and of the leg, and at the same time an injury to the spine, which paralysed the lower extremities. The arm united readily enough, but the leg, which was deprived of its proper share of nervous influence, did not unite.

are essential for the consolidation of callus; comprising perfect rest and immobility, and contact and pressure of the broken surfaces against each other. The second is to excite by artificial means that inflammatory process which nature employs in the restoration of injuries. The third is to remove, as far as possible, every disorder of the health, and to administer some medicine capable of modifying the general action of the capillaries.

In conformity with these rules, the first thing to be done, if a fracture does not unite within the given time, is to bind it up firmly with splints, or the starch bandage, or plaster of Paris, or some similar unyielding material, for a month or six weeks. This failing, the surgeon may resort to violent friction of the broken surfaces against each other, or may pass a seton between them for a fortnight, or may affect the system with mercury; or, if a false joint appears to have formed, he may cut down on the broken ends, and shave them off. But, as I commenced by observing, he will meet with some instances in which all these measures combined will be ineffectual, as in the case of Henry Ildred, related at page 575.

I have premised the above brief observations by way of introduction to the following cases, which will afford instances of some of the circumstances under which non-union occurs, and of the success and want of success that attends the surgeon's efforts in various instances.

The first case is one that Sir A. Cooper was consulted about by Mr. Bernard, surgeon, of Crewkerne.

Case CCCLIV.—" On the 24th of June last, Mrs. Bird was thrown from a carriage, and received a simple transverse fracture of the left tibia and fibula, at the junction of the lower with the middle third of the shaft of the bones. She was at the same time very much cut and bruised about the face, shoulder, back, &c. Her chest also must have sustained severe concussion, as she constantly spit blood for a fortnight after the accident. All appeared to go on well for the first few days, but then she became subject to most severe hysterical paroxysms, during which attacks the leg was most violently twisted and thrown about by the action of the muscles. I endeavoured to remedy this by change of position, first trying a straight, then a bent position of the leg, but the same could seldom be borne continuously for a whole day. In this way she went on until July 18th, when, on taking off the splints and opening the bandages, I found that no union had taken place; and the wounds about the body being healed, and her general health more restored, I first applied soap plaster on leather firmly, next one bandage, then pasteboard splints, then another bandage well wetted with mucilage of acacia; thus making a firm and complete case for the leg, and in some degree restraining the violent

convulsive action of the muscles. The leg appeared now to mend, although slowly; and at the end of six weeks, on taking off my apparatus, there was some union, though far from firm, as the leg could be moved from side to side. Since then she has gone on progressively improving, but is still unable to bear on the limb at all without severe pain. I had also great difficulty to overcome before she could place the foot on the ground, from the violent convulsions which the attempt produced. She has for the last few months worn an elastic laced stocking, and has more power over the limb, being able to turn it over when in bed, and to bear it down the whole day whilst in a sitting posture. I have tried friction, with various stimulating applications, but the skin is so irritable that she cannot continue their use.

"I should also add, that I think Mrs. B. to be of a very strumous constitution, and wanting strength to throw out ossific deposit so as to make the union firm; but that I believe time will render it so.

"February 21st. The state of the leg this day is the same, inability to bear on it, with pain, on pressure, at the seat of the fracture; occasional spasms, with some considerable swelling towards night, so as to be obliged to remove the elastic bandage and laced stocking."

The next case was sent to Sir A. Cooper for his opinion, by Mr. Neville, of Esher, in 1838.

Case CCCLV.—"A gentleman suffered an extremely oblique compound fracture of both bones of the leg. It was treated in the straight position in junks, and reduced to a simple fracture in three weeks. The limb was apparently recovered in ten weeks, and the patient was allowed to get up, and have it bent and put upon the ground.

"From a very early period the limb was enormously swollen, up to the hip, measuring thirty-two inches at least in the upper part of the thigh. It was more like a case of phlegmasia dolens than ordinary dropsical infiltration.

"In a few weeks after he left his bed, the patient suffered from a *severe* attack of influenza. While this confined him to his bed, the swelling of the limb rapidly disappeared, and the leg was then found as flexible at the fractured part as on the first receipt of the injury.

"A return to the recumbent position, and a re-treatment after the original principle, was now proposed in consultation, but the patient refused.

"The case now submitted to you," says Mr. Neville, "has for a long time, *in more senses than one*, vexed and embarrassed those who have had the management of it.

"Scarcely less than a dozen of the fraternity, both of London and

country, as friends, have endeavoured to assist me in the business, and the whole of the most eminent men have been over and over proposed for consultation, out of whom the patient had previously selected Mr. Key.

"Mr. Key said that the same thing occasionally baffled him in the hospital, but that he expected the limb would recover and be sound. Latterly, however, he has agreed with us, in looking at the dropsical diathesis as founded on organic disease of the heart and arteries, and in thinking that the same cause which affected the fractured limb at first is now affecting the other. From the tunica vaginalis I drew off twenty ounces of fluid about three weeks since.

"The action of the pulse at the wrist, the state of the heart under auscultation, together with the symptoms of angina pectoris, which occasionally, without the patient understanding their true nature, have affected him, are matters which have been duly weighed in the treatment of the case."

The next case was sent to Sir A. Cooper by Mr. Phythian, of Winchcomb, Gloucestershire.

"I have a son at Somerset, Pennsylvania, North America, who has for several years been in extensive practice, and having received an invitation from several of the most respectable inhabitants of Union Town, Fayette County, to settle there, he has requested me to endeavour to procure your opinion of the following case, which he believes would be of the most essential service to him, and for which I assure you I shall feel myself under the greatest obligation. The case is as follows:—

Case CCCLVI.—"Mr. Buttermore, a stout, athletic, healthy person, between thirty and forty years of age, had a simple fracture of the femur, about half way between the knee and hip, five months ago; and from bad management, or some unaccountable circumstance, it has formed an artificial joint. I have been applied to," says my son, "for the purpose of performing an operation, but have advised the patient to wait for cooler weather, and for the opinion of my friends in England. I do not approve of the seton, as it appears to have failed in the practice of Dr. Physick of Philadelphia, although dissection proved that it had passed directly between the ends of the bones. The patient has always complained of the knee more than of the fracture, which he says scarcely hurt him at all; and during the attempt to cure it the inflammation of the joint ran very high. May I hazard the following suggestion? Did not the inflammatory action, which ought to have produced union, (as I believe the bones were kept in apposition,) metastatize and seize on the knee-joint? At present he complains much of his knee, which is considerably swollen; the leg and foot are œdematous, in consequence, I should suppose (principally),

of his wearing a piece of sole-leather tight round the thigh, to enable him to throw his leg forward.

"I have advised local bleeding from the knee, and Baynton's plan to the leg. As Sir Astley Cooper is so well known in these parts, I am most anxious to obtain his opinion of the above case, with a minute account of the operation, together with the probable anatomical appearances, and ultimate result of it."

The following case Sir Astley was consulted about by Mr. Page, of Plymouth.

Case CCCLVII.—"I write to you," says Mr. Page, "at the request of my friend, Sir George M., an eminent physician of this place, to obtain your opinion and advice on his case. He unfortunately broke his leg about eighteen weeks since, and all our endeavours to effect union have hitherto failed. The accident occurred whilst walking; his foot slipped, and he suddenly came to the ground. On visiting him I found both bones broken, but as the limb was perfectly straight, and he was suffering extreme pain, I did not push my inquiries to ascertain whether the fracture was transverse or oblique. When the inflammation subsided, in the course of a few days, it was found that the fracture was oblique, running from without towards the internal malleolus. The impression on the doctor's mind, from having previously examined the limb, was, that another transverse fracture existed higher up; but I could never satisfy myself that the opinion was correct. Many subsequent attempts were made by our mutual friends to discover it, but without any conclusive result. It is a singular circumstance, however, that when the opinion of the doctor was made known to me, I immediately said, 'if such be the case I fear union will not take place.' I merely mention the circumstance *en passant*, though the impression on my mind at the time was, that no such fracture really existed. At the expiration of six weeks, as the bones were found not to be firmly united, he was advised to continue recumbent and at rest for a fortnight longer, after which it was thought right to take him occasionally from bed, and place the limb on an inclined plane. The attempt was attended with excessive pain and inconvenience, so that he preferred remaining in bed for another fortnight.

"All pressure was now removed from the limb, and friction with soap liniment resorted to. This plan having been persisted in for another fortnight, in conjunction with a more generous diet, and the internal use of quinine, it was determined to remove him daily from bed, to cover the part with soap plaster, to bandage the limb firmly, and to add the whalebone splints, to secure the fractured portions from motion. This course has been continued for some weeks, the parts being occasionally inspected.

His general health has improved, as shown by a return of plumpness, but, unfortunately, no amendment is visible in the condition of the injured parts.

"As this state of things is a novelty to me, having never met with more than one case of ununited fracture, and that occurring in a gun-shot wound of the arm, I am most anxious, in conjunction with my patient, to obtain the advice of one so well qualified as yourself to give it. He is now taking the carbonate of iron, and using mercurial friction, with the view of exciting an action in the system. He has been told of three cases where the mercurial treatment has been found pre-eminently beneficial, and although reasoning, *à priori*, might not lead us to such a conclusion, yet the experiment is worth a trial. His age is nearer sixty than fifty; his general appearance healthy; his habits most temperate and active. No man in this neighbourhood has undergone more fatigue on horseback than himself, and to look at him, you would say that he was one of the healthiest of men, and equal to any laborious exertion. It may be well to add, that an acute point of the fractured bone can be distinctly felt at the inner ankle, projecting about two or three lines from the inferior portion of bone, but not visible to the eye."

Sir Astley recommended a double-footed splint to be tightly applied on each side of the leg, and that the limb, thus bound up, should be suffered to hang down, and be used in walking with crutches, till some degree of inflammation followed.

The next case is that of a patient of Mr. Chandler, of Canterbury.

Case CCCLVIII.—"Mr. C. P., on the 10th of February, was riding a horse down a hill in my neighbourhood, when the horse fell, with Mr. P.'s leg under him, and on attempting to rise, Mr. P. found the limb fractured. He was removed to an inn in Canterbury, and sent for me. On examining his leg, I found a simple fracture of the tibia, about three inches above the joint. The seat of fracture was distinctly seen and felt, being somewhat oblique, and the superior end of the bone presenting a lunated edge, the convexity facing downwards. He was placed in a swing which I employ for fractures, the limb being slightly flexed; no particular degree of inflammation followed. At the end of four weeks the leg was examined, and union found to be so imperfect as to allow of very slight motion. He was therefore recommended quietude, and in another fortnight (viz. six weeks after the accident) was suffered to return to Greenwich, with the understanding that the splints were to remain on another week.

"On his return he was seen by another surgeon, who first complained that the splints had been kept on too long, but afterwards stated that he traced a fracture in an oblique direction from that hitherto known,

down to the ankle-joint nearly; which fracture he conceives to have been in some degree comminuted, as he perceives small fragments scarcely yet united, to which he attributes the length of time required for recovery, the dropping of the foot, &c.

"Now, as there was no appearance or indication of the fracture having been comminuted, I am at a loss to understand what this gentleman means; more especially as, if the fracture had been a comminuted one, no other treatment, as far as I know, could have been adopted than that recommended. As I feel my professional reputation involved in this affair, I do entreat you will meet me, and give me your candid view of the case."

The following case occurred in the practice of the Editor at Guy's Hospital.

CASE CCCLIX.—"Eliz. Gould, aged 28, in August, 1835, broke her left humerus, about the junction of the upper with the middle third, through a fall from a cart. *She was in good health at the time,* and is naturally of a strong constitution. She immediately applied for professional advice, had splints applied, and, from her account, was treated in the usual manner. In about eight weeks the surgeon discovered that union had not taken place; he replaced the splints therefore more firmly than before, and bound the arm to the side, to prevent motion. This apparatus was worn for a month without being removed, at the expiration of which period the fracture was still found ununited. The apparatus was now re-applied, with the addition of an iron splint bent at an acute angle, and extending from the outer side of the humerus to the wrist, which was worn for another month, but with no better effect. A bandage was then tightly bound round the arm, and a wooden splint applied over it, compressed to the utmost the patient could bear, for two months, when still it was found that no union had taken place.

"On March 9th, 1836, she was admitted under my care into Guy's Hospital, when, upon examination, I found the two fractured extremities of the humerus in juxta-position, but without union, or any adventitious formation in the surrounding cellular membrane; the two portions of bone moved readily upon each other, and without producing anything approaching to the sensation of crepitus, giving rather the impression of an amphiarthrodial joint in motion. Impressed with the conviction that all mechanical means had been judiciously employed, I gave up all hopes of producing union by any further use of such means, and proposed a seton, which was immediately consented to by the patient, and was inserted between the extremities of the bone, about March 23rd. It was worn ten weeks, producing but very little constitutional irritation or local effect, for on removing it, no ossific union had taken place.

"A bandage dipped in a composition of egg and flour was then firmly applied, and worn for six weeks. It was so applied (enclosing both the elbow and shoulder,) as forcibly to press both extremities of the bone against each other, but without producing the desired effect. Plaster of Paris was next used as a means of maintaining perfect apposition and rest; it was worn a month, but when chiselled off, the arm was *in statu quo*.

"About this period Mr. Colles of Dublin went round with me, and said he had known such cases cured by the administration of mercury, continued until it produced ptyalism. This plan was adopted, but at the same time a leathern padded girth, furnished with several straps and buckles, was forcibly applied around the arm. In four days the mercury was obliged to be discontinued, from the violent effect on her mouth, but the girth was continued to be worn a month, when upon its removal the arm was found united. She remained, however, in the hospital two months longer to recruit her health, when she was discharged cured.

"Three months after this she was again admitted, from the fracture having been reproduced by a violent blow; when upon examination all the usual phenomena of common fracture presented themselves. The same girth was applied, and (without the use of mercury) the bone united at the usual period."

The last case was under the care of Mr. Key in Guy's Hospital.

Case CCCLX.—Henry Ildred, æt. twenty-five, a stout muscular man, by trade a butcher, who had never had syphilis nor taken mercury, and in fact never remembered a day's illness, broke his left humerus about its lower third, on the 4th of November, 1839. The limb was at once put up in splints and bandages, which were removed and readjusted every other day for the first fortnight; and after this, once a week for six weeks; during which time he could occasionally distinctly feel the ends of the bone rub against each other. At the expiration of this time the bones were still ununited, and all treatment was abandoned for four weeks more.

He then consulted another surgeon, who secured the limb in splints, and kept him in bed for a month, but without avail.

He next went to Ramsgate, and bathed for six weeks; but this being equally inefficacious, he became a patient in Guy's Hospital, under Key, on the 8th of July, 1840.

Every means that held out any prospect of producing union made use of, but were all equally unattended with benefit. A ordinary methods of perfect apposition, rest, pressure, &c. ha failure, Mr. Key cut down to the separated portions of bo tempted, by placing wire around their extremities, to excit

inflammation, and so to lead to the desired union. This not succeeding, Mr. Key again divided down to the line of fracture, and having exposed the surfaces of the disjoined portions of bone, removed a thin layer from each by means of a fine saw. On this occasion a portion of substance having a cartilaginous appearance, apparently muscular tissue, which had become altered by pressure, was found separating the two extremities of the bone, and was removed. This operation having proved unsuccessful, notwithstanding a considerable degree of inflammation was excited, as a dernier resort, a seton was passed between the separated surfaces. This, however, failed equally with the other attempts in producing union, and the man left the hospital unrelieved. At one period in the course of the treatment above mentioned, he was subjected to the influence of mercury, until salivation was produced, but apparently without producing any effect on the fractured ends of the bone.

THE END.

LONDON:
PRINTED BY SAMUEL BENTLEY,
Bangor House, Shoe Lane.